

# 32nd Annual Meeting American Association *of* Clinical Anatomists



American  
Association  
of Clinical  
Anatomists

**June 9 –12, 2015** | *Henderson, Nevada*

[www.clinical-anatomy.org](http://www.clinical-anatomy.org)



## President's Report

June 9-12, 2015  
Green Valley Ranch Resort & Casino  
Henderson, NV

PO Box 2945  
LaGrange, Ga 30241  
Ph: 706-298-0287

[www.clinical-anatomy.org](http://www.clinical-anatomy.org)

Another year has quickly passed and I have been asked to summarize achievements/threats to the Association for our meeting program booklet. Much of this will be recanted in my introductory message on the opening day of the meeting in Henderson. As President, I am representing Council in recognizing the work of those individuals not already recognized in our standing committee reports that you will find in this program.

One of our most active ad hoc committees has been the one looking into creating an endowment for the association through member and vendor sponsorships. Our past president, Anne Agur, has chaired this committee and deserves accolades for having the committee work hard and produce the materials you have either already seen, or will be introduced to in Henderson. The format was based on that used by many clinical organizations. It allows support at many different levels, the financial income from which is being invested for student awards and travel stipends. Our ambitious 5 year goal is \$100,000. I hope that you will join me in thinking seriously about supporting this initiative - at whichever level you feel comfortable with. Every dollar goes to the endowment.

In October, Council ratified the creation of our new standing committee - Brand Promotion and Outreach. This committee was formed by fusing the two ad hoc committees struck by Anne Agur when she was President. Last year our new branding was highly visible in Orlando and we want to use this momentum to continue raising the profile of the Association at many different types of events within and outside North America.

Our regional meeting initiative has also taken off with the first one to be held in Salt Lake City this coming October. We encourage those within the region - and also those outside the region - to make an effort to attend this new meeting format. Our continuation and expansion of these regional meetings will depend on member support. Check this program, or our web site, for full information on this meeting being organized by Jon Wisco and associates locally.

Association finances continue to hold solid. Much of this is due to an increased number of paying members coupled with the Wiley subscription deal and Shane Tubbs' ability to run the editorial office within the budget provided by the Wiley Contract. This allows us to retain the Clinical Anatomy royalties provided by Wiley that continue to grow in size - this year close to \$70,000. Our relationship with ASG (our association management group) continues to mature into a solid working relationship where we have a mutual understanding of what we need and want as an association. Both Caitlin and Shanan continue to do an outstanding job as the "face" of the association and our members speak highly of their interaction with the management team. In light of projected increased hourly charges over the next few years, and to ensure we retain a sound financial footing with ASG, I have asked our Financial Affairs Committee to work closely with them over the next 12 months to see where the majority of ASG services are utilized - which committees/aspects of the association run the largest hours of usage with ASG. We value ASG as our management colleagues and will work with them to ensure fiscal responsibility as the cost of doing business rises. Financial responsibility has been my greatest area of focus since entering the presidential stream of the AACA and I remain committed to seeing our well-crafted ASG-AACA relationship continue into the future.

Finally, I want to ensure that each of you recognize the hard work of our Program Secretary (Noelle Granger), our meeting managers (David Porta and Sherry Downie) and the other members of the MOPP Committee for their efforts in creating this non-hosted meeting in Henderson. Our bid to hold the meeting jointly with AMI in San Antonio fell through at a date that was too late to get other sites involved. Las Vegas has an infinite number of meeting sites and Green Valley Ranch came through with a proposal that we felt welcomed us back after our Touro-sponsored 2007 meeting. We appreciate everyone's effort to make this a meeting that differs only slightly from our typical hosted meetings. We are all looking forward to hearing from our Presidential speaker - Francine Netter; Carol Scott-Conner, our Honored Member, and remembering our Adkins Award winner, Larry Ross. I look forward to seeing you all during the meeting and I encourage anyone with Association-related issues or ideas to discuss them with me at any time.

**Brian R. MacPherson, Ph.D.**

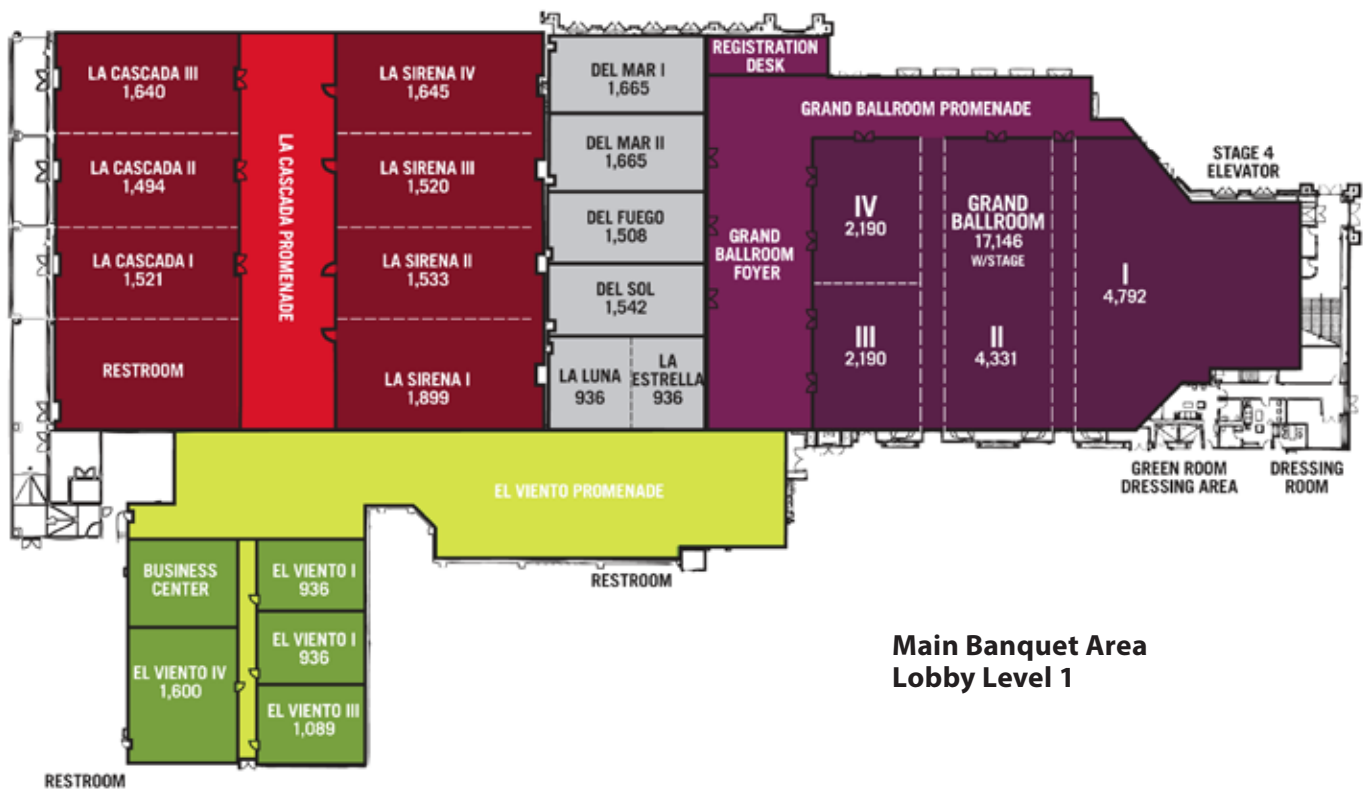
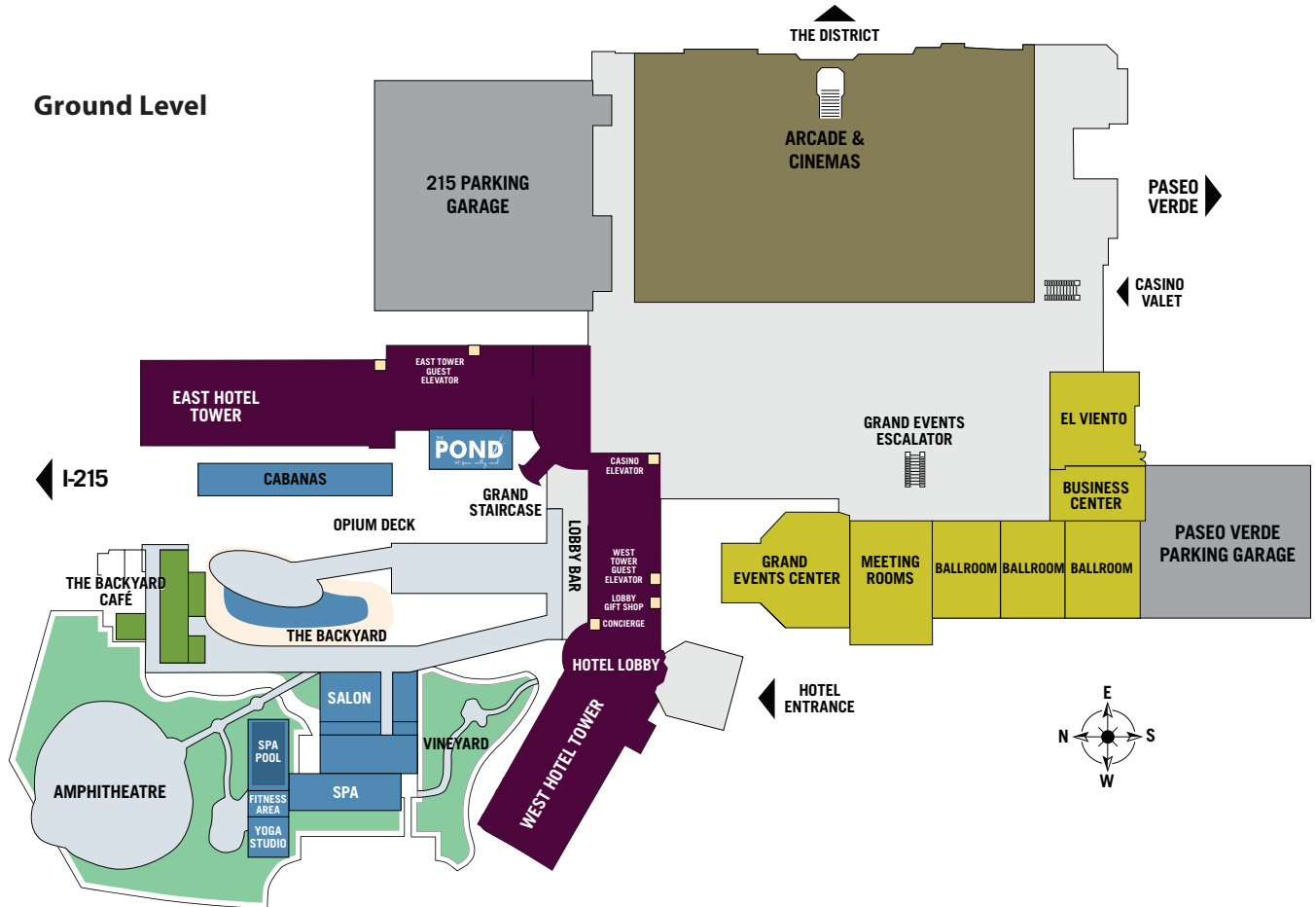
# Table of Contents

Floorplan of Convention Center.....	3
Block Schedule of Events.....	4
Handy Tear-Out Sheet.....	3,4
Acknowledgement and Thanks to our Sponsors and Exhibitors.....	5
Information on Food/Beverage Around Green Valley Ranch.....	8
Pre-Meeting Events.....	9
Scientific Program .....	9
Presidential Speaker – Francine Mary Netter.....	14
Honored Member –Carol Scott-Conner .....	15
Distinguished Service Award – Lawrence M. Ross .....	16
Career Development Committee Symposium .....	17
“High Point in Anatomical Art” by Acland, Machado & Gielecki.....	19
“Anatomy in the New Millennium” Lunch Symposium.....	20
Clinical Anatomical Terminology Committee Symposium.....	22
Poster Listing	
Poster Session 1 - Head and Neck.....	24
Poster Session 2 - Limbs.....	27
Poster Session 3 - Torso.....	30
Poster Session 4 - Anatomical Services & Education.....	33
Annual Business Meeting Agenda.....	36
Annual Business Meeting Minutes – Orlando.....	37
Officers of the AACA Council.....	40
<i>Clinical Anatomy</i> – the Official Journal of AACA.....	41
Committee Reports	
Anatomical Services Committee.....	42
Career Development Committee.....	43
Clinical Anatomical Terminology Committee.....	44
Educational Affairs Committee .....	45
Journal Committee.....	46
Meeting Oversight and Program Planning Committee .....	47
Membership Committee.....	49
Nominating Committee .....	50
2015 Annual Meeting Committee.....	51
Listserv Admin Report .....	52
Abstract Listing by Author	
Platform Presentations .....	53
TechFair Presentations .....	63
Poster Presentations.....	65
William Carey University College of Osteopathic Medicine Advertisement .....	122



# GVR Conference Center Floor Plan

## Ground Level



## Main Banquet Area Lobby Level 1

# Block Schedule

Tuesday, June 9th		Wednesday, June 10th	Thursday, June 11th	Friday, June 12th	Saturday, June 13th
7:30		Career Dev Comm J Wisco 7:30 - 9:00 in Del Mar Rm	Educational Affairs Comm Elections & Low Tech Fair J. Burgoon 7:30 - 9:00 in Del Mar Rm	Anatomical Svcs Comm Schmitt & Hoagland 7:30 - 9:00 in Del Mar Rm	Visit the Strip! Grand Canyon Lake Meade
7:45		Breakfast/Poster/Exhibitors in Grand Rm II, III, IV	Breakfast/Poster/Exhibitors in Grand Rm II, III, IV	Breakfast/Poster/Exhibitors in Grand Rm II, III, IV	
8:00		Welcome & State of the Assn MacPherson in Grand I	Opening Announcements	Opening Announcements	
8:15		Presidential Speaker Francine Netter 9:30 - 10:30 in Grand I	Platform Session 2 (n=5) Students Part 2 of 2 9:15 - 10:30 in Grand I Moderator: S. Downie	Poster Session 4 - ASC & Ed Even #'s 62-122 Presented 9:15 - 10:30 in Grand II,III,IV	
8:30		BREAK	BREAK		
8:45		Platform Session 1 (n=5) Students Part 1 of 2 10:45 - 12:00 in Grand I Moderator: D. Porta	Poster Session 2 - Limbs Even #'s 2-60 Presented 10:45 - 12:00 in Grand II,III,IV	Platform Session 4 Education + Tech Fair (n=5+3) 10:30 - 12:00 in Grand I Moderator: G. Smith	
9:00	Registration All Day, Each Day @ the Grand Ballroom Reg Desk				
9:15					
9:30					
9:45					
10:00					
10:15					
10:30					
10:45					
11:00					
11:15					
11:30					
11:45					
12:00					
12:15					
12:30	AACA Council Meeting 9:00 - 5:00 in Del Fuego Rm	Lunch Break 12:00 - 1:30 <i>Clinical Anatomy</i> Editorial Board Lunch Mtg in Del Sol Rm	"Anatomy in the New Millennium" Lunch Symposium 12:00 - 1:15 in Grand I	Lunch Break & Tech Fair Hands-on 12:00 - 1:00 Grand I	
12:45					
1:00			Platform Session 3 (n=3) Pot pourri 1:15 - 2:00 in Grand I Moderator: J. Brueckner-Collins	Clinical Anatomical Terminology Committee Meeting Open To ALL S. Downie 1:00 - 2:30 in Grand I	
1:15			BREAK	BREAK	
1:30			"Towards a Universal Anatomical Terminology for the Health Sciences" 2:15 - 3:30 in Grand I J. Fraher & R. Pratt	Platform Session 5 (n=4) Pot pourri 2:45 - 3:45 in Grand I Moderator: A. McArthur	
1:45					
2:00	Spkr Prep Area Open Each Day until 7 pm in Del Mar Rm	CDC Symposium "Changing Paradigms in Academics" Carwise, Daly, Phitayakorn & Wisco 1:30 - 3:00 in Grand I	Poster Session 3 - Torso Odd #'s 61-119 Presented 3:30 - 4:45 in Grand II,III,IV		
2:15					
2:30					
2:45					
3:00					
3:15					
3:30		Poster Session 1 - Head & Neck Odd #'s 1-59 Presented 3:15 - 4:30 in Grand II,III,IV			
3:45		Mentee Mtg - Alan Detton 4:30 - 5:00 in Del Mar Rm			
4:00					
4:15					
4:30					
4:45					
5:00					
5:15	Judges Meeting 5:00 - 6:00 in Del Sol Rm	Mentor Reception 5 - 6:00 in Del Mar Rm	Reception 5:00 - 6:00 in Grand Foyer	Business Mtg & Awards Ceremony 4:00 - 5:00 in Grand I	
5:30				Mtgs of NEW AACA Council & MOPP Comm 5:00 - 6:00 in Del Mar	
5:45					
6:00					
6:15					
6:30					
6:45	>Welcome Reception 6:30 - 8:30 Opium Terrace	Social "High Point in Anatomical Art" Acland, Machado & Gielecki 6:30 - 8:00 in Grand I	Banquet & Awards 6:00 - 8:00 in Grand I		
7:00					
>7 pm					

# Sponsors/Commercial Exhibitors

*Generous donations and/or commercial exhibitor fees paid by the following companies and organizations have substantially reduced the Association's expenses in presenting this meeting.*

*Thank you to our Welcome Reception Sponsor* **ELSEVIER**

*You are encouraged to visit the exhibits available for viewing in the Grand II, III, IV*

**Exhibit hours:**     **8:00 am - 12:00 pm and 1:00 pm - 5:00 pm Wednesday**  
                              **8:00 am - 12:00 pm and 1:00 pm - 5:00 pm Thursday**  
                              **8:00 am - 1:00 pm Friday**

## LIST OF EXHIBITORS AS OF 5-21-15

**1**

### **Elsevier**

1600 John F. Kennedy Boulevard, Suite 1800  
Philadelphia, PA, 19103  
USA  
Phone: 215-239-3491  
www.elsevierhealth.com

Medical books and periodicals.

**2**

### **Anatmage**

111 N. Market Street #500  
San Jose  
CA, 95113  
USA  
Phone: 408-885-1474  
www.anatmage.com

Virtual Dissection Table.

**3, 4**

### **Bone Clones, Inc.**

21416 Chase Street, #1  
Canoga Park, CA, 91304  
USA  
Phone: 818-709-7991  
www.boneclones.com

Osteological Reproductions.

**5**

### **STAT!Ref**

PO Box 4798, 125 S. King Street  
Jackson, WY, 83001  
USA  
Phone: 800-901-5494 x 130  
www.statref.com

Electronic healthcare e-books and reference.

**6**

### **Mortech Manufacturing**

411 N. Aerojet Ave  
Azusa, CA, 91702  
USA  
Phone: 626-334-1471  
www.mortechmfg.com

Manufacturer of Anatomy Equipment.

**7**

### **Holt Anatomical**

PO Box 370749  
Miami, FL 33137-0749  
800-642-4658  
www.holtanatomical.com

Holt is a distributor for SOMSO, 3B, and Denoyer Geppert Models.

**9**

### **Touch of Life Technologies**

12635 E Montview  
Aurora, CO, 80045  
USA  
Phone: 720-505-2381  
www.toltech.net

VH Dissector.

**10**

### **InfoSight Corporation**

20700 US Highway 23  
PO Box 5000  
Chillicothe OH 45601  
Phone: 740-642-3600  
www.infosight.com

Identification and marking equipment.

*continued on next page*

**15**  
**William Carey University College of Osteopathic Medicine**

498 Tuscan Avenue  
Hattiesburg, MS 39401  
USA

Phone: 601-318-6731

[www.mmcarey.edu](http://www.mmcarey.edu)

Osteopathic Medical School

**16**  
**BodyViz**

8805 Chambery Boulevard, Suite 300-242  
Johnston, IA, 50131

USA

Phone: 877-296-4111 ext 555

[www.bodyviz.com](http://www.bodyviz.com)

Stereoscopic MRI/CT Visualization Software for Education.

**17**  
**Anatomy Tools**

5275 Arville Street, Suite 372  
Las Vegas, NV, 89118

USA

Phone: 702-826-3950

[www.anatomytools.com](http://www.anatomytools.com)

Products & Training in Aesthetic Anatomy, for Artists, Surgeons and Physicians.

**18**  
**Imagineeringart.com Inc**

208 Bloor Street West, Suite 300  
Toronto, ON, M5S 3B4

Canada

Phone: 416-946-8811 ext 292

[www.imagineeringart.com](http://www.imagineeringart.com)

Illustration/Animation/3D/Multimedia.

**19**  
**EducationHive, LLC**

562E 2320N

Provo, UT, 84604

USA

Phone: 949-235-7526

[www.anatomyhive.com](http://www.anatomyhive.com)

A web-based testing application for anatomy lab practicals.

**20, 21**  
**von Hagens Plastination**

Im Bosseldorn 17

Heidelberg, 03172

Germany

Phone: 49-35615474306

[www.vonhagens-plastination.com](http://www.vonhagens-plastination.com)

Real human plastinated teaching specimens.

**22**  
**Primal Pictures Ltd**

Christchurch Court, 10-15 Newgate Street

London, EC1A 7AZ

United Kingdom

Phone: +44 (0) 207 551 9979

[www.primalpictures.com](http://www.primalpictures.com)

Primal Pictures provides cost effective software solutions for healthcare education.

**23**  
**Wiley**

350 Main Street

Maupen, MA, 02148

USA

Phone: 781-388-8313

[www.wiley.com](http://www.wiley.com)

Books and Journals.

**24**  
**Wolters Kluwer**

Two Commerce Square, 2001 Market Street

Philadelphia, PA, 19103

USA

Phone: 215-521-8300

[www.lww.com](http://www.lww.com)

Books, Journals, Electronic Media.

**25**  
**Thieme Publishers**

333 Seventh Avenue

New York, NY, 10001

USA

Phone: 212-760-0888

[www.thieme.com](http://www.thieme.com)

Educational and clinical books; digital products.



# 2015



American  
Association  
of Clinical  
Anatomists

PO Box 2945  
LaGrange, Ga 30241  
Ph: 706-298-0287  
[www.clinical-anatomy.org](http://www.clinical-anatomy.org)

# Member Sponsorship

## 2015 Member Sponsorship Donors

### Diamond \$1000

Anne Agur, BSc, (OT), Ph.D  
Stephen Carmichael, Ph.D., DSc  
Sherry A. Downie, Ph.D.  
David J. Porta, Ph.D.

### Emerald \$500

### Ruby \$250

Peter Abrahams, MBBS, FRCS(Ed), FRCR, DO(Hon), FHEA  
Noelle A. Granger, Ph.D.  
Jonathan J. Wisco, Ph.D.

### Sapphire \$100

***Interested in becoming a member sponsor donor?***

Visit the registration desk for more details.

# Dining Options

## Inside the Green Valley Ranch

### Fine Dining

#### Hanks Fine Steaks & Martinis

Dinner only

\$\$\$\$

### Casual Dining

#### Grand Café

Open 24 hours a day

\$\$

#### Tides Oyster Bar

Open 11 AM – 10 PM

\$\$

#### Feast Buffet

Breakfast 8:00 AM – 10:45 AM

Lunch 11:00 AM – 3:00 PM

Dinner 4:00 PM – 9:00 PM

\$\$

#### Pizza Rock

11 AM - 12 AM

\$\$

#### Turf Grill

11 AM - 7 PM

\$

### Quick Eats

#### Capriotti's

#### Fatburger

#### Tropical Smoothie Café

#### Slice House

#### Starbucks

#### Panda Express

#### U-Swirl

\$

## Nearby *(Across the street at the District Shopping Center)*

### Seated Dining

#### Balboa Pizza Company

Open 24 hours a day

\$\$

#### Elephant Bar

Open 11 AM – 10 PM

\$\$

#### King's Fish House

Open at 11 AM each day

\$\$ - \$\$\$

#### Lucille's Bar-B-Que

Open 11 AM – 10 PM

\$\$ - \$\$\$

#### P.F. Chang's China Bistro

Open 11 AM – 11 PM

\$\$ - \$\$\$

#### Settebello Pizzeria Napoletana

Open 11 AM – 10 PM

\$

#### The Cheesecake Factory

Open 11 AM – 11:00 PM

\$\$ - \$\$\$

### Quick Bites

#### Crazy Pita Rotisserie & Grill

Open 10:30 AM – 9 PM

\$

#### Panera Bread Company

Open 6:30 AM – 9 PM

\$

#### Rachel's Kitchen

Open 8 AM – 9 PM

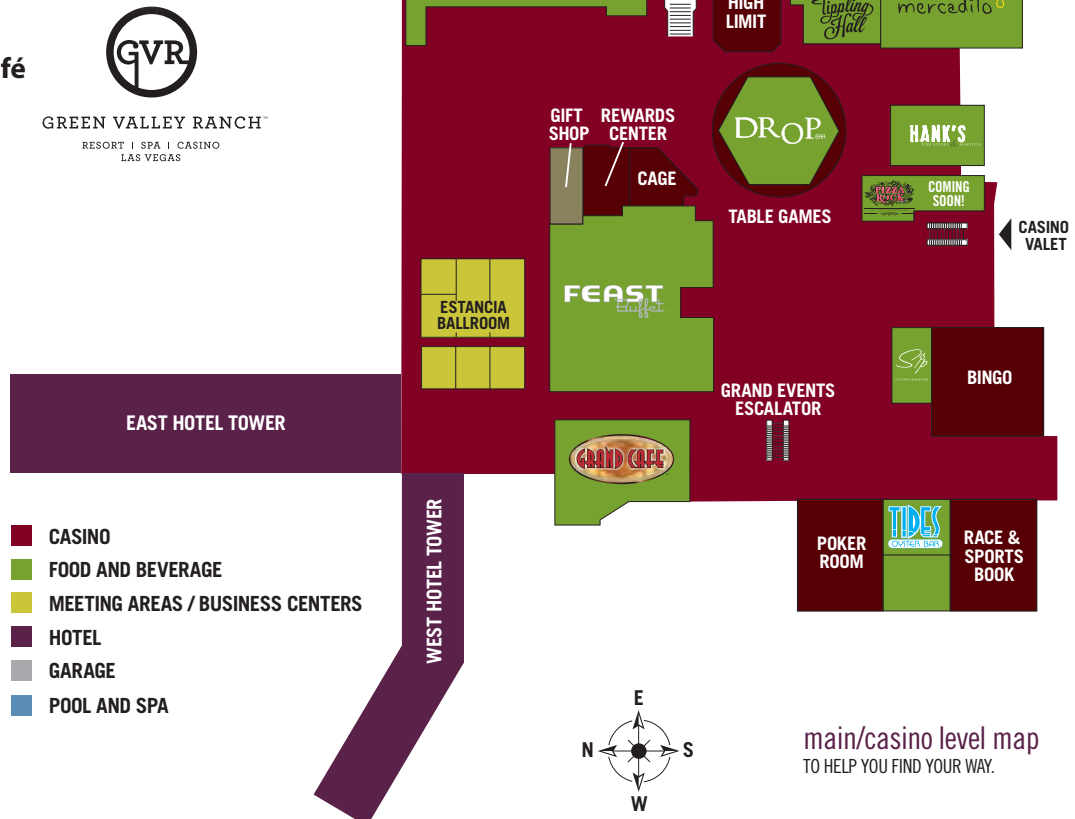\$

#### Coffee Bean & Tea Leaf

Open 6:30 AM – 9:30 PM

\$

\$ = how expensive the restaurant is



# Pre Meeting Events

## Tuesday, June 9th

9:00 AM – 5:00 PM	AACA Council Meeting .....	Del Fuego Room
8:00 AM – 5:00 PM	Exhibitor Set-Up .....	Grand II, III, IV
1:00 PM – 5:45 PM	Registration .....	Grand Ballroom Registration Desk
5:00 PM – 6:00 PM	Judges' Meeting .....	Del Sol Room
6:30 PM – 8:30 PM	Welcome Reception .....	Opium Terrace

Sponsored by **ELSEVIER**

# Scientific Program

## Wednesday, June 10th

7:30 AM – 9:00 AM	Career Development Committee Meeting – Open to all .....	Del Mar Room
8:00 AM – 5:00 PM	Registration .....	Grand Ballroom Registration Desk
8:30 AM – 9:00 AM	Breakfast with Exhibits .....	Grand II, III, IV
8:30 AM – 10:30 AM	Posters 1 - 60 Set up	
9:00 AM – 9:30 AM	Opening of Scientific Session - Welcome .....	Grand I
	Brian R. MacPherson, Ph.D. President, American Association of Clinical Anatomists	
	Kimberly Topp, PT, Ph.D. President, American Association of Anatomists	
	Tom Lehman President, Human Anatomy and Physiology Society	
9:30 AM – 10:30 AM	Presidential Speaker: Francine Mary Netter.....	Grand I
10:30 AM – 10:45 AM	Break with Exhibits/Posters.....	Grand II, III, IV
10:45 AM – 12:00 PM	Platform Session I – Students Part 1 of 2 .....	Grand I
	Moderator: David Porta	
10:45 AM	<u>A comparative 3D architectural study of the oral musculature at the fibre bundle level.</u> <b>LI<sup>1</sup></b> , Zhi, Adel FATTAH <sup>2</sup> , Dongwoon LEE <sup>3</sup> , Nancy MCKEE <sup>1</sup> , and Anne AGUR <sup>1</sup> . <sup>1</sup> Division of Anatomy, Department of Surgery, University of Toronto, Toronto, ON M5S 1A8, Canada; <sup>2</sup> Department of Plastic Surgery, Alder Hey Children's NHS Foundation Trust, Liverpool L12 2AP United Kingdom; <sup>3</sup> Department of Computer Science, University of Toronto, Toronto, ON M5S 3G4, Canada.	
11:00 AM	<u>Efficacy of undergraduate medical education in anatomical sciences for pathology residency preparation.</u> <b>STERITZ</b> , Matthew J., Lisa M.J. LEE. Modern Human Anatomy Program, University of Colorado School of Medicine. Aurora, CO, 80045, USA.	

## Wednesday, June 10th continued

11:15 AM	<u>The role of ultrasound in surgical decision-making for iatrogenic spinal accessory nerve injuries: A paradigm shift.</u> <b>CESMEBASI</b> , Alper <sup>1,2</sup> , Jay SMITH <sup>3</sup> , and Robert J SPINNER <sup>1</sup> . <sup>1</sup> Department of Neurologic Surgery, Mayo Clinic, Rochester, MN 55905, USA; <sup>2</sup> Department of Anatomical Sciences, St George's University, Grenada, West Indies; <sup>3</sup> Department of Physical Medicine and Rehabilitation, Mayo Clinic, Rochester, MN 55905, USA.
11:30 AM	<u>Creation of an online 'Medical Imaging Solution for Teaching and Research' (MISTR).</u> <b>CARTER</b> Yasmin <sup>1</sup> , Adam MCKENZIE <sup>2</sup> , John COSTA <sup>3</sup> and Brent BURBRIDGE <sup>1</sup> . <sup>1</sup> Medical Imaging, College of Medicine, University of Saskatchewan; <sup>2</sup> Information Communications Technology, University of Saskatchewan; <sup>3</sup> Information Technology, College of Medicine, University of Saskatchewan, Canada.
11:45 AM	<u>Neonatal anatomy of the mediastinal structures at the level of the manubriosternal angle.</u> <b>MIRJALILI</b> , S. Ali <sup>1</sup> , Michael J. SUNDERLAND <sup>1</sup> , Tom IWAN <sup>1</sup> , and James HAMIL <sup>2</sup> . <sup>1</sup> Department of Anatomy with Radiology, Faculty of Medical and Health Sciences, University of Auckland, Auckland, New Zealand; <sup>2</sup> Department of Paediatric Surgery, Starship Hospital, Auckland, New Zealand.
12:00 PM – 1:30 PM	Lunch on your Own – See page 8 for options
12:00 PM – 1:30 PM	Clinical Anatomical Editorial Board Lunch ..... Del Sol Room
1:30 PM – 3:00 PM	Career Development Committee Symposium "Changing Paradigms in Academics" ..... Grand I
3:00 PM – 3:15 PM	Break with Exhibitors/Posters .....Grand II, III, IV
3:15 PM – 4:30 PM	Poster Session 1 (Odd #'s 1 - 59) - Head and Neck .....Grand II, III, IV
4:30 PM – 5:00 PM	Mentee Meeting – Alan Detton .....Del Mar Room
5:00 PM – 6:00 PM	Mentor Reception .....Del Mar Room
6:30 PM – 8:00 PM	Social: "Hischfeld and Leveillé's "Nevrologie et Esthesiologie": the high point of a great anatomical tradition." ..... Grand I

## Scientific Program

### Thursday, June 11th

7:30 AM – 9:00 AM	Educational Affairs Committee Meeting & Low Tech Fair - Open to all .....Del Mar Room
8:00 AM – 5:00 PM	Registration ..... Grand Ballroom Registration Desk
8:30 AM – 9:00 AM	Breakfast with Exhibits/Posters .....Grand II, III, IV
9:00 AM – 9:15 AM	Opening Announcements ..... Grand I
9:15 AM – 10:30 AM	Platform Session 2 - Students Part 2 of 2 ..... Grand I Moderator: Sherry Downie

continued on next page

## Thursday, June 11th continued

- 9:15 AM Anatomical analysis of the ulnar collateral ligament in cadaveric specimens and implications for joint stability and surgical recovery. **GAMBOA**, Jakob E<sup>1</sup>, Luke SANDERS<sup>2</sup>, Geoffrey DORRUS<sup>2</sup>, David A. MORTON<sup>2</sup> and Jonathan J. WISCO<sup>1,2</sup>. <sup>1</sup>Department of Physiology and Developmental Biology, Brigham Young University, Provo, UT. 84602; <sup>2</sup>Department of Neurobiology and Anatomy, University of Utah School of Medicine, Salt Lake City, UT 84132, USA.
- 9:30 AM The snapping medial antebrachial cutaneous nerve. **CESMEBASI**, Alper<sup>1,2</sup>, Shawn W O'DRISCOLL<sup>1</sup>, Jay SMITH<sup>1</sup>, John A SKINNER<sup>1</sup>, and Robert J SPINNER<sup>1</sup>. <sup>1</sup>Mayo Clinic, Rochester, MN 55905, USA; <sup>2</sup>St George's University, Grenada, West Indies.
- 9:45 AM Palmar triquetrum-hamate ligaments determined by lunate type. **AL SAFFAR**<sup>1</sup>, Radi A. and Quentin A. FOGG<sup>1,2</sup>. <sup>1</sup>Laboratory of Human Anatomy, School of Life Sciences, University of Glasgow, Glasgow, G128QQ, UK; <sup>2</sup>Centre for Human Anatomy Education, Monash University, Melbourne, Australia 3800.
- 10:00 AM Architectural partitioning of gluteus medius: An in situ 3D computer modelling study. **SCOLERI**, Yolanda<sup>1</sup>, Shannon ROBERTS<sup>1</sup>, Anne M. AGUR<sup>1</sup>, and Nalini PATHER<sup>2</sup>. <sup>1</sup>Division of Anatomy, Department of Surgery, University of Toronto, Toronto, ON M5S 1A8, Canada; <sup>2</sup>Department of Anatomy, School of Medical Sciences, University of New South Wales, Sydney, NSW 2052, Australia.
- 10:15 AM Comparative analysis of the 3D musculotendinous architecture of the anterior thigh muscles. **CASTANOV**, Valera and Anne M.R. AGUR. Division of Anatomy, Department of Surgery, University of Toronto, Toronto, ON M5S 1A8, Canada.
- 10:30 AM – 10:45 AM Break with Exhibits/Posters.....Grand II, III, IV
- 10:45 AM – 12:00 PM Poster Session 2 (Even #'s 2 - 60) - Limbs .....Grand II, III, IV
- 12:00 PM – 1:15 PM "Anatomy in the New Millennium" Lunch Symposium ..... Grand I
- 1:00 PM - 2:00 PM Posters 1 - 60 Tear Down.....Grand II, III, IV
- 1:15 PM – 2:00 PM Platform Session 3 - Pot Pourri..... Grand I  
Moderator: Jennifer Brueckner-Collins
- 1:15 PM Palmar radiocarpal ligaments: morphological asymmetry between external and internal surfaces. **FOGG**, Quentin A.<sup>1,2</sup>. <sup>1</sup>Centre for Human Anatomy Education, Monash University, Melbourne, Australia 3800; <sup>2</sup>Laboratory of Human Anatomy, School of Life Sciences, University of Glasgow, Glasgow, G128QQ, UK.
- 1:30 PM A new and lifesaving use for old, undefined anatomy. **LOK**, Charmaine E.<sup>1</sup>, Surendra SHENOY<sup>3</sup>, Marc GLICKMAN<sup>4</sup>, William COHN<sup>5</sup>, and Dheeraj RAJAN<sup>2</sup>. Divisions of <sup>1</sup>Nephrology and <sup>2</sup>Radiology, University Health Network, Toronto, ON M5G 2C4, Canada; <sup>3</sup>Division of General Surgery, Section of Transplantation Surgery, Washington University, St. Louis, MO 63110, USA; <sup>4</sup>Sentara Vascular Specialists, Eastern Virginia Medical School, Norfolk, VA 23507, USA; <sup>5</sup>Division of Cardiovascular Surgery, Texas Heart Institute, Baylor College of Medicine, Houston, TX 77030, USA.
- 1:45 PM Use of indocyanine green lymphography for identifying lymphatic structural changes in lymphedema. **SUAMI**, Hiroo, Alexander T. NGUYEN, Edward I. CHANG. Department of Plastic Surgery, The University of Texas, MD Anderson Cancer Center, Houston, TX 77030, USA.



## Thursday, June 11th continued

2:00 PM – 3:00 PM	Posters 61 – 122 Set Up .....	Grand II, III, IV
2:00 PM – 2:15 PM	Break with Exhibits/Posters.....	Grand II, III, IV
2:15 PM – 3:30 PM	CAT Symposium “Towards a Universal Anatomical Terminology for the Health Sciences” .....	Grand I
3:30 PM – 4:45 PM	Poster Session 3 (Odd #'s 61 – 119) - Torso .....	Grand II, III, IV
5:00 PM – 6:00 PM	Reception.....	Grand Foyer
6:00 PM – 8:00 PM	Awards and Banquet.....	Grand I

## Scientific Program

### Friday, June 12th

7:30 AM – 9:00 AM	Anatomical Services Committee Meeting - Open to All .....	Del Mar Room
8:00 AM – 5:00 PM	Registration.....	Grand Ballroom Registration Desk
8:30 AM – 9:00 AM	Breakfast with Exhibits/Posters .....	Grand II, III, IV
9:00 AM – 9:15 AM	Opening Announcements.....	Grand I
9:15 AM – 10:30 AM	Poster Session 4 (Even #'s 62 – 122) - Anatomical Services and Education.....	Grand II, III, IV
10:30 AM – 12:00 PM	Platform Session IV + Tech Fair– Education .....	Grand I
	Moderator: Greg Smith	
10:30 AM	<u>Comparing DirectVision urinary catheterization on multiple cadaver preparations for ideal teaching of healthcare trainees</u> <b>BENNINGER</b> Brion <sup>1,2</sup> , Steven Carmicheal <sup>1</sup> and Tom Schlundt <sup>1</sup> . <sup>1</sup> Willed Body Donation Program, Medical Anatomy Center, Departments of Medical Anatomical Sciences, Neuromuscular Medicine, Family Practice, Western University of Health Sciences, COMP - Northwest, Lebanon, OR. USA; <sup>2</sup> Orthopaedic and General Surgery residency faculty, Samaritan Health Services, Corvallis, OR. USA.	
10:45 AM	<u>Group-based peer teaching with lab quizzes improve student performance in anatomy practical exams.</u> <b>ROQUE</b> , Rouel, Marianna KEGEYAN-TERZIAN, Dan BOLLARD, Yehia MARREEZ, Noel GUISON, and William ROY. Department of Basic Sciences, Touro University Nevada, Henderson, NV 89014 USA.	
11:00 AM	<u>Tracking peer professionalism measures in preclinical medical students.</u> <b>BRUECKNER-COLLINS</b> , Jennifer <sup>1</sup> , Paul KLEIN <sup>2</sup> , Leslee MARTIN <sup>2</sup> , Susan SAWNING <sup>2</sup> , Craig ZIEGLER <sup>2</sup> , Emily CARR <sup>2</sup> , Ann SHAW <sup>2</sup> and Amy HOLTHOUSE <sup>2</sup> . <sup>1</sup> Anatomical Sciences and Neurobiology and <sup>2</sup> Undergraduate Medical Education Office, University of Louisville School of Medicine, Louisville, KY 40202, USA.	
11:15 AM	<u>A new curriculum model for developing pedagogical competencies in future medical educators.</u> <b>ROYER</b> , Danielle F. Department of Cell & Developmental Biology, University of Colorado School of Medicine, Aurora, CO 80045, USA	
11:30 AM	<u>From grave-robbing to a willed body program: 143 years of donor history at University of Louisville.</u> <b>HERRING</b> , Nicole R., Rebecca L. BARKER, Jennifer K. BRUECKNER-COLLINS. Department of Anatomical Sciences and Neurobiology, School of Medicine, University of Louisville, Louisville, KY USA.	

continued on next page

## Friday, June 12th continued

11:45 AM	<u>Development of a programmed learning tool for an innovative approach to the laboratory component of dental gross anatomy.</u> <b>MACPHERSON</b> , Brian R. <sup>1</sup> , and Jennifer K. BRUECKNER-COLLINS <sup>2</sup> . <sup>1</sup> Anatomy and Neurobiology, University of Kentucky College of Medicine, Lexington, KY 40536; <sup>2</sup> Anatomical Sciences and Neurobiology, University of Louisville School of Medicine, Louisville, KY 40202, USA.
11:50 AM	<u>The role and value of highly customized 3D models in the anatomy curriculum.</u> <b>SRIVASTAVA</b> , Sakti, Matt HASEL, Sarah HEGMANN, Joe LANG, Leslie WHITE, Ian WHITMORE. Division of Clinical Anatomy, Stanford School of Medicine, Stanford CA 94305 USA.
11:55 AM	<u>Quantitative assessments on achieving histology competency; first-step toward evidence-based education.</u> <b>LEE</b> , Lisa M.J., Oana ROSENTHAL, Jessica KAHL. Department of Cell and Developmental Biology, University of Colorado School of Medicine. Aurora, CO, 80045, USA.
12:00 PM – 1:00 PM	Lunch Break and Tech Fair Hands On Session ..... Grand I
1:00 PM – 5:00 PM	Exhibitor Tear Down/Poster Tear Down .....Grand II, III, IV
1:00 PM – 2:30 PM	Clinical Anatomical Terminology Committee Meeting - Open to all..... Grand I
2:30 PM – 2:45 PM	Break.....
2:45 PM – 3:45 PM	Platform Session 5 - Pot Pourri ..... Grand I Moderator: Angela McArthur
2:45 PM	<u>Gross and CT measurements of typical cervical vertebrae - guidelines for lateral mass screw fixation</u> <b>SANGARI</b> , Santosh K. <sup>1</sup> , Thomas E. HEINEMAN <sup>2</sup> , Mathew S. CONTI <sup>2</sup> , Paul-Michel F. DOSSOUS <sup>2</sup> , David J. DILLON <sup>2</sup> , Se Young PYO <sup>4</sup> , Apostolos J TSIOURIS <sup>3</sup> , Estomih P. MTUI <sup>1</sup> , Roger HARTL <sup>4</sup> . <sup>1</sup> Program in Anatomy and Body Visualization, Weill Cornell Medical College, New York; <sup>2</sup> Medical student, Weill Cornell Medical College, New York; <sup>3</sup> Clinical Radiology, New York Presbyterian Hospital, Weill Cornell Medical Center, New York; <sup>4</sup> Brain and Spine Center, Weill Cornell Medical College, New York.
3:00 PM	<u>The lysosome concept: comparative morphology for a better understanding of the sentinel node.</u> <b>SUAMI</b> , Hiroo, Department of Plastic Surgery, The University of Texas, MD Anderson Cancer Center, Houston, TX 77030, USA.
3:15 PM	<u>Revisiting the anatomy of the ilio-inguinal/iliohypogastric nerve block.</u> <b>VAN SCHOOR</b> Albert-Neels <sup>1</sup> Marius C BOSMAN <sup>1</sup> , and Adrian T BOSENBERG <sup>2</sup> . <sup>1</sup> Department of Anatomy, School of Medicine, Faculty of Health Sciences, University of Pretoria, Pretoria, South Africa; <sup>2</sup> Department of Anesthesiology and Pain Management, University of Washington and Seattle Children's Hospital, Seattle, USA.
3:30 PM	<u>DVD demonstration of dissection of the female pelvic lymphatic pathways to the thoracic duct: Special reference to the para-aortic chains.</u> <b>SATO</b> , Tatsuo. Tokyo Ariake University of Medical and Health Sciences, Koto City, Tokyo, 135-0063, Japan.
3:45 PM - 4:00 PM	Break
4:00 PM – 5:00 PM	Business Meeting & Awards Ceremony ..... Grand I
5:00 PM – 6:00 PM	New AACA Council Meeting and MOPP Committee ..... Del Mar

# The 2015 Presidential Speaker

Wednesday, June 10th at 9:30 AM

**Francine Mary Netter**



## ***Medicine's Michelangelo, the life and art of Frank H. Netter, MD.***

Frank Netter was both a doctor and artist whose genius was such that he not only grasped the most complex medical concepts, but he could make drawings that made those concepts clear to others. Beginning in the mid-20th century, his books of illustrations — thirteen atlases and over 200 pamphlets — educated doctors and health care professionals the world over. His award-winning Atlas of Human Anatomy is today the most popular and best-selling anatomy atlas in the English language.

**MEDICINE'S MICHELANGELO: The Life & Art of Frank H. Netter, MD**, written by his daughter Francine Mary Netter (October, 2013; \$39.95; Quinnipiac University Press), is the first biography of this illustrious figure revered by generations of students of medicine. Netter was the son of working class immigrants who owned a stationery store in the theater district of New York. In his youth, all he ever wanted to do was to paint, yet he entered medical school at the urging of his mother. He finished an internship in medicine and surgery at Bellevue Hospital, but found that there was more demand for his sable brush than for his scalpel, and for the next fifty years devoted himself full time to making medical illustrations. Netter moved in both the glamorous New York art world and intellectual medical circles. He lived in opulent homes on Long Island and in Palm Beach, lunched at the Society of Illustrators with the likes of Norman Rockwell and Rube Goldberg, and at the great teaching hospitals consulted with hundreds of medical experts, including Drs. Michael DeBakey, C. Everett Koop, Albert Sabin and Paul Dudley White, and single-handedly documented the great medical advances of the 20th century. Francine Mary Netter captures the character of the man and tells his life story using not only her remembrances but also her father's own autobiographical notes, personal correspondence and private files, publications of his work and public archives, and more than 100 interviews with family members, artists, distinguished practitioners and scientists. More than an account of his momentous career, *Medicine's Michelangelo* provides a personal introduction to the man behind the art.

**Francine Mary Netter** is the daughter of Frank H. Netter, MD. She grew up on Long Island, where her father had a large art studio in the family home. She spent many hours with him there while he drew and painted his magnificent pictures. She has a BA from North Carolina State University, an MA from Hofstra University and an MBA from the University of North Carolina. She has written on the history of medicine for numerous publications. She now lives in North Carolina with her husband Ralph Roberson. Her three children live nearby.

# Honored Member 2015

## The American Association of Clinical Anatomists

Recognizes and Awards  
Honored Membership to



### ***Carol E. Scott-Conner, EH, MD, Ph.D., FACS***

Carol Scott-Conner received her MD at the New York University School of Medicine, where she subsequently completed her surgery residency. Her first academic job was at Marshall University College of Medicine in Huntington, WV. While there, she began a life-long collaboration with David Dawson PhD in the Department of Anatomy. In 1993, the first edition of Scott-Conner and Dawson's textbook, *Operative Anatomy*, was published. Over those years and the ones that followed at the University of Mississippi, she attained her PhD in Anatomy from the University of Kentucky under the direction of Betty Sissen PhD. In 1995 she was recruited to become Professor and Head of the Department of Surgery at the University of Iowa College of Medicine, becoming the second woman in the history of American surgery to attain such a position. She has authored or edited more than ten textbooks on surgical technique and anatomy. She is also the author of a book of short stories. For more than a decade, she has participated on committees for the Institute of Medicine advisory to NASA on healthcare issues for astronauts. She was a founding member of the AACA, has served on the Executive Council, has been on the editorial board of *Clinical Anatomy*, hosted the annual meeting at the University of Iowa, has served as president, and has been the honored recipient of the R. Benton Adkins Jr. Distinguished Service Award.

#### **Previous Honored Members of the AACA**

\*W. Henry Hollinshead, 1984  
\*Chester B. McVay, 1985  
\*Donald James Gray, 1986  
\*Russell T. Woodburne, 1987  
Oliver Beahrs, 1988  
N. Alan Green, 1989  
\*Frank H. Netter, 1990  
\*Ralph Ger, 1991  
M. Roy Schwartz, 1992  
Carmin D. Clemente, 1993  
Keith L. Moore, 1994

\*Ray J. Scothorne, 1995  
Robert A. Chase, 1996  
Tatsuo Sato, 1997  
\*John E. Skandalakis, 1998  
Donald R. Cahill, 1999  
\*Sandy C. Marks, Jr., 2000  
David G. Whitlock, 2001  
Robert D. Acland, 2002  
Arthur F. Dalley, II, 2003  
\*John V. Basmajian, 2004  
Ian Whitmore, 2005

Peter H. Abrahams, 2006  
Gary G. Wind, 2007  
Vid Persaud, 2008  
Richard S. Snell, 2009  
Ray Gasser, 2010  
Harold Ellis, 2011  
Ronald A. Bergman, 2012  
John T. Hansen, 2013  
Victor M. Spitzer, 2014

\* deceased

# **R. Benton Adkins Jr. Distinguished Service Award 2015**



**The American Association of Clinical Anatomists**  
Recognizes and Awards the  
R. Benton Adkins Jr. Distinguished Service Award posthumously to

## ***Lawrence M. Ross, MD, Ph.D.***

Lawrence McIvor Ross, 76, passed away Sunday March 1, 2015. Lawrence M. Ross, was Adjunct Professor in the Department of Neurobiology & Anatomy, received his B.A. degree from the University of St. Thomas in Houston in 1960, his Ph.D. and M.D. degrees from the University of Texas Medical Branch - Galveston in 1966 and 1968 respectively. He was a faculty member in the Department of Anatomy at UTMB from 1968 to 1973. From 1973 to 2000, he was a member of the faculty in the Department of Anatomy at Michigan State University in East Lansing, Michigan. He retired from Michigan State as Professor of Anatomy in August, 2000. During his 27 years at Michigan State University he taught Gross Anatomy, Histology, and Embryology. He was the course director of Gross Anatomy for 10 years, and course director of Histology for 8 years. He spent 5 years in curriculum administration. He had administrative oversight of the Willd Body Program at MSU for 21 years, and served on the State of Michigan's State Anatomical Board for 19 years, holding all major offices on the Board.

During his career, Dr. Ross taught medical students seeking M.D. and D.O. degrees, a wide variety of surgical residents, allied health professionals, undergraduate students, attorneys, and worker's compensation practitioners. He has been a Visiting Professor at St. George's University on Grenada in the West Indies. He has received teaching awards from the medical students at MSU and UT, and was a member of Alpha Omega Alpha. He served as Councilor, Secretary and in the Presidential stream for the American Association of Clinical Anatomists.

His research activities have been in the fields of teratology, respiratory histophysiology, clinical anatomy, instructional video production, and computer aided instruction. He was a co-author of a textbook entitled "Case Files in Gross Anatomy", and he was a Consulting Editor for the English Edition of the 3 volume "Thieme Atlas of Anatomy". He co-authored the 2nd Edition of "Atlas of Anatomy" for Thieme Publishers with Anne Gilroy and Brian MacPherson.

Dr. Ross and his wife Irene, a former nurse at Methodist Hospital in Houston, have 5 grown children: Jennifer, Jocelyn, Lawrence Jr., Tricia and Trey, and four grandchildren.

### **Previous R. Benton Adkins Jr. Distinguished Service Award Recipients**

2004 – Robert J. Leonard

2011 – Carol Scott-Conner

2006 – Daniel O. Graney

2012 – Keith L. Moore

2007 – Ralph Ger

2013 – Stephen W. Carmichael

2009 – Arthur F. Dalley



# Career Development Committee Symposium

Wednesday, June 10th  
1:30 PM – 3:00 PM

## ***“Changing Paradigms in Academics”***

---

### ***Anatomists & Hollywood*** **Andrew Cawrse**



The influence of anatomists and anatomical sciences in Hollywood, Media & Art. Expanding anatomists' roles into new realms of entertainment, Virtual education and alternative career paths.

**Andrew Cawrse** is one of the world's most sought after aesthetic anatomy instructors, he teaches in both traditional and digital mediums, tutoring surgeons, physicians, fine art professionals and artists in the movie visual effects & game industries.

Established worldwide as an authority on artistic anatomy and instruction he is recognized as a creator of some of the world's most incredible anatomical sculptures & products for anatomy education. His anatomical work has been shown on the BBC, The History channel, The Discovery Channel, Bravo, Mythbusters and a variety of forensic and educational programming worldwide.

Andrew also has a distinguished background in movie VFX, with over 9 years at Industrial Light & Magic as a model supervisor & digital concept sculptor. His effects work has been featured in the films Avatar, The Spiderwick Chronicles, Van Helsing, Dreamcatcher, Star Wars Episode I & II, Mission to Mars & Galaxy Quest, & technical consultant on Pirates of The Caribbean II, and The Avengers. Andrew left the entertainment industry to pursue his interest in Anatomy.

Andrew also is an accomplished figurative fine-art sculptor. His work has been shown in New York by the National Sculpture Society by award & invitation, and he is scheduled to release his private exhibition and collection of works in 2016. To join his private fine art mailing list, please visit: [andrewscawrse.com](http://andrewscawrse.com).

---

### ***Anatomical services in support of cadaver based surgical training*** **Frank Daly, Ph.D.**

At the University of New England (UNE), cadavers are utilized in a variety of health science programs, including Osteopathic medicine, dentistry, physical / occupational therapy, and athletic training. UNE has also been able to offer outside groups the opportunity to access laboratory resources.

On average, approximately 70 anatomical donors are utilized for academic programs each year. Renovation of the cadaver lab has allowed us to offer outside groups from area hospitals, regional manufacturers and national associations the opportunity to utilize UNE's laboratory resources while some of the smaller courses are running simultaneously. UNE supplies outside groups with both embalmed and fresh specimens (in limited number) and has recently started working with Thiel embalmed specimens. Access to ongoing medical student dissections augments post-graduate surgical training with the ability to quickly move from surgical preparations to anatomical specimens.



*continued on next page*


## Career Development Committee Symposium continued

Often the outside groups are in the final steps of research and development of new surgical implants or instruments. UNE has also served as a training site for sales staff of surgical equipment manufacturers, sometimes utilizing UNE anatomists as extra educational staff. Occasionally, individual surgeons will request space and materials to practice techniques or try new surgical approaches. As real-time imaging of injection becomes more commonplace, training for ultrasound and fluoroscope guided joint injection takes place on a more regular basis.

**Frank Daly**, Ph.D. received his doctorate in anatomy and neurobiology from Boston University School of Medicine. He completed his post-doctoral research as a Howard Hughes Medical Institute Fellow at Massachusetts General Hospital. He joined the faculty of the College of Health Professions at the University of New England in 1999. He is currently an associate professor in the Department of Biomedical Sciences in the College of Osteopathic Medicine at the University of New England and director of the Anatomical Donor Board of the State of Maine.

Dr. Daly teaches gross anatomy, histology & embryology in the first year medical student Osteopathic Clinical Skills course. He is also course director for gross anatomy and systems histology courses for dental students.

## *Current and future relationship of anatomists and surgeons in clinical teaching*



### ***Roy Phitayakorn, MD MHPE (MEd) FACS***

Historically, anatomists and surgeons were closely aligned and allied to advance the field of surgical education and training. Unfortunately, over time, this relationship was strained as more anatomists were placed in universities and anatomy training was focused into the pre-clinical years of medical schools. However, as funding for anatomy programs decline, there are many exciting opportunities to rekindle the anatomist and surgeon relationship to enhance medical knowledge and skills and even develop new technologies to create operations that would have been impossible just ten years ago. This interactive talk will discuss the current state of surgical education and focus on ways anatomists and surgeons can work together both now and towards the future.

**Dr. Roy Phitayakorn** completed his residency training in general surgery at Case Western Reserve University in 2009 and completed an endocrine surgery fellowship at the Massachusetts General Hospital in 2011. He is currently an

Assistant Professor of Surgery with a practice in general surgery and endocrine surgery. Dr. Phitayakorn is also the MGH Director of Surgical Education Research, the Surgical Lead for Strategic Initiatives and Operations at the MGH Learning Laboratory, and the Co-Director of the American College of Surgeons accredited MGH Surgical Education and Simulation Research Fellowship program.

Dr. Phitayakorn also has a Masters degree in Medical Education from the University of Illinois at Chicago (MHPE). His MHPE thesis was on phone communication preferences of general surgery residents and attendings and won the best thesis award in 2007 and also best presentation at the 2008 MHPE medical education conference.

Finally, Dr. Phitayakorn is an external consultant for the American Board of Surgery and a faculty member for several national medical education courses and institutions including the Harvard Macy Institute, the ACS Surgeons as Educators course, and the Institute of Medical Simulation.

## NOTES:

---

---

---

---

---

---

---

# Social: “Hirschfeld and Leveillé’s ‘Nevrologie et Esthesiologie’: the high point of a great anatomical tradition.”

**Wednesday, June 10th**  
**6:30 PM – 8:00 PM**

*The session will highlight Hirschfeld and Léveillé’s colored lithographic atlas of neuroanatomy, published in 1855, one of the finest anatomical works ever created.*

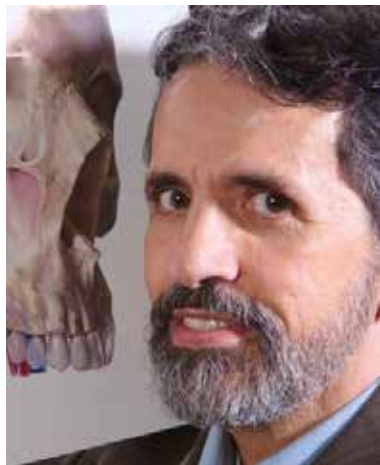
## ***Lithography: a revolution in visual representation.***

### ***Robert D Acland, MD, FRCS, University of Louisville***

Dr. Acland will describe how the invention of lithography in 1798 and its perfection in France in the early 1800s led to a succession of anatomical masterpieces, culminating in Hirschfeld and Léveillé’s “Nevrologie et Esthesiologie” in 1855. He will describe how lithography works and how it was an advance on previous techniques.

Acland will show some of the masterpieces of the French anatomical tradition leading up to those of Ludwig Hirschfeld and his artist-collaborator Jean-Baptiste Léveillé.

Dr. Robert Acland is a professor emeritus in the Department of Anatomical Sciences at the University of Louisville School of Medicine. He gained his interest in anatomy during his first career as a reconstructive microsurgeon. In his second career as a clinical anatomist, Dr. Acland directed his school’s Fresh Tissue Dissection Laboratory, where he taught anatomy to students and surgeons, pursued anatomical research, and created his “Video Atlas of Human Anatomy”.



## ***The art of Jean Baptiste Léveillé***

### ***Carlos Machado, M.D.***

Dr. Machado will analyze the artworks of the Atlas of Hirschfeld and Léveillé from the point of view of an artist; and will describe the important teamwork between anatomist and artist that is so evident in this work.

Before his artistic talents took his career in a different direction, Dr. Machado practiced medicine as a cardiologist in Rio de Janeiro, Brazil. His skill in medical illustration came to the attention of Ciba-Geigy, which at that time controlled the illustration work initiated by Dr. Frank Netter. Dr. Machado has contributed to the Netter Collection of Medical Illustrations for nineteen years, adding over 1,000 new illustrations to the collection, and updating many of the images to reflect current medical practice and knowledge.

## ***The life and times of Hirszfeld Ludwik Maurycy (Ludovic Hirschfeld) 1816-1876***

### ***Jerzy Stanislaw Gielecki, MD, PhD, DSc, Department of Anatomy, University of Warmia and Masuria***

Prof. Gielecki’s talk will describe the anatomist’s origins, his rise from humble beginnings to professor in the Anatomical Institute of Paris, and his subsequent career in his native Poland. Prof. Gielecki was born and raised in Hrubieszow, Poland. He commenced medical studies at Lublin Medical University and received his MD in 1985, PhD in 1988, and DSc. degree in 1999 at the Warsaw Medical University. In 2000 he became head of the Department of Anatomy at the Medical University of Silesia in Katowice. Since 2008 he has been the head of the Department of Anatomy at the University of Warmia and Masuria (UWM) in Olsztyn (Poland) and has worked as a visiting professor at St. George’s University in Grenada. In 2009 Dr. Gielecki became the Dean for Education at the Faculty of Medical Sciences UWM. Dr. Gielecki has authored 22 books and monographs, 6 book chapters, 81 research papers and 105 abstracts. Prof. Gielecki focuses on development of the cerebral arteries, and new methods of interactive stereoscopic projection in 3D space.



# **“Anatomy in the New Millennium” Lunch Symposium**

**Thursday, June 11th  
12:00 PM – 1:15 PM**

The editors of *Clinical Anatomy* and I are happy to offer you our second Journal sponsored symposium. This year's symposium is a luncheon (free lunches to the first 200 attendees) and focuses on changes in how anatomy is presented and taught in this new era. We are elated to have three world-renowned speakers. Elsevier is kindly supporting the presentation of Dr. Susan Standring, who is the editor-in-chief of *Gray's Anatomy*. Wiley, the publisher of our Journal, with developmental funds, is supporting our lunch and the presentations of Drs. Wolanskyj and Benninger. Dr. Wolanskyj is Senior Associate Dean of Student Affairs at Mayo Medical School and Dr. Benninger is Executive Director of the Medical Anatomy Center in Lebanon, Oregon.

We hope that you will be able to join us for this enlightening session!

Shane Tubbs

Editor-in-Chief *Clinical Anatomy*

## **“2015: Strategies for Teaching Anatomy to Nearly 2,000 Medical Students a Year”**

Dr. Loukas received his M.D. degree from Warsaw University School of Medicine, and a Ph.D. from the Institute of Rheumatology in the Department of Pathology in Warsaw, Poland. He held a post-doctoral position at the Ulm University Clinic in Germany and studied arteriogenesis and angiogenesis projects.

He began his academic career at Harvard Medical School where he served as lecturer and laboratory instructor for the Human Body Course. In 2005, he joined St. George's University in Grenada where he rose to the rank of a professor. In 2008, he was named Chair of the Department of Anatomical Sciences and Assistant Dean of Basic and Allied Health Sciences. Under his leadership, the Department of Anatomical Sciences developed a unique division of Ultrasound in Medical Education that instructs faculty members in how to teach ultrasound to medical students and residents, and how to provide effective continuing medical education (CME) courses.

In 2012, Dr. Loukas was appointed Dean of Research for the School of Medicine at St. George's University. One of his main tasks was to develop a transdisciplinary research infrastructure to support translational research to bridge basic science and clinical departments with the aim of enhancing student research and publications. Since that time, the School of Medicine has published over 100 scientific papers each year in peer-reviewed journals. In 2015, Dr. Loukas was appointed as Dean of Basic Sciences at St. George's University, School of Medicine.

Dr. Loukas' research has been continuously funded from St. George's University. He has been the recipient of numerous teaching research awards such as the Herbert M. Stauffer Award from the Association of University Radiologists and Harvard Excellence in Tutoring Award from Harvard Medical School in 2007. In 2015, Dr. Loukas was appointed as editor-in-chief of the journal *Translational Research in Anatomy* published by Elsevier.

Dr. Loukas has published over 532 papers in peer reviewed journals, authored 15 books, which include *Gray's Anatomy Review*, *Gray's Clinical Photographic Dissector of the Human Body*, *McMinn and Abrahams's Clinical Atlas of Human Anatomy* 7th ed. and has authored 14 chapters in various medical and surgical books. He has also served as an editor and co-editor for 12 journals and reviewer for over 40 journals. His scientific interests include surgical anatomy and technique, cardiovascular pathology and medical education. Recently, his focus has been directed toward issues of integrated curriculum and faculty development in medical education with an emphasis on simulation and technology and effective teaching and assessment.



*continued on next page*



**“Millennial Learners-How to Effectively Teach Generation Y”**  
**Dr. Alexandra Wolanskyj, M.D.**

Dr. Alexandra Wolanskyj, M.D., a native of Quebec, graduated from the University of Montreal. She has been on the staff of the Mayo Clinic since 2002 following training there in Internal Medicine and Hematology and Oncology. Dr Wolanskyj has been chair of the Hematology course at Mayo Medical School creating a new and integrated curriculum. She has been Program Director of the Hematology-Oncology fellowship and Chair of Education for Hematology, during which time she created innovative educational curricula through simulation. She has successfully mentored many medical students, residents and fellows in these roles. She has received the Mayo Fellows Association Teacher of the Year award (2006), the Hematology Fellowship Teacher of the year award (2006) and the Mayo Medical School Teacher of the Year award (2010). Currently, she serves as the senior associate Dean for student affairs at Mayo Medical School and the Vice chair for the AAMC Steering committee for the Central Group on Student Affairs. She is recognized nationally for her expertise in intergenerational learning.



.....

**“Google Glass and Ultrasound-the Anatomy Teacher of the Future?”**  
**Brion Benninger, MD, MB, ChB, MSc**

Brion Benninger, Professor, Executive Director of the Medical Anatomy Center where education and science meet medicine, Western University of Health Sciences, Lebanon, Oregon. Residency faculty General Surgery, Orthopaedics and Sports Medicine Samaritan Health Services, Corvallis, Oregon and Surgery, Orthopaedics & Rehabilitation OHSU, Portland Oregon.

Professor Benninger has been on the cutting edge of technology by developing, promoting and integrating optical head mounted displays (e.g. Google Glass), novel ultrasound finger probes (e.g. SonicEye), visualization table (e.g. Sectra) and Glass optical urinary catheterization (e.g. PercuVision), providing innovative medical education, basic and clinical science research and invasive techniques with an emphasis on anatomy and imaging. His formal training as a physician (trauma and sports medicine) and clinical anatomist has provided him with insights into medical education, physical examination and invasive techniques. He has received several teaching awards by faculty and students from multiple institutions and countries. He was the first Chair of Anatomy to receive an accreditation Commendation Award, for his vision and innovative teaching methods. His innovation and use of technology in research has benefited both military and civilian medicine. He was the first to conduct research using Google Glass in an anatomy lab and the first to combine ultrasound finger probes with Glass while examining a patient, which is being patented as Triple feedback technique and practiced in anatomy lab courses. First to combine 3D visualization table with actual cadaver CT/MRI prior, during and post dissection as part of an anatomy lab course. He has mentored over 100 medical/dental students who have presented research at national and international conferences. He continues to pioneer medical anatomy by integrating it with technology and disruptive innovation.





# Clinical Anatomical Terminology Committee Symposium “Towards a Universal Anatomical Terminology for the Health Sciences”

Thursday, June 11th  
2:15 PM – 3:30 PM

---

## *Towards a Universal Anatomical Terminology for the Health Sciences*

### ***John Fraher MB, FRCS Edin, PhD, DSc, FAS (hon), MRIA***

Professor Emeritus of Anatomy  
University College Cork

Effective communication depends on a precise, common vocabulary. There is a need for a universally accepted anatomical terminology across the health sciences, and Terminologia Anatomica (TA), the official terminology of the International Federation of Associations of Anatomists [IFAA], can play a key role in fulfilling this. [TA is based in one of the six sections of the IFAA, namely, FIPAT – the Federative Programme for Anatomical Terminology, which also contains Terminologia Embryologica (TE).]

In realising the defined aim, there are obstacles to be overcome. For example, while TA specifies the official term, there are commonly synonyms for a particular entity. This difficulty can be resolved through prioritisation and by means of cross-links between TA in its Informatics format and other systems of terminology, such as Anatomical Terminology. info. Other challenges arise from the continual generation of new terms in areas of clinical practice and of anatomical science such as embryology. Furthermore, a given entity may have different names in TA and in a particular clinical discipline [terminological drift]. In addition, entities lacking names in TA may have been given them in clinical fields such as imaging, neurosurgery and vascular surgery. Corresponding challenges arise for TE in relation to areas such as in vitro fertilisation, stem cell biology, neuroscience and congenital anomalies.

Such disparities in anatomical terminology can be resolved through constructive interaction between anatomists and, e.g., clinicians, embryologists and neuroscientists. Regular updating of TA and TE on the FIPAT/IFAA website will provide for feedback and enable continual incorporation of new and refined terms. The ideal outcome is a universal anatomical terminology, relevant across all of the health sciences.

The presentation will focus on the content of the abstract, and in doing so the following themes will arise:

1. The need for a standardized anatomical terminology across the health sciences
2. The key role for Anatomy in achieving this
3. The organizational structure, the role and the objectives of the International Federation of Associations of Anatomists [IFAA]
4. Historical development of Anatomical Terminology
5. Terminologies of and for today
6. The Federative International Programme for Anatomical Terminology [FIPAT]
  - Sections
  - Terminologia Anatomica
7. Challenges for Anatomy
  - Rationalization of terms between anatomy and clinical disciplines
  - Equivalent challenges in embryological terminology
  - The need to rationalize the situation regarding synonyms and related terms
8. The role of Websites in achieving these objectives

*continued on next page*

## Clinical Anatomical Terminology Committee Symposium continued

**Dr John Fraher** qualified in Medicine and Science from University College Cork, Ireland. He has the PhD and DSc degrees from the University of Edinburgh. He is FRCS Edinburgh, an Honorary Fellow of the Anatomical Society and a Member of the Royal Irish Academy.

He held tenured posts at the Universities of Edinburgh and London before becoming Professor and head of the Anatomy Department at University College Cork (UCC), where he established Neuroscience as a teaching and research discipline. He was Foundation Director of UCC's flagship BioSciences Institute. He has been President of the Anatomical Society of Great Britain & Ireland and also of the European Federation for Experimental Morphology. He is Chair of the Federative International Programme for Anatomical Terminology of the International Federation of Associations of Anatomists.



His undergraduate and postgraduate teaching experience has spanned all aspects of Anatomy in Medical, Dental, Science, Therapies, Arts and Mechanical Engineering [Human Biomechanics] disciplines. His graduate teaching included programmes for trainees in Surgery, Psychiatry and Radiology, as well as for professionals in medical device manufacture for various multinational corporations. He was instrumental in initiating the joint Anatomy teaching training programme between the Anatomical Society of Great Britain & Ireland and the American Association of Anatomists, for professionals in the discipline. Also he has a lifelong passion for Art History [the human body in painting], involving series of public lectures and broadcasts.

His principal research field is in Developmental Neuroscience [myelination, nerve fibre development, axon-myelin relationships; establishment and formation of the CNS-PNS Transitional Zone in spinal and cranial nerves], in which he has over 200 publications. Other research extends to comparative anatomy and the anatomical analysis of images of the human body in painting.

## NOTES:

[illegible]

# Poster Listings

## Poster Session 1 – Head and Neck

Wednesday, June 10 3:15 – 4:30 PM

(Set up time: Wednesday, June 10 from 8:30 AM until 10:30 AM; Take down time: Thursday, June 11 from 1:00 PM until 2:00 PM)

*\*Denotes abstract will be published in Clinical Anatomy if poster is presented as planned.*

### Poster #Abstract Title/Authors

- 001\* Morphological study of the parietal emissary foramen and their clinical importance. SARALAYA, Vasudha V., and Murlimanju B. VIRUPAKSHAMURTHY. Department of Anatomy, Kasturba Medical College, Mangalore-575004, Manipal University, Manipal, Karnataka, India.
- 003 Circle of Willis vasculature anomalies - a comparison between Dutch and American Cadavers. NILSSON, Wesley, Dae KIM, and Ijoma NWOSU. American University of the Caribbean, Cupecoy, Dutch Lowlands, Sint Maarten, Dutch West Indies.
- 005\* Bilateral agenesis of the facial arteries: compensation by inferior transverse facial arteries. LEE, Vaughan H, Christian BEZBORUAH, Carlos MARTINEZ, Fahmida MUSHAROF, Christine RIDDLE, and Phuong TRINH. Texas Tech University, Department of Medical Education, Lubbock, TX 79430, USA.
- 007 Anatomic imaging analysis for the facial structures affect facial aging. OKUDA, Itsuko<sup>1</sup>, Keiichi AKITA<sup>2</sup>, and Yasuo NAKAJIMA<sup>3</sup>. <sup>1</sup>Department of Diagnostic Radiology, International University of Health and Welfare, Mita Hospital, Tokyo, 1088329, Japan; <sup>2</sup>Department of Clinical Anatomy, Graduate School of Medical and Dental Sciences, Tokyo Medical and Dental University, Tokyo 1138519, Japan; <sup>3</sup>Department of Radiology, St. Marianna University School of Medicine, Kanagawa, 2168511, Japan.
- 009\* Pectoralis minor transfer for facial reanimation: Architectural study of donor and recipient muscles. ROBERTS, Shannon L.<sup>1</sup>, Zhi LI<sup>1</sup>, Adel FATTAH<sup>2</sup>, Nancy MCKEE<sup>3</sup>, and Anne M. AGUR<sup>1</sup>. <sup>1</sup>Division of Anatomy, Department of Surgery, University of Toronto, Toronto, ON M5S 1A8, Canada; <sup>2</sup>Department of Plastic Surgery, Alder Hey Children's NHS Foundation Trust, Liverpool L12 2AP, United Kingdom; <sup>3</sup>Division of Plastic and Reconstructive Surgery, Department of Surgery, University of Toronto, Toronto, ON M5T 1P5, Canada.
- 011\* Medical illustration highlighting the 3D morphology of the temporomandibular joint articular disc. D'ANTONI, Anthony V<sup>1</sup>, and Carlos A. G. MACHADO<sup>2,3,4</sup>. <sup>1</sup>Department of Pathobiology, The Sophie Davis School of Biomedical Education, The City College of New York, CUNY, New York, NY 10031, USA; <sup>2</sup>Medical Illustrator, Austin, TX 78759, USA; <sup>3</sup>Department of Pathophysiology, The University of Saint Augustine for Health Sciences at Austin, Austin, TX 78739, USA; <sup>4</sup>Department of Cellular and Structural Biology, The University of Texas Health Science Center at San Antonio, San Antonio, TX 78229, USA.
- 013\* Pterygospinous and pterygoalar ligament presence as an etiology of trigeminal neuralgia. BUSCH, Kyle J., and Anthony B. OLINGER. Department of Anatomy, Kansas City University of Medicine and Biosciences, Kansas City, MO 64106, USA.
- 015\* A cadaver study of the Gow-Gates nerve block technique approximation to the maxillary artery and inferior alveolar nerve. DEWAN, Dale, and Sherif HASSAN. A. T. Still University, Missouri School of Dentistry and Oral Health, Kirksville College of Osteopathic Medicine, Kirksville, MO 63501, USA.

*continued on next page*

## Poster Session 1 – Head and Neck continued

- 017\* Evaluation of the pediatric maxillary nerve block. BOSMAN Marius C.<sup>1</sup>, Lané PRIGGE<sup>1,2</sup>, Adrian T. BOSENBERG<sup>3</sup>, and Albert-Neels VAN SCHOOR<sup>1</sup> <sup>1</sup>Department of Anatomy, School of Medicine, Faculty of Health Sciences, University of Pretoria, Pretoria, South Africa. <sup>2</sup>Department of Anatomy, Sefako Magkatho Health Sciences University, Garankuwa, South Africa, <sup>3</sup>Department of Anesthesiology and Pain Management, University of Washington and Seattle Children's Hospital, Seattle, USA.
- 019\* Assessment of anterior petrosectomy: cadaveric and radiographic analysis of adjunct to subtemporal approach. THERIOT, Krystle B<sup>1</sup>, Osama AHMED<sup>2</sup>, Jonathan WALTHER<sup>3</sup>, and Bharat GUTHIKONDA<sup>2</sup>. <sup>1</sup>Department of Cellular Biology and Anatomy; <sup>2</sup>Department of Neurosurgery; <sup>3</sup>School of Medicine. LSU Health Science Center, Shreveport, LA 71130, USA.
- 021 Pilot study of anatomical complications for maxillary dental implants using cone beam computed tomography. WEISS II, Robert O., Takanari MIYAMOTO, and Neil S. NORTON, Creighton University School of Dentistry, Omaha, NE 68178, USA.
- 023\* TREM-1 and TREM-2 protein expression in normal and healthy human gingival tissue. PUETZ III, William J., Laura C. BARRITT, Jason M. KUM, Sonia M. SANCHEZ, Shikha TARANG, Barbara J. O'KANE. Department of Oral Biology, School of Dentistry, Creighton University, Omaha, NE 68178, USA.
- 025 Determination of Expression of TREM-1 and TREM-2 in Oral Keratinocytes. KUM, Jason M., Laura C. BARRITT, William J. PUETZ, Sonia M. SANCHEZ, Shikha TARANG, and Barbara J. O'KANE. Department of Oral Biology, School of Dentistry, Creighton University, Omaha, NE 68178, USA.
- 027\* Anatomic and radiologic correlation of accessory mental foramina and nerves. IWANAGA Joe<sup>1,2</sup>, Tsuyoshi SAGA<sup>1</sup>, Yoko TABIRA<sup>1</sup>, Sadaharu KITASHIMA<sup>1,2</sup>, Koichi WATANABE<sup>1</sup>, Jingo KUSUKAWA<sup>2</sup>, Koh-ichi YAMAKI<sup>1</sup>. <sup>1</sup>Department of Anatomy, Kurume University School of Medicine, Kurume, Fukuoka, 830-0011, Japan; <sup>2</sup>Dental and Oral Medical Center, Kurume University School of Medicine, Kurume, Fukuoka, 830-0011, Japan.
- 029\* A literature review of the influence of the stomatognathic system on body posture. NATION, Philip B. and Margaret A. JERGENSON. Department of Oral Biology, School of Dentistry, Creighton University, Omaha, NE 68178, USA.
- 031\* Illustration of the mylohyoid muscle: a historical overview. MAHDI, Ali, Zhi LI, Shannon ROBERTS, and Anne AGUR. Division of Anatomy, Department of Surgery, University of Toronto, Toronto, ON M5S 1A8, Canada.
- 033\* Evolution of the anatomical illustration and understanding of the digastric muscle. SAWYER, F. Kip<sup>1</sup>, Stephanie M. SHAW<sup>2</sup>, and Anne M.R. AGUR<sup>1</sup>. <sup>1</sup>Division of Anatomy, Department of Surgery, University of Toronto, Toronto, ON M5S 1A8, Canada; <sup>2</sup>Department of Speech-Language Pathology, University of Toronto, Toronto, ON M5G 1V7, Canada.
- 035\* An anatomical study of the arterial and nerve supply of the infrahyoid muscles. ABDEL MEGUID, Eiman M.<sup>1</sup>, and Amany E. AGAWANY<sup>2</sup>. <sup>1</sup>Centre of Biomedical Sciences Education, Queen's University Belfast, BT7 1NN, United Kingdom; <sup>2</sup>Department of Anatomy, Faculty of Medicine, University of Alexandria, Egypt.

## Poster Session 1 – Head and Neck continued

- 037\* Interrelationships between the insertions of the infrahyoid muscles. SAKAMOTO, Yujiro. Graduate School of Medical and Dental Sciences. Tokyo Medical and Dental University. Tokyo 113-8549, Japan.
- 039\* Botox injections into the scalene triangle compromises thoracic outlet syndrome (TOS) patients as displayed by MRI, MRA, MRV. COLLINS, James D, Ernestina H SAXTON, Hugh GELABERT, Alfred CARNES. Department of Radiological sciences, David Geffen School of Medicine, University of California, Los Angeles, Los Angeles, CA 90024, USA.
- 041\* The internal carotid artery, oculomotor, trochlear, ophthalmic, maxillary and abducens nerves in relation to the cavernous sinus. KAUTZ, Mandalyn J. and Anthony B. OLINGER. Department of Anatomy, Kansas City University, Kansas City, MO 64106, USA.
- 043\* Affect of cervical siphon of external and internal carotid arteries: A case report. SINGH Rajani<sup>1</sup>, R. Shane TUBBS<sup>2</sup>. <sup>1</sup>Department of Anatomy, AIIMS, Rishikesh 249201 Uttarakhand, India; <sup>2</sup>Pediatric Neurosurgery, Children's of Alabama, Birmingham AL, 35233 USA
- 045\* Two cases of the dual origin of left vertebral artery. WATANABE, Koichi, Tsuyoshi SAGA, Joe IWANAGA, Yoko TABIRA, Moriyoshi NAKAMURA, Koh-ichi YAMAKI. Department of Anatomy Kurume University School of Medicine, Kurume, Fukuoka, 830-0011, Japan.
- 047 The anatomy of the cervical fascia of the spaces of the neck and their clinical significance. SNOSEK, Michael, and Marios LOUKAS. St. George's University, St. George's, Grenada, West Indies.
- 049\* Medicolegal strategies for iatrogenic spinal accessory nerve injury after prior surgery: An anatomic based approach. CESMEBASI, Alper<sup>1,2</sup>, and Robert J SPINNER<sup>1</sup>. <sup>1</sup>Department of Neurologic Surgery, Mayo Clinic, Rochester, MN 55905; <sup>2</sup>Department of Anatomical Sciences, St George's University, Grenada, West Indies.
- 051\* A head above the rest: An introduction to student plastination in medical gross anatomy. SCHULTZ, Pamela E, Anthony WHITLOW, Holbert HODGES, Stanley ILIFF, and Donna HERMEY. LMU-DCOM, Harrogate, TN 35572, USA.
- 053\* Characterization of the clavicular deltoid tubercle by gender for use as a palpable landmark. RONECKER, Julie C., Brandon M. GEOSLING, and Anthony B. OLINGER. Department of Anatomy, Kansas City University of Medicine and Biosciences, Kansas City, MO 64106, USA.
- 055\* Secondary pathologies of clavicle fractures: length discrepancies and osteoarthritic Changes. COLVIN, Lacey D., Nicholas C. ELWERT, and Natalie R. SHIRLEY. Anatomy Department, Lincoln Memorial University-DeBusk College of Osteopathic Medicine, Harrogate, TN 37752, USA.
- 057 The correlation between acromion types and subacromial space dimensions among Egyptians. YASSA Hanan D.<sup>1</sup> and Maha A.E. WAHED<sup>2</sup>. <sup>1</sup>Anatomy and Embryology Department, Faculty of Medicine, Beni Suef University, Beni Suef, 62511, Egypt; <sup>2</sup>Anatomy and Embryology Department, Faculty of Medicine, Fayoum University, Fayoum, 63514, Egypt.
- 059 Analysis of rotator cuff muscle attachments in the late cocking and follow through phases of baseball pitching on cadaveric specimens. AVONDET, McKay R.<sup>1</sup>, Tanner GRAY<sup>1</sup>, Adam JORGENSEN<sup>1</sup>, and Jonathan J. WISCO<sup>1,2</sup>. <sup>1</sup>Brigham Young University, Provo UT 84602, USA; <sup>2</sup>University of Utah School of Medicine, Salt Lake City, UT 84132, USA.

*continued on next page*



# Poster Listings

## Poster Session 2 – Limbs

Thursday, June 11 10:45 AM – 12:00 PM

(Set up time: Wednesday, June 10 from 8:30 AM until 10:30 AM; Take down time: Thursday, June 11 from 1:00 PM until 2:00 PM)

*\*Denotes abstract will be published in Clinical Anatomy if poster is presented as planned.*

### Poster #Abstract Title/Authors

- 002\* From The Novice To The Experienced Ultrasound User: 7D imaging Is Your Personal Tutor. KO, Jong Bum<sup>1</sup>, Rohit SACHDEVA<sup>2</sup>, David COLLINS<sup>3</sup>, Soo Y. KIM<sup>2</sup>. <sup>1</sup>College of Kinesiology, University of Saskatchewan, Saskatoon, SK S7N 5B2, Canada; <sup>2</sup>School of Physical Therapy, University of Saskatchewan, Saskatoon, SK S7S 0W3, Canada; <sup>3</sup>Faculty of Physical Education and Recreation, University of Alberta, Edmonton, AB T6G 2H9, Canada.
- 004\* Changes in the architecture of supraspinatus following exercise training. SACHDEVA, Rohit<sup>1</sup>, Jonathan FARTHING<sup>2</sup>, Soo Y. KIM<sup>1</sup>. <sup>1</sup>School of Physical Therapy, University of Saskatchewan, Saskatoon, SK S7S 0W3, Canada; <sup>2</sup>College of Kinesiology, University of Saskatchewan, Saskatoon, SK S7N 5B2, Canada.
- 006 A novel bilateral branching pattern of the axillary artery and its clinical implications. GIEFER, Kristen Y., Kyle J. BUSCH, Ashley M. OLSON, Anthony B. OLINGER. Department of Anatomy, Kansas City University of Medicine and Biosciences, Kansas City, MO 64106, USA.
- 008 Quantitative Analysis of Aberrant Forearm Muscle with Possible Flexor Function. LEWIS, C.C.<sup>1</sup>, K. TUFTS<sup>2</sup>, Z. LI<sup>3</sup>, A. AGUR<sup>3</sup>. <sup>1</sup>Samuel Merritt University, Oakland, CA., Department of Basic Sciences; <sup>2</sup>Samuel Merritt University, Oakland, CA., Program of Occupational Therapy; <sup>3</sup>University of Toronto, Toronto, Canada. Division of Anatomy, <sup>2</sup>Division of Anatomy, Department of Surgery, University of Toronto, Toronto, ON M5S 1A8, Canada.
- 010\* Intramuscular architecture of the bellies of flexor digitorum superficialis: a 3D modelling study. JOHNSTON, Mai-Lan, Ellis C. KELLY, Zhi LI, Joshua ATKINSON, and Anne M.R. AGUR. Division of Anatomy, Department of Surgery, University of Toronto, Toronto, ON M5S 1A8, Canada.
- 012\* Prevalence of the persistent median artery: an ultrasound study. KOSALKA, Robert<sup>1</sup>, Zhe Shun J. LI<sup>1</sup>, Chen-En HSIEH<sup>1</sup>, Jason LATSKY<sup>1</sup>, Khoi P. DANG-HO<sup>1</sup>, Sean LEVY<sup>1</sup>, Sara SULAIMAN<sup>2</sup> and James COEY<sup>3</sup>. <sup>1</sup>St. George's International School of Medicine Keith B. Taylor Global Scholars Program with Northumbria University, UK; <sup>2</sup>Department of Applied Sciences, Faculty of Health & Life Sciences, Northumbria University, UK; <sup>3</sup>Department of Anatomy, St. George's University School of Medicine, Grenada, West Indies.
- 014\* High originating radial artery: anatomical study through the use of ultrasound. EBOT Derrick<sup>1</sup>, Haider HILAL<sup>1</sup>, James COEY<sup>1</sup>, and Sara SULAIMAN<sup>2</sup>. <sup>1</sup>Department of Anatomy, St. George's International School of Medicine; Drill Hall, Faculty of Health and Life Sciences; Northumbria University, Newcastle upon Tyne, NE1 8ST, UK; <sup>2</sup>Department of Applied Sciences, Faculty of Health & Life Sciences, Northumbria University, UK.
- 016 Guyon's Canal: An anatomical study of ulnar nerve and artery by the use of ultrasound. SOOKNANAN, Naveen, Nadia SOLOMON, Prerana RODRIGUES, Gillian RICHMOND, Sara SULAIMAN<sup>2</sup> and James COEY<sup>1</sup>. <sup>1</sup>Department of Anatomy, St. George's International School of Medicine; Drill Hall, Faculty of Health and Life Sciences; Northumbria University, Newcastle upon Tyne, NE1 8ST, UK; <sup>2</sup>Department of Applied Sciences, Faculty of Health & Life Sciences, Northumbria University, UK.

*continued on next page*

## Poster Session 2 – Limbs continued

- 018\* Quantification of morphological variations of male and female carpal bones using spherical extent functions. SEMECHKO, Anton<sup>1</sup>, Anne M.R. AGUR<sup>1</sup>, Azam KHAN<sup>2</sup>, and Jeremy P.M. MOGK<sup>2</sup>. <sup>1</sup>Division of Anatomy, Department of Surgery, University of Toronto, Toronto, ON M5S 1A8, Canada; <sup>2</sup>Autodesk Research, Toronto, ON M5A 1J7, Canada.
- 020\* 3D printing of scaphoid types improves visualisation of structural variability. FOGG, Quentin A., Michelle R. QUAYLE, Justin W. Adams and Paul G. McMENAMIN. Centre for Human Anatomy Education, Monash University, Melbourne, Australia 3800.
- 022\* Anatomic study of the triangular fibrocartilage disc of the wrist with surgical relevance. DOMINGUEZ, Juan C<sup>1</sup>, Tatiana NDJATOU<sup>1</sup>, Mika HIRANO<sup>2</sup>, Djavlon A. KHAKIMOV<sup>2</sup>, Alisha J POONJA<sup>2</sup>, R. Shane TUBBS<sup>3,4</sup>, Marios LOUKAS<sup>4</sup>, Piotr B. KOZLOWSKI<sup>5</sup>, Anthony C. DILANDRO<sup>6</sup>, and Anthony V. D'ANTONI<sup>7</sup>. <sup>1</sup>Student at The Sophie Davis School of Biomedical Education, The City College of New York, CUNY, New York, NY 10031, USA; <sup>2</sup>Student at New York College of Podiatric Medicine, New York, NY 10035, USA; <sup>3</sup>Pediatric Neurosurgery, Children's of Alabama, Birmingham, AL 35233, USA; <sup>4</sup>Department of Anatomical Sciences, St. George's University, Grenada; <sup>5</sup>NEUROMEDLAB, Staten Island, NY 10314, USA; <sup>6</sup>Division of Pre-clinical Sciences, New York College of Podiatric Medicine, New York, NY 10035, USA; <sup>7</sup>Department of Pathobiology, The Sophie Davis School of Biomedical Education, The City College of New York, CUNY, New York, NY 10031, USA.
- 024\* Quantitative analysis of triquetrum-hamate entheses. AL SAFFAR<sup>1</sup>, Radi A. and Quentin A. FOGG<sup>1,2</sup>. <sup>1</sup>Laboratory of Human Anatomy, School of Life Sciences, University of Glasgow, Glasgow, G128QQ, UK; <sup>2</sup>Centre for Human Anatomy Education, Monash University, Melbourne, Australia 3800.
- 026\* Morphological and statistical descriptions of the trapezium and 1st metacarpal bones. AL HARBI<sup>1</sup>, Yasser. A and Quentin A. FOGG<sup>1,2</sup>. <sup>1</sup>Laboratory of Human Anatomy, School of Life Sciences, University of Glasgow, Glasgow, G128QQ, UK; <sup>2</sup>Centre for Human Anatomy Education, Monash University, Melbourne, Australia 3800.
- 028\* Size of gluteus maximus and psoas major muscles varies with multifidus size in a cadaver Population. AMABILE, Amy H. and John H. Bolte, IV. Division of Anatomy, School of Health and Rehabilitation Sciences, College of Medicine, The Ohio State University, Columbus, OH 43210.
- 030\* The effects of total hip arthroplasty on femur length and enthesopathy. VASS, Caleb A., Samuel ANTHONY, Natalie R. SHIRLEY. Anatomy Department, Lincoln Memorial University-DeBusk College of Osteopathic Medicine, Harrogate, TN, 37752, USA.
- 032\* Is ultrasound a valid and reliable method of measuring hip abductor volume in cadavers? WOODLEY, Stephanie. J, Natasha A.M.S. FLACK, Jill C. MUIRHEAD, and Samuel S. HAYSOM. Department of Anatomy, University of Otago, New Zealand.
- 034\* Immunohistochemical fiber typing of the hip abductor muscles. FLACK, Natasha A.M.S., Stephanie J. WOODLEY, and Helen D. NICHOLSON. Department of Anatomy, Otago School of Medical Sciences, University of Otago, Dunedin, New Zealand
- 036\* All or nothing: Investigating the anterolateral ligament of the knee by the use of ultrasound. MCKINNELL<sup>1</sup> Zoe A., Daphnee BEAULIEU<sup>1</sup>, Renee WONG<sup>1</sup>, Sara SULAIMAN<sup>2</sup> & James COEY<sup>3</sup>. <sup>1</sup>St. George's International School of Medicine Keith B. Taylor Global Scholars Program with Northumbria University, UK; <sup>2</sup>Department of Applied Sciences, Faculty of Health & Life Sciences, Northumbria University, UK; <sup>3</sup>Department of Anatomy, St. George's University School of Medicine, Grenada, West Indies.

*continued on next page*

## Poster Session 2 – Limbs continued

- 038      High-speed video capture of anterior cruciate ligament femoral avulsion. GILLESPIE, Michael<sup>1</sup>, Devon SMITH<sup>1</sup>, Randy HURD<sup>2</sup>, and Jonathan J. WISCO<sup>1,3</sup>. <sup>1</sup>Brigham Young University, Provo UT 84602, USA; <sup>2</sup>Incompressible Fluids Lab, Utah State University, Logan, Utah; <sup>3</sup>University of Utah School of Medicine, Salt Lake City, UT 84132, USA.
- 040\*      Architecture of the anterolateral and posteromedial bundles of the posterior cruciate ligament. KHOUSHOO, John. Xiao WANG, Zhi LI, Shannon L. ROBERTS. Adarsh RAO, Anne M.R. AGUR. Division of Anatomy, Department of Surgery, University of Toronto, Toronto, ON M5S 1A8, Canada.
- 042\*      The width and thickness of the menisci of knee joint in South Indian cadavers. VIRUPAKSHAMURTHY, Murlimanju B. Department of Anatomy, Kasturba Medical College, Mangalore-575004, Manipal University, Manipal, Karnataka, India.
- 044      Ultrasound assessment of patellar tendon length in athletes & non-athletes. ROMANI Michael<sup>1</sup>, Georgios MIHALOPULOS<sup>1</sup>, Andrew SHLIMUN<sup>1</sup>, Jainesh PATEL<sup>1</sup>, Michael TOMANI<sup>1</sup>, Ryan TOEWS, Maximilian SOLOW<sup>1</sup>, Sara SULAIMAN<sup>2</sup> and James COEY<sup>3</sup>. <sup>1</sup>St. George's International School of Medicine Keith B. Taylor Global Scholars Program with Northumbria University, UK; <sup>2</sup>Department of Applied Sciences, Faculty of Health & Life Sciences, Northumbria University, UK; <sup>3</sup>Department of Anatomy, St. George's University School of Medicine, Grenada, West Indies.
- 046\*      Diagnostic implications of a popliteal cyst in physical therapy education. RUTLAND Marsha D., Jesse RAWLINGS, Rebecca LONEY, Kaylea AULT, and Kate BRUMLEY. Hardin-Simmons University Physical Therapy Department. Abilene, TX 79698, USA.
- 048      The utility of diagnostic and interventional ultrasound in identifying common fibular (peroneal) neuropathy secondary to fabellae. CESMEBASI, Alper<sup>1,2</sup>, Robert J SPINNER<sup>1</sup>, Jay SMITH<sup>1</sup>, Stephen M BANNAR<sup>3</sup>, and Jonathan T FINNOFF<sup>3</sup>. <sup>1</sup>Mayo Clinic, Rochester, MN 55905, USA; <sup>2</sup>St George's University, Grenada, West Indies; <sup>3</sup>Tahoe Orthopedics and Sports Medicine, South Lake Tahoe, CA 96150, USA.
- 050\*      Proximal peroneus brevis muscle insertion and the prevalence of split tendons: a cadaveric study. HOUSLEY, Stephen N.<sup>1</sup>, James E. LEWIS<sup>2</sup>, Deon L. THOMPSON<sup>1</sup>, and Gordon WARREN<sup>1</sup>. <sup>1</sup>Department of Physical Therapy, Georgia State University, Atlanta, GA 30302, USA; <sup>2</sup>Department of Physical Therapy, Brenau University, Gainesville, Georgia 30501, USA.
- 054\*      Biomechanical causes and structural changes associated with hallux valgus: A literature review. VIENNEAU, Maxine D.<sup>1</sup>, Valera CASTANOV<sup>1</sup>, Diane TYCZYNSKI<sup>2</sup>, and Anne M.R. AGUR<sup>1</sup>. <sup>1</sup>Division of Anatomy, Department of Surgery, University of Toronto, Toronto, ON M5S 1A8, Canada; <sup>2</sup>The Michener Institute for Applied Health Sciences, Toronto, ON M5T 1V4, Canada.
- 056\*      Anatomic study of interosseous talocalcaneal and cervical ligaments of foot with surgical relevance. KHAKIMOV, Djavlon A.<sup>1</sup>, Mika HIRANO<sup>1</sup>, Alisha J. POONJA<sup>1</sup>, R. Shane TUBBS<sup>2,3</sup>, Marios LOUKAS<sup>3</sup>, Piotr B. KOZLOWSKI<sup>4</sup>, Khurram H. KHAN<sup>5</sup>, Anthony C. DILANDRO<sup>6</sup>, and Anthony V. D'ANTONI<sup>7</sup>. <sup>1</sup>Student at New York College of Podiatric Medicine; <sup>2</sup>Pediatric Neurosurgery, Children's of Alabama; <sup>3</sup>Department of Anatomical Sciences; <sup>4</sup>NEUROMEDLAB; <sup>5</sup>VA Connecticut Healthcare System; <sup>6</sup>Division of Pre-clinical Sciences, New York College of Podiatric Medicine; <sup>7</sup>Department of Pathobiology, The City College of New York, USA.

## Poster Session 2 – Limbs continued

- 058\* Osteophytic lippling in response to BMI in the tibio-femoral and tibio-talar joints. SACHDEVA, Shireen, Sunay PATEL, and Natalie R. SHIRLEY. Anatomy Department, Lincoln Memorial University-DeBusk College of Osteopathic Medicine, Harrogate, TN 37752, USA.
- 060\* A study of obesity: the relationship between BMI and heel spurs. KUIK, Joyce, and Natalie R. SHIRLEY. Department of Anatomy, Lincoln Memorial University-DeBusk College of Osteopathic Medicine, Harrogate, TN 37752, USA.

## Poster Listings

### Poster Session 3 – Torso

**Thursday, June 11 3:30 – 4:45 PM**

(Set up time: Thursday, June 11 from 2:00 PM until 3:00 PM; Take down time: Friday, June 12 from 1:00 PM until 3:00 PM)

\*Denotes abstract will be published in *Clinical Anatomy* if poster is presented as planned.

#### Poster #Abstract Title/Authors

- 061\* An anatomical study of Kartagener's syndrome. ARMS, Lauren E.<sup>1</sup>, David L. MEALIEA<sup>1</sup>, Darlene E. PETERSON<sup>1</sup>, Allison L. CIOLINO<sup>1</sup>, Sarah J. GREENE<sup>1,2</sup>. <sup>1</sup>University of Vermont College of Medicine, Burlington, VT 05456; <sup>2</sup>Department of Pathology and Anatomy, Morehouse School of Medicine, Atlanta, GA, 30314.
- 063\* Anatomical observation of the dorsal scapular nerve- A series of cadaver study. NGUYEN, Vuvi H.<sup>1</sup>, Howe LIU<sup>2</sup>, Armando ROSALES<sup>1</sup>, and Rustin REEVES<sup>1</sup>. <sup>1</sup>Department of Integrative Physiology and Anatomy; <sup>2</sup>Department of Physical Therapy, University of North Texas Health Science Center, Fort Worth, TX 76107, USA.
- 065\* Reliability and validity of fiber bundle length measurements of the pectoralis major: in vivo ultrasound imaging. KO, Jong Bum<sup>1</sup>, Rohit SACHDEVA<sup>2</sup>, Gyung won SON<sup>3</sup>, and Soo Y. KIM<sup>2</sup>. <sup>1</sup>College of Kinesiology, University of Saskatchewan, Saskatoon, SK S7N 5B2, Canada; <sup>2</sup>School of Physical Therapy, University of Saskatchewan, Saskatoon, SK S7S 0W3, Canada; <sup>3</sup>College of Medicine, University of Saskatchewan, Saskatoon, SK S7N 5E5, Canada.
- 067\* Supernumerary muscles of the pectoral and axillary regions: A systematic review and meta-analysis. CASIER, Craig B., Benjamin TURNER, R. Shane TUBBS, Marios LOUKAS. Department of Anatomical Sciences, St. George's University, Grenada, West Indies.
- 069\* Examination of the Intercostal Nerve and Branch Points: A Cadaveric Study. SOLOMON, Danielle, Penelope BURIKAS, Ian BOWERS, and Anthony OLINGER. Kansas City University of Medicine and Biosciences. Kansas City, MO, 64118, USA.
- 071\* Surface anatomy of the central venous structures in neonates. IWAN, Tom M.<sup>1</sup>, Michael SUNDERLAND<sup>1</sup>, James HAMIL<sup>2</sup>, Kiarash TAGHAVI<sup>3</sup>, and S. Ali MIRJALILI<sup>1</sup>. <sup>1</sup>Department of Anatomy with Radiology, Faculty of Medical and Health Sciences, University of Auckland, Auckland, New Zealand; <sup>2</sup>Department of Paediatric Surgery, Starship Hospital, Auckland, New Zealand; <sup>3</sup>Department of Paediatric Surgery, Royal Children's Hospital, Brisbane, QLD, Australia.
- 073 Relating aortic annulus to the femoral and subclavian arteries. OVEYSSI, Justin O., Ravi PIRYANI, and Anthony B. OLINGER. Department of Anatomy, Kansas City University of Medicine and Biosciences, Kansas City, MO, 64106, USA.

*continued on next page*

### Poster Session 3 – Torso continued

- 075      MRI reconstruction and 3D print of coronary vessels to aid in coronary bypass preoperative teaching and preparation. JORGENSEN, Adam<sup>1</sup>, Brett GARDINER<sup>1</sup>, Alistair HILTON<sup>1</sup>, H. Wayne LAMBERT<sup>2</sup>, and Jonathan J. WISCO<sup>1,3</sup>. <sup>1</sup>Brigham Young University, Provo, UT 84602, USA; <sup>2</sup>West Virginia University School of Medicine, Morgantown, WV 26505, USA; <sup>3</sup>University of Utah School of Medicine, Salt Lake City, UT 84132, USA.
- 077\*      Characterization of the coronary arteries to improve aortic replacement surgery. PFEIFFER, Jacob F. Clive C. PERSAUD Devon S. BOYDSTUN Amanda L. OSTERLOH Kristin COLYER Ashley OLSON Anthony B. OLINGER Kansas City University of Medicine and Biosciences, Department of Anatomy, Kansas City MO, 64106, USA.
- 079\*      Anatomical data can aid in clinical decisions regarding 'left atrial appendage closure devices'. OSTERLOH, Amanda, Stanley WIGGINS, and Anthony OLINGER. Kansas City University of Medicine and Biosciences, Kansas City, Missouri, 64106, USA. Mercy Clinic Cardiology & Clinical Cardiac Electrophysiology, Springfield, Missouri, USA.
- 081\*      Characterizing the superior vena cava to confirm central venous catheter location on Radiographs. KAUFFMAN, Travis H, Amanda L OSTERLOH, Anthony B OLINGER. Department of Anatomy, Kansas City University of Medicine and Biosciences, Kansas City, MO 64105, USA.
- 083      Revisiting the anatomy of the superior surface of the respiratory diaphragm. WEINHAUS, Anthony J. Department of Integrative Biology & Physiology, University of Minnesota Medical School, Minneapolis, MN 55455, USA
- 085\*      Lymphadenopathy investigation: an interdisciplinary approach to studying chronic lymphocytic leukemia. HUA, Nathan, Velma A RAWLINS, MD. Peter A. BELLOT, MD. Riad K BANKUSLI, Kunwar P KAUR, Astrid I CARRIÓN RODRÍGUEZ, Meghan E GUTHRIE, Sanjay SINGH, Aisha S ATHAR, Amber N USRY. Ross University School of Medicine, 2300 SW 145th Avenue, Suite 200, Miramar, FL 33027, USA.
- 087      Ultra-structural morphology of long-term cultivated white adipose tissue-derived stem Cells. MIKO<sup>1</sup>, Michal, Ivan VARGA<sup>1</sup>, Stefan POLAK<sup>1</sup>, Lenka ORAVCOVA<sup>1</sup>, Lubos DANISOVIC<sup>2</sup>. <sup>1</sup>Institute of Histology and Embryology; <sup>2</sup>Institute of Medical Biology, Genetics and Clinical Genetics, Faculty of Medicine, Comenius University in Bratislava, Slovakia.
- 089      Variations in the distances from the major to minor duodenal papilla and pylorus. BEE, Mary, Ami PATEL, Sheila PUTNAM, and Taylor MARSHALL. University of Detroit Mercy, Detroit, MI 48223.
- 091      Developing a surface anatomy landmark ratio to identify kidneys in cadavers with finger Ultrasound. WRIGHT Jonathon<sup>1</sup> and Brion BENNINGER<sup>1,2</sup>. <sup>1</sup>Medical Anatomy Center, Departments of Medical Anatomical Sciences, Neuromuscular Medicine, Family Practice, Western University of Health Sciences, COMP-Northwest, Lebanon, OR. USA; <sup>2</sup>Orthopaedic and General Surgery Residency faculty, Samaritan Health Services, Corvallis, OR. USA.
- 093      Characterization of the Inferior Vena Cava to improve IVC filter placement and longevity. OLSON, Ashley M., Kristen Y. GIEFER, Kenna B SCHNARR, and Anthony B. OLINGER. Department of Anatomy, Kansas City University of Medicine and Biosciences, Kansas City, MO 64106, USA.
- 095\*      Transramic obturator artery: a normal human variant in Dutch and American cadavers I. NWOSU Ijoma A.<sup>1</sup>, Andrew J. MILLER<sup>1</sup>, Luke CARLSON<sup>1</sup>, Frank SCALI<sup>1</sup>, Dennis J. WARFIELD JR.<sup>1</sup>, Meghan TORNATORE<sup>1</sup>, Jose PEREZ-GUMA<sup>1</sup>, Lance G. NASH<sup>1</sup>. <sup>1</sup>Department of Anatomy, embryology and histology, American University of the Caribbean (AUC), Cupecoy, St. Maarten, Dutch West Indies.

*continued on next page*



### Poster Session 3 – Torso continued

- 097\* Study of the differences in the level of the conus medullaris in four different age groups. VAN SCHOOR Albert-Neels<sup>1</sup>, Marius C BOSMAN<sup>1</sup>, and Adrian T BOSENBORG<sup>2</sup>. <sup>1</sup>Department of Anatomy, School of Medicine, Faculty of Health Sciences, University of Pretoria, Pretoria, South Africa; <sup>2</sup>Department of Anesthesiology and Pain Management, University of Washington and Seattle Children's Hospital, Seattle, USA.
- 099\* Should we abandon landmark-based techniques for caudal anesthesia in neonates and infants? MIRJALILI, S. Ali.<sup>1</sup>, Kiarash TAGHAVI<sup>2</sup>, Geoff FRAWLEY<sup>3</sup>, and Susan CRAW<sup>4</sup>. <sup>1</sup>Department of Anatomy with Radiology, Faculty of Medical and Health Sciences, University of Auckland, Auckland, New Zealand; <sup>2</sup>Department of Paediatric Surgery, Royal Children's Hospital, Brisbane, Qld, Australia; <sup>3</sup>Department of Paediatric Surgery, Royal Children's Hospital, Melbourne, Vic, Australia; <sup>4</sup>Department of Radiology, Dunedin Public Hospital, Dunedin, New Zealand.
- 101\* Viewing the ganglion impar in vivo utilizing ultrasound: A feasibility study and literature review. RICHMOND, S. R. Gillian<sup>1</sup>, Peter BOSHARA<sup>1</sup>, Gaston HABIB<sup>1</sup>, Grace NASRI<sup>1</sup>, Prerana RODRIGUES<sup>1</sup>, Nadia SOLOMON<sup>1</sup>, Naveen SOOKNANAN<sup>1</sup>, James COEY<sup>1</sup> and Sara SULAIMAN<sup>2</sup>. <sup>1</sup>Department of Anatomy, St. George's International School of Medicine; Drill Hall, Faculty of Health and Life Sciences; Northumbria University, Newcastle upon Tyne, NE1 8ST, UK; <sup>2</sup>Department of Applied Sciences, Faculty of Health & Life Sciences, Northumbria University, UK.
- 103\* The suspensory ligament of the ovary versus the ovarian ligament; a semantic conundrum. OTOBO, M. Tarimobo and TARIMOBO-OTOBO Rugina. Department of Anatomy, Niger Delta University, Wilberforce Island, Bayelsa State, Nigeria.
- 105\* Localization of stem cell and differentiation markers in prostate cancer and benign prostatic hyperplasia. RODLER, Daniela, and Fred SINOWATZ. Institute of Anatomy, Histology and Embryology, Department of Veterinary Sciences, University of Munich, D-80539 Munich, Germany.
- 107 Percuision: DirectVision camera guided urinary catheterization training during medical students anatomy lab. NATKA, Vitaly<sup>1</sup>, David HORN<sup>1</sup> and Brion BENNINGER<sup>1,2</sup>. <sup>1</sup>Medical Anatomy Center, Departments of Medical Anatomical Sciences, Neuromuscular Medicine, Family Practice, Western University of Health Sciences, COMP-Northwest, Lebanon, OR. USA; <sup>2</sup>Orthopaedic and General Surgery residency faculty, Samaritan Health Services, Corvallis, OR. USA.
- 109 Assessing the relationship between levator ani nerve length and pelvic floor dysfunction. GIEFER, Kristen Y., Barth W. WRIGHT, and Ashley M. OLSON. Department of Anatomy, Kansas City University of Medicine and Biosciences, Kansas City, MO 64106, USA.
- 111\* Should hemorrhoids be considered a complication of portal hypertension? PALMER, Laura, Thomas R. GEST, and DolgorBAATAR. Paul L. Foster School of Medicine, TTUHSC, El Paso, TX, USA.
- 113 Different types of placental trophoblasts: New terminology and clinical significance. VARGA, Ivan<sup>1</sup>, Zuzana CIERNA<sup>2</sup>, Ludovit DANIHEL<sup>2</sup>, and Michal MIKO<sup>1</sup>. <sup>1</sup>Institute of Histology & Embryology; <sup>2</sup>Institute of Pathology, Faculty of Medicine, Comenius University in Bratislava, Slovakia.
- 115 The clinical significance of interstitial Cajal-like cells and their role in tissue regeneration. VARGA, Ivan, Michal MIKO, Stefan POLAK and Lubos DANISOVIC. Faculty of Medicine, Comenius University in Bratislava, Slovakia.

continued on next page

## Poster Session 3 – Torso continued

- 117      Art and anatomy, two professions, same story. ABRAHAMS, Peter<sup>1,2</sup>, Letsogile NGWALONGWALOT, and Justine SCHOB<sup>3</sup>. <sup>1</sup>St Georges University school of medicine, WI; <sup>2</sup>Warwick University Medical school, Coventry, West Midlands CV4 7AL, United Kingdom; <sup>3</sup>UPMC Hamot, 201 State Street, Erie, PA 16550.
- 119\*      Art and anatomy, Vitruvian man- Two sexes. ABBATIELLO, Thomas<sup>1</sup>, Malcolm ANTOINE<sup>1</sup>, Peter ABRAHAMS<sup>1,2</sup>. <sup>1</sup>St Georges University school of medicine, WI, USA; <sup>2</sup>Warwick University Medical school, Coventry, West Midlands CV4 7AL, United Kingdom.

## Poster Listings

### Poster Session 4 – Anatomical Services and Education

Friday, June 12 9:15 – 10:30 AM

(Set up time: Thursday, June 11 from 2:00 PM until 3:00 PM; Take down time: Friday, June 12 from 1:00 PM until 3:00 PM)

\*Denotes abstract will be published in *Clinical Anatomy* if poster is presented as planned.

#### Poster #Abstract Title/Authors

- 062      A rare case of acute formaldehyde allergy in the dissection room. BARASH Alon, NISSIM Hila, KARASIK David. Faculty of Medicine in the Galilee, Bar Ilan University, Safed, Israel.
- 064      Rē•Līf-ing: Exploring a Life in Death. ENTEZAMPOUR, Mo, Paul LYONS, Kendrick DAVIS, and Chris MILLER. University of California Riverside School of Medicine, Riverside, CA 92521.
- 066      Veterans memorial services for donors. PIPE, Kimberly H., Aron R. DAVIS. University of California Davis Body Donation Program, Sacramento, CA 95820, USA.
- 068\*      Using a database to track the demographics of preregistered donors to predict future trends in whole body donations. FISHER, Dean R.<sup>1</sup>, Nicki HARRIS<sup>1</sup>, Travis G. SIEMS<sup>1</sup>, Alex RODRIGUEZ<sup>1</sup> and Parviz KHOSHBAKHTAI<sup>2</sup>. <sup>1</sup>University of California Los Angeles, Los Angeles, CA 90095 USA; <sup>2</sup>University of California Irvine, Irvine, CA 35233, USA.
- 070\*      Advantages of using a gravity embalming method: steps to reduce formaldehyde exposure and to increase employee productivity. BARTON, Scott T.<sup>1</sup>, Mark D. GARY<sup>1</sup>, Maria C. SAVOIA<sup>2</sup>. <sup>1</sup>Anatomical Services, Division of Medical Education; <sup>2</sup>Division of Medical Education, School of Medicine, University of California, San Diego, La Jolla, CA 92093, USA.
- 072      A look back over the first 9 years of our body donation program: What we wish we'd known! McANDREW, Darryl J. Graduate School of Medicine, University of Wollongong, Wollongong NSW 2522 Australia.
- 074\*      The meaning of a convocation of thanks: Beyond the students. GREENE, Sarah J.<sup>1,2</sup>, Amanda BECHTEL<sup>1</sup>, Lee ROSEN<sup>1</sup>. <sup>1</sup>University of Vermont College of Medicine, Burlington, VT 05401. <sup>2</sup>Department of Pathology and Anatomy, Morehouse School of Medicine, Atlanta, GA 30310.
- 076\*      Comparing cadaver preparations for maximum imaging quality used for anatomy teaching courses, CME's and research. CARMICHAEL<sup>1</sup>, Steven, Brion BENNINGER<sup>1,2</sup>, and Tom Schlundt<sup>1</sup>. <sup>1</sup>Willard Body Donation Program, Medical Anatomy Center, Departments of Medical Anatomical Sciences, Neuromuscular Medicine, Family Practice, Western University of Health Sciences, COM- Northwest, Lebanon, OR. USA. <sup>2</sup>Orthopaedic and General Surgery residency faculty, Samaritan Health Services, Corvallis, OR. USA.


continued on next page

## Poster Session 4 – Anatomical Services and Education continued

- 078\* Whole-body donation willingness: associations with cadaver-based anatomy and blood/plasma donations. SEVERNS, Danielle M., and Alla G. PETERS. Department of Biology, Missouri Southern State University, Joplin, MO 64801, USA.
- 080 A step towards change: The virtual anatomy lab. CRUTCHFIELD, Jay M. and John H. OLSON, Department of Anatomy, A.T. Still University School of Osteopathic Medicine, Mesa, AZ 85206.
- 082\* Advanced dissections and education skills: Training teaching assistants. HEWETSON, Anthony, Vaughan LEE, Texas Tech University, Department of Medical Education, Lubbock, TX 79430, USA.
- 084\* Benefits of offering a clinical anatomy review course to health care professionals. RUTLAND, Marsha D; Janelle K. O'CONNELL. Hardin-Simmons University, Department of Physical Therapy, Abilene, TX. 79698, USA.
- 086\* A near peer-driven dissection selective: Primer to a medical school anatomy course. CANTWELL, Sean R., George F. BONADURER III, Wojciech PAWLINA, and Nirusha LACHMAN\*. Department of Anatomy, College of Medicine, Mayo Clinic, Rochester, MN 55905, USA.
- 088 Residents: Career mentors for medical students. BISNATH, Carol<sup>1</sup>, Leslie NICKELL<sup>1</sup>, and Anne AGUR<sup>2</sup>. <sup>1</sup>Office of Health Professions, Student Affairs, Faculty of Medicine, University of Toronto, Toronto, ON M5S 1A8, Canada; <sup>2</sup>Division of Anatomy, Department of Surgery, University of Toronto, Toronto, ON M5S 1A8, Canada.
- 090 Instrument organization. MUELLER, Dean A., and Jeannette R. HINKLE. University of Michigan Anatomical Donations Program, Ann Arbor, MI 48109, USA.
- 092 Converting a computerized neuroanatomical tool to a HTML5 format. SEVERSON, Arlen R. Department of Biomedical Sciences, University of Minnesota Medical School, Duluth Campus, Duluth, MN 55812, USA.
- 094 Anatomic knowledge increases after participation in ASSET training. PUGH, Kristy R., Evan M. GAROFALO, Brandon W. BONDS, and Colin F. MACKENZIE. Shock Trauma & Anesthesiology Research Center & Department of Anatomy and Neurobiology. University of Maryland School of Medicine, Baltimore, MD 21201, USA.
- 096 Evaluating the efficacy of a video dissection guide tailored to the Louisiana State University Health Sciences Center gross anatomy curricula. CAMPEAU, Lisa M. and Jason C. MUSSELL. Louisiana State University Health Sciences Center, New Orleans, LA 70112.
- 098 Dissecting out the variables of an interprofessional near peer anatomy teaching experience. NOEL Geoffroy PJC <sup>1</sup>, Jonathan HUDON <sup>1</sup> and Sandie LAROUCHE<sup>2</sup>. <sup>1</sup>Division of Anatomical Sciences, Department of Anatomy and Cell Biology, Faculty of Medicine; <sup>2</sup>Ingram School of Nursing, McGill University, Montreal, QC, H3A 0C7, Canada.
- 100 Neuroanatomy education: evaluating methods of delivery on student opinions and academic performance. BERGEN, Hugo T., Alison M. LONGO, and Jason PEELER. University of Manitoba, Department of Human Anatomy & Cell Science, College of Medicine, Faculty of Health Sciences, Winnipeg, MB, Canada.

## Poster Session 4 – Anatomical Services and Education continued

- 102\* Survey of body donor personal information provided to students attending medical school in the United States. GERWER, Johanna, Thomas GEST. Department of Medical Education, Texas Tech University Health Sciences Center Paul L. Foster School of Medicine, El Paso, Texas 79905, USA.
- 104\* Presenting mechanisms of anatomical variations utilizing 3D animations and the Aurasma mobile app. HONG<sup>1</sup>, Trudy M.<sup>1</sup>, Kaori TAMURA<sup>2</sup>, Georg C. BEZARD<sup>1</sup>, Ali Cem KUCUKDAGLI<sup>1</sup>, Beth K. LOZANOFF<sup>1</sup>, Steven LaBRASH<sup>1</sup>, Selcuk TUNALI<sup>1,3</sup>, Scott LOZANOFF<sup>1</sup>. <sup>1</sup>Department of Anatomy, Biochemistry & Physiology, University of Hawaii School of Medicine, USA; <sup>2</sup>Department of Kinesiology and Rehabilitation Science, University of Hawaii at Manoa, USA; <sup>3</sup>Department of Anatomy, TOBB University of Economics and Technology, Ankara, Turkey.
- 106\* Multimodal learning resource: cross-sectional anatomy. RICHTER, Saskia D, Laura C. BOUCHER, Eileen L. KALMAR. Division of Anatomy, The Ohio State University, Columbus, OH, 43210 USA.
- 108\* Muscle fiber direction of the upper trapezius in relation to tender zones of patients with chronic neck pain. HEMANTH, Raksha<sup>1</sup>, Erica A. ERRIGO<sup>1</sup>, Annette PANTALL<sup>1</sup>, Rebecca L. PRATT<sup>1,2</sup>. <sup>1</sup>College of Osteopathic Medicine; <sup>2</sup>Department of Radiology Michigan State University, East Lansing, MI 48824, USA.
- 110\* Methods of using plastinated specimens to enhance learning and retention of anatomical structures. OWENS, Juston, Donna HERMEY, and Stan ILIFF. Lincoln Memorial University – DeBusk College of Osteopathic Medicine, Cumberland Gap, TN 37752, USA.
- 112\* Understanding our students and how they learn: Preferred learning styles of undergraduate gross anatomy students. QUINN, Melissa, M., and Jennifer M. BURGOON. Division of Anatomy, College of Medicine, The Ohio State University, Columbus, Ohio, 43210, USA.
- 114 Musculoskeletal anatomy education: evaluating the influence of different methods of delivery on medical students perception and academic performance. LONGO, Alison M., Hugo BERGEN and Jason PEELER. University of Manitoba, Department of Human Anatomy & Cell Science, College of Medicine, Faculty of Health Sciences, Winnipeg, MB, Canada.
- 116 Timed visual text guide for skill acquisition of the Sectra Visualization Table BARRACK, Daniel<sup>1</sup>, David HORN<sup>1</sup>, Brion BENNINGER<sup>1,2</sup>. <sup>1</sup>Medical Anatomy Center, Departments of Medical Anatomical Sciences, Neuromuscular Medicine, Family Practice, Western University of Health Sciences, COMP-Northwest, Lebanon, OR. USA; <sup>2</sup>Departments of Surgery, Orthopaedics & Rehabilitation, Oregon Health & Science University, Portland, OR. USA.
- 120 Using augmented reality in the form of Google Glass to examine students in the medical anatomy lab RICHARDSON, Matt, Adam BURCH <sup>1</sup> and Brion BENNINGER<sup>1,2</sup>. <sup>1</sup>Medical Anatomy Center, Departments of Medical Anatomical Sciences, Neuromuscular Medicine, Family Practice, Western University of Health Sciences, COMP-Northwest, Lebanon, OR. USA; <sup>2</sup>Orthopaedic and General Surgery residency faculty, Samaritan Health Services, Corvallis, OR. USA.
- 122 Comparing ultrasound images and probes between variable cadaver preparations for health care training KIMBAL, Adam, Bonnie KENYAN <sup>1</sup>, David HORN<sup>1</sup> and Brion BENNINGER <sup>1,2</sup>. <sup>1</sup>Medical Anatomy Center, Departments of Medical Anatomical Sciences, Neuromuscular Medicine, Family Practice, Western University of Health Sciences, COMP-Northwest, Lebanon, OR. USA; <sup>2</sup>Orthopaedic and General Surgery residency faculty, Samaritan Health Services, Corvallis, OR. USA.



# Annual Business Meeting

**Agenda**  
**Friday, June 12, 2015**  
**Green Valley Ranch Resort**  
**Henderson, Nevada**

PO Box 2945  
LaGrange, Ga 30241  
Ph: 706-298-0287

[www.clinical-anatomy.org](http://www.clinical-anatomy.org)

## **CALL TO ORDER: 4:00pm**

Approval of Minutes of 2014 Annual Business Meeting (ABM) and the 2015 ABM Agenda

1. **President's Report** – *Brian MacPherson*
  - a. 2015 Election Results
  - b. 2016 Election
  - c. Presidential Committee Appointments
2. **Treasurer's Report** – Neil Norton on behalf of *Carol Lomneth*
3. **Membership Committee Report** – *Neil Norton*
  - a. Remembrance of Deceased Members – *H. Wayne Lambert*
4. **Journal Committee Report** – *Neil Norton*
  - a. Report of Editor-in-Chief of *Clinical Anatomy* – *R. Shane Tubbs*
5. **Meeting Organization & Program Planning Comm. Report** – *Noelle Granger*
  - a. Report of 2015 Annual Meeting Committee – *David Porta and Sherry Downie*
  - b. Future Meetings:
    - i. AACA Annual Meeting in 2016, Oakland, CA – *Brandi Schmitt & Kim Topp*
    - ii. AACA Annual Meeting in 2017, Minneapolis, MN – *Tony Weinhaus*
6. **Committee Elections\*** – *Brian MacPherson*

a. Election of Members-at-Large for Bylaws:	2 vacancies
b. Financial Affairs Committee:	1 vacancy
c. Nominating Committee:	2 vacancies
7. **Annual AACA Awards** – *Noelle Granger*
  - a. AACA Student Awards
  - b. AACA Anatomical Services Award
8. **Transfer of Leadership** – *Brian MacPherson*
9. **Old Business**
10. **New Business**

## **ADJOURNMENT: 5:00pm**

\* The membership of Special Interest Group (SIG) Committees (Educational Affairs, Career Development, Clinical Anatomical Terminology, and Anatomical Services) elects members at their committee meetings.



**American Association of Clinical Anatomists**  
**Thursday, July 10, 2014**  
**Disney's Yacht & Beach Club Resort**  
**Orlando, Florida**

**Call To Order:** 4:54 p.m.

The President asked for approval of the minutes of the 2013 Annual Business Meeting, which were located on Page 37 of the Annual Meeting Program, the 2014 Annual Business Meeting Agenda, located on Page 36 of the Annual Meeting Program. The minutes and agenda were adopted by general consent at 4:55 p.m.

**1. President's Report** (Brian MacPherson – AACA President):

- The 2014 AACA election results were reported. The AACA membership elected H. Wayne Lambert as Secretary, Philip Fabrizio as Special Councilor – Allied Health, and Lisa Lee and Marios Loukas as Councilors-at-Large.
- For the 2015 election, many important positions will be available to the membership, including President-Elect, Program Secretary, two Councilor-at-Large positions, and the Special Councilor – Anatomical Services. Brian encouraged the attendees to vote in the 2015 AACA Election as the AACA would like to increase the level of membership participation.
- The Composition of the 2014-2015 AACA Committees are as follows:

**Anatomical Services Committee:** Brandi Schmitt (Technical Co-Chair), Todd Hoagland (Academic Co-Chair)

**Presidential Appointees:** Quentin Fogg (2012-2015), Todd Hoagland (2013-2016), Andrew Corson (2014-2017)

**Elected Members-at-Large:** Brion Benninger (2012-2015), Jennifer Mark (2013-2016), Angela McArthur (2014-2017)

**Bylaws Committee:** Len Cleary (Chair)

**Presidential Appointees:** Jennifer Burgoon (2012-2015), Elmus Beale (2012-2015)

**Elected Members-at-Large:** Kurt Gilliland (2014-2015), Catherine "Katie" Mattinson (2014-2015)

**Career Development Committee:** Jon Wisco (Chair)

**Presidential Appointees:** Jon Wisco (2012-2015), Sarah Greene (2013-2016), Anthony "Tony" Olinger (2014-2017)

**Elected Members-at-Large:** Dolgor Baatar (2012-2015), Gilbert Willett (2013-2016), Nirusha Lachman (2014-2017), Alan Detton (2014-2017)

**Clinical Anatomical Terminology Committee:** Sherry Downie (Chair)

**Presidential Appointees:** Sherry Downie (2013-2016), Brad Martin (2013-2016)

**Elected Members-at-Large:** Tom Gest (2012-2015), Rebecca Pratt (2012-2015), Brion Benninger (2012-2015), Anthony "Tony" Olinger (2013-2016), Alan Richards (2014-2017), Ian Whitmore (2014-2017), O. Paul Gobee (2014-2017)

*continued on next page*

**Educational Affairs Committee:** Jennifer Burgoon (Chair)

**Presidential Appointees:** Jennifer Burgoon (2012-2015), Erin Fillmore (2013-2016), April Richardson-Hatcher (2014-2017)

**Elected Members-at-Large:** Ann Poznanski (2012-2015), Lonnie Salkowski (2013-2016), Vaughn Lee (2014-2017)

**Financial Affairs Committee:** Carol Lomneth (Chair – Treasurer - ex officio)

**Presidential Appointees:** Neil Norton (2014-2016), Lisa Lee (2014-2016)

**Elected Member-at-Large (one-year term):** David Porta (2014-2015), Laura Barritt (2014-2015)

**Journal Committee:** Neil Norton (Chair – President-Elect - ex officio)

**BACA President:** Stuart McDonald (2013-2015)

**AACA President:** Brian MacPherson (2013-2015)

**AACA Treasurer:** Carol Lomneth (2013-2015)

**Clinical Anatomy Editor-in-Chief:** Shane Tubbs (2013-2015)

**Publisher's Representative:** Tiffany McKarahan (Wiley Liss – not term limited)

**Membership Committee:** Neil Norton (Chair – President-Elect - ex officio)

**Presidential Appointees:** Samuel Franklin (2013-2015)

**Past President:** Anne Agur (2013-2015)

**Nominating Committee:** Rebecca Lufler (Chair)

**Presidential Appointees:** Rebecca Lufler (2014-2015), David Porta (2014-2015), Todd Hoagland (2014-2015)

**Elected Members-at-Large:** Tom Quinn (2014-2015), Anne Gilroy (2014-2015)

## **2. Treasurer's Report** (Carol Lomneth - AACA Treasurer):

- Carol thanked Neil Norton for his help in making her transition to Treasurer a smooth one. The financial standing of the AACA was reviewed, highlighting how our professional association will benefit from our newly structured membership dues and the renegotiation of the journal contract. While showing the membership the major meeting expenditures, Carol reported the 2013 Denver meeting led to an AACA profit of \$6,438, after \$113,909 in income and \$107,471 in expenses. The postgraduate course at the Denver meeting experienced a loss of \$3,661. Carol listed the royalties derived from the Clinical Anatomy journal as \$66,262 in 2014, which is an increase from the previous year. She also listed Wiley support for the editorial office, including office support = \$25,000, travel budget for Editor-in-Chief to promote the journal = \$10,000, and journal development = \$22,500. Therefore, Wiley support to the editorial office in 2014 was \$57,500. With the new membership dues and journal contract, the AACA is benefitting financially with a balance of \$274,367 on May 14, 2014, which has led to the need to open another AACA bank account. After stating our current balance, Carol did remind the AACA members that many of our meeting expenses for the 2014 Orlando meeting still need to be paid. Carol also listed the costs of our professional management company, ASG, as \$44,362 with an additional \$17,240 in AACA operating expenses in 2014. Finally, Carol listed her future goals as the AACA Treasurer, which included improving communication, creating a chart of accounts, establishing a travel expense policy, increasing the funds for SIG committees to allow for the invitation of outside speakers, and growing savings to support a one year operating budget. At the conclusion of his presentation, Brian thanked Carol for smooth transition to AACA Treasurer.

## **3. Membership Committee Report** (Neil Norton – AACA President-Elect):

- The membership committee report was inserted into the Orlando Meeting Program on pages 47-49, and this report listed the new members that joined the AACA from August 1, 2013 – May 1, 2014, which included 71 regular, 75 associate, 4 affiliate, and 2 senior members.
- Neil mentioned that there will be a new, streamlined membership approval process in place in the coming year, which will make joining the AACA a more efficient process.

## **4. Remembrance of Deceased Members** (H. Wayne Lambert – AACA Secretary):

- Wayne asked the AACA members in attendance for the names of any members who had passed away since the previous annual business meeting. A moment of silence was observed for beloved AACA members, Neal A. Cross and Hunter S. Neal.

*continued on next page*

**5. Journal Committee Report** (Neil Norton – AACA President-Elect):

- Neil, the Chair of the AACA Journal Committee, highlighted some financial numbers involved with our journal, *Clinical Anatomy*. His discussion focused on our new publishing contract with Wiley. Currently, 13% of AACA members receive a print version and 87% receive online access to the journal. He also mentioned a 24% increase in downloads of our journal articles in 2014.
- Neil discussed going to the BACA meeting to work on the joint journal committee, which is composed of AACA and BACA members, the Editor-in-Chief, and Tiffany McKarahan, our Wiley representative.

**6. Journal Report** (Shane Tubbs – *Clinical Anatomy* Editor-in-Chief):

- Shane thanked Neil and the Journal Committee as well as Tiffany McKarahan for their help throughout the past year.
- He introduced his editorial board, showed the types of articles published in the journal, shared the top downloaded articles in the journal for 2012 and 2013, and listed the upcoming special issues.
- New topics of interest for the journal include ethics, formaldehyde, eponyms, prions, imaging.
- What's new in 2014 and beyond? Our journal is now requiring acknowledgements for donors of cadaveric material, IRB verification, listing of authors' conflicts of interests, and changing covers on each journal.
- Shane highlighted the quick turnaround of his editorial board, which enables papers to be published online in a timely manner.
- The journal will send out a survey to the membership to receive feedback.
- Our journal will start allowing CME credits for papers published in our journal.
- Impact factor in 2012 was 1.159 and the IF13 will be out later in July.
- Increase exposure of our journal at the IFAA meeting will see AACA members serve as chairs of four symposia and speakers at 6 symposia.
- *Clinical Anatomy* currently has a 76% rejection rate as the leading journal devoted to clinical anatomy.
- Shane thanked the members of the AACA for their work in reviewing manuscripts and their valued input, which impacts the quality of the *Clinical Anatomy* journal.

**7. Committee Elections** (Brian MacPherson – AACA President):

- Two Members-at-Large for the Bylaws Committee were accepted by acclamation by the membership (Katie Mattison and Kurt Gilliland).
- The Financial Affairs Committee had one member accepted by acclamation (Laura Barritt).
- Two members were voted onto the Nominating Committee (Tom Quinn, Anne Gilroy).

**8. Report of the Program Secretary** (Noelle Granger – AACA Meeting Chair):

- Noelle summarized the work of the MOPP committee and mentioned how the MOPP and Annual Meeting Committee have planned the future annual meetings through the 2019. She encouraged the membership to read the results of the AACA Membership Survey.

**9. Report of the Annual Meeting Chair** (David Porta - 2014 AACA Annual Meeting Chair):

- Instead of giving an oral presentation, David asked the AACA members to read the report of the 2014 AACA Annual Meeting Committee, which is located on Pages 52-53 of the Annual Meeting Program.

**10. Old Business:** None

**11. New Business:** Todd Olson asked the membership to rethink the new AACA logo, and he made the following motion (listed below), which was defeated by a large majority.

MOTION (Olson, Porta): I move AACA's branding process be immediately suspended and all activities and expenditures promulgating "The Torso" cease until the Council electronically surveys the membership's response to the logo and can make a determination as to whether or not its continued use is in the long-term interests of the Association's objectives, membership retention and growth, and its academic image amongst our peer societies. The President is further charged to name a three to five member ad hoc committee to develop and disseminate the survey tool and report the findings to Council by its October Interim Meeting.

**11. Adjournment:** The 2014 AACA Annual Business Meeting was adjourned at 6:06 p.m.

Respectfully submitted,  
H. Wayne Lambert, Ph.D., AACA Secretary

# **2014 – 2015**

## **Officers of the AACCA Council**

**President** - Brian R. MacPherson, Ph.D.

**President-Elect** - Neil S. Norton, Ph.D.

**Secretary** - H. Wayne Lambert, Ph.D.

**Treasurer** – Carol S. Lomneth, Ph.D.

**Past-President** - Anne Agur, Ph.D.

**Program Secretary** – Noelle A. Granger, Ph.D.

### **Councilors**

Brion Benninger, M.D., M.S., ChB, MSc

R. Shane Tubbs, Ph.D.

Sarah Keim-Janssen, Ph.D.

Marios Loukas, M.D.

Brandi J. Schmitt, M.S.

Anne M. Gilroy, M.A.

Rebecca Pratt, Ph.D.

Robert Spinner, M.D.

Philip Fabrizio, M.S., PT, MPT, DPT

Lisa M.J. Lee, Ph.D.

# ***Clinical Anatomy***

The Official Journal of the American Association of Clinical Anatomists, the British Association of Clinical Anatomists, the Australian and New Zealand Association of Clinical Anatomists, and the Anatomical Society of Southern Africa

**Editor-in-Chief** – R. Shane Tubbs, Ph.D.

**Editor Emeritus** – Stephen W. Carmichael, PhD

**AACA Co-Editors** – Senior Editor: Robert J. Spinner; Anthony V. D’Antoni, DC, Ph.D., Thomas R. Gest, Ph.D., John T. Hansen, Ph.D., Marios Loukas, M.D., Ph.D., Susan Stranding Ph.D., DSc, Joel Vilensky Ph.D.

**BACA Editor** – Stuart W. McDonald, Ph.D.

**ASSA Editor** – Graham Louw

**ANZACA Editor** – Stephanie Woodley, Ph.D., MSc, BPhty

**Editorial Assistant** – Amy Finch

**Reference:** Anastacia Arynchyna

**Production Editor:** Diane Grube

**Founding Editors:** Ralph Ger and Ray J. Scothorne

## **Editorial Board – 2015 Associate Editors**

Marwan Abu-Hijleh  
Robert H. Anderson  
Nihal Apaydin  
Brion Benninger  
Aaron A. Cohen-Gadol  
Peter Dangerfield  
Raffaele De Caro  
Fabrice Duparc  
Jerzy Gielecki  
Somes Guha  
Ake Hansasuta  
David Heylings  
Hee-Jin Kim  
Sarah Mackay  
Vishy Mahadevan  
Petru Matusz  
Ali Mirjalili  
Stanley Monkhouse  
Martin M. Mortazavi  
Janusz Moryś  
Bernard Moxham  
Horia Muresian

Richard Newell  
Johann Peltier  
Alan T. Richards  
Elias Rizk  
Daisy Sahni  
José Ramón Sañudo  
Louise Scheuer  
Carol E. H. Scott-Conner  
Mark F. Seifert  
Jonathan Spratt  
Mark D. Stringer  
Richard Tunstall  
Albert van Schoor  
Huan Wang  
Robert Ward  
Koichi Watanabe  
Peter L. T. Willan  
Bülent Yalçın  
Anna Żurada



# Committee Reports

Anatomical Services Committee  
Career Development Committee  
Clinical Anatomical Terminology Committee  
Educational Affairs Committee  
Journal Committee  
Meeting Oversight and Program Planning Committee  
Membership Committee  
Nominating Committee  
2015 Annual Meeting Committee  
Listserv Admin Report

## 2015 Anatomical Services Committee Report

The Anatomical Service Committee (ASC) and special interest group (SIG) represents both academic and technical members of the Association who are active in the operations and administration of institutional whole body donation programs. We function to serve the association's membership through the development of symposia, courses and guidance documents and promote technical and academic aspects of human anatomical specimen use in health care and university education and research. The group advocates informed, ethical, safe operations for students, faculty, staff and researchers who contribute to medicine, education and research through the use of anatomical materials. The ASC meets monthly to plan annual meeting activities, discuss and act on relevant items that range from current practices, related legal and media items to pertinent Association bylaws and topics for future symposia. Some specific items that were developed in 2014/2015 include an appendix to the association's policy for vendors with anatomical materials as well as the development of a new award for Anatomical Services presentations. More on these topics can be found on the AACA website or by speaking with an ASC member.

The AACA maintains an active listserv specific to anatomical services, which helps to facilitate open discussion of relevant issues. We use this listserv to raise awareness, communicate with colleagues and to gather information. Our committee members regularly interact with members of other professional societies and on topics of mutual interest. The ASC area of the AACA webpage is a resource where position statements, best practices, contact information and various links can be accessed. Visit our webpage or reach out to a committee member for additional information.

### 2015 AACA Annual Meeting Anatomical Services Committee events include:

- Members of the Anatomical Services Committee will be present at the Welcome Reception on Tuesday, June 9th from 6:30 – 8:30 PM. Additionally, you will find ASC members and anatomical services members at the Mentor Reception on Wednesday June 10th from 5:00 – 6:00 PM. AACA meeting attendees and members interested in Anatomical Services are encouraged to attend, meet the committee and SIG members, and learn what we do or how to get involved.
- The annual breakfast meeting takes place on Friday, June 12th from 7:30 to 9:00 AM. The ASC will be presenting on Lessons Learned where real case studies in academic donation programs will be presented. Active AACA members will be voting for a new Anatomical Services Committee member and the agenda will include a report on the work of the Anatomical Services committee during the last year as well as discussion of current topics, future meetings and symposia. All meeting attendees are welcome to attend.

### Presidential Appointees:

2012-2015: Quentin Fogg

2013-2016: Todd Hoagland, Academic Co-Chair - thoagland@mcw.edu

2014-2017: Andrew Corson

### Elected Members:

2012-2015: Brion Benninger

2013-2016: Jennifer Mark

2014-2017: Angela McArthur

### Ex Officio:

Brandi Schmitt, Technical Co-Chair, ASC Special Councilor - brandi.schmitt@ucop.edu

## Career Development Committee

The role of the Career Development Committee (CDC) is to support career growth and the advancement of clinical anatomy knowledge for individuals at any stage of their career. Additionally, the CDC strives to encourage high quality anatomical research and scholarly educational work. The committee accomplishes these goals through sponsoring numerous activities, including the following at the annual meeting: judging of student posters (Sandy C. Marks, Jr. Award) and platform presentations (Ralph Ger Award), and sponsoring the CDC Breakfast Meeting and Mentorship Reception. Every other year, the CDC sponsors the Career Development Symposium.

We thank all of you who agreed (or at least were willing, but weren't able to help this year – we appreciate you too!) to assist our committee with the judging process for the Marks and Ger Awards. As we know, mentorship extends from laboratories and classrooms to peer-reviewed arenas such as the poster and platform presentations. Judging plays an important role in that process. This year in addition to the standard paper judging forms, we have developed a Google Forms based judging form. We encourage you to use your favorite electronic device to enter your judging scores and comments. The electronic format promises to ease the tabulation process and provide timely feedback to those eligible for awards, both of which were difficult to do using the paper process. Instructions will be provided at the Judge's Orientation Meeting Tuesday, June 9, 5-6 pm.

During the Breakfast Meeting on Wednesday, June 10, 7:30-9 am, we will seek input and discuss plans for proposing the establishment of formal clinical anatomy scholarly exchanges beyond the informal mentorship that already occurs at the Mentorship Reception. We'll have a busy morning and would love to have you participate in what promises to be a lively discussion.

The theme for this year's bi-annual CDC Symposium on Wednesday, June 10, 1-2:30 pm, is *Changing Paradigms in Academics*. We have an exciting panel of speakers this year: Andrew Cawrse will be speaking on the role and influence anatomists have in Hollywood, media and art; Frank Daly will address how anatomists can be part of the important process for surgical training; Roy Phitayakorn will expound on the important relationship between anatomists and surgeons in the clinical teaching arena. After each of our guests has addressed us, we will be privileged to participate in a panel discussion.

This year's Mentorship Reception on Wednesday, June 10, 4:30 -6 pm, will have a different format from those in past years. First, we invite conference attendees who consider themselves to be Mentees to attend the entire reception. During the first 30 minutes, Alan Detton will present his thoughts on how to maximize the mentorship process, and how that can translate into finding the right career path. It will be a good preview for meeting those conference attendees who consider themselves to be Mentors when they join us at 5:00 pm. Second, all Mentees who attend the reception will receive an access code to an electronic anatomy teaching resource or app that was generously donated. Mentees can also enter the raffle, but this time we will only have a limited number of textbooks so that Mentees and Mentors can focus on meeting each other.

If you have a passion for mentoring and innovative ideas to promote career growth, please consider becoming a member of the CDC. We will be electing two new members at our Breakfast Meeting. Even if you don't get elected, or are more interested in informal involvement, we have project-specific sub-committees that could use your help! Come to one of our events this year and connect with a member of the committee to get more information.

### CDC Committee

#### Presidential Appointees

2012 – 2015: Jonathan Wisco, Chair (Brigham Young University)  
2013 – 2016: Sarah Greene, Incoming Chair (Morehouse School of Medicine)  
2014 – 2017: Tony Olinger (Kansas City University of Medicine and Biosciences)

#### Elected Members

2013 – 2015: Dolgor Baatar (Texas Tech University of Health Sciences)  
Gib Willett (University of Nebraska Medical Center)  
2014 – 2016: Alan Detton (Stanford University School of Medicine)  
Nirusha Lachman (Mayo Clinic)

The CDC would like to thank the outgoing elected members, Dolgor Baatar and Gib Willett for their incredible service the past two years, Caitlin Hyatt and Shanan Atkinson from Association Services Group (ASG) for their assistance, and all members who helped our committee in some manner this year, including and especially our Award judges.

# Clinical Anatomical Terminology (CAT) Committee

## Clinical Anatomical Terminology (CAT) Committee Activities – Henderson 2015

### Friday, June 12. 1:00 - 2:30pm - Open Meeting

All AACA members and meeting attendees are welcome! We will be sharing the progress of the discussions between AnatomicalTerms.info, CAT and the Federative International Programme for Anatomical Terminology (FIPAT) regarding cataloging and defining anatomical terms for world reference and use. The interests and concerns of attendees will shape the activities of the CAT Committee during the coming year. We will elect a new member for the 2015-2018 cycle. And, Lippincott Williams & Wilkins will again sponsor the annual Clinical Anatomical Terminology contest! We look forward to seeing you there!

### Thursday, June 11. 2:15-3:00pm - CAT Committee Symposium

#### “Towards a Universal Anatomical Terminology for the Health Sciences”

##### Speaker: Dr. John Fraher MB, FRCSEdin, PhD, DSc, FAS(hon), MRIA

Bio Excerpt: Dr John Fraher qualified in Medicine and Science from University College Cork, Ireland. He has the PhD and DSc degrees from the University of Edinburgh. He is FRCS Edinburgh, an Honorary Fellow of the Anatomical Society and a Member of the Royal Irish Academy. He held tenured posts at the Universities of Edinburgh and London before becoming Professor and head of the Anatomy Department at University College Cork (UCC), where he established Neuroscience as a teaching and research discipline. He was Foundation Director of UCC's flagship BioSciences Institute. He has been President of the Anatomical Society of Great Britain & Ireland and also of the European Federation for Experimental Morphology. He is Chair of the Federative International Programme for Anatomical Terminology of the International Federation of Associations of Anatomists.

The **Clinical Anatomical Terminology (CAT)** committee was formed to investigate the usage of clinical anatomical terms and provide a forum for discussion about their history and evolution into the various synonyms used today by anatomists, clinicians, and educators.

Our primary activity is to develop and implement multiple mechanisms by which both clinical and anatomical systems of nomenclature can be cross referenced and described in order to improve the educational experience for students and faculty, and simplify communication between a broad spectrum of medical and allied health professionals and educators. To this end, members of the CAT committee engage in collecting anatomical terms used by various constituencies (e.g. FIPAT, anatomists, clinicians of various specialties, authors) around the world, documenting their usage, and tracing their history. Currently, these activities are channeled into the development of two websites and a collection of abstracts from papers that focus on clinical anatomical terminology.

[www.AnatomicalTerms.info](http://www.AnatomicalTerms.info) (ATI) has been live for one year! ATI, which was initiated by AACA member Dr. O. Paul Gobée, Leiden University Medical Center, is a central repository of world-wide anatomical terminology. The CAT committee joined forces with Dr. Gobée during development of ATI and continues to support the site by adding terms and definitions and reviewing external submissions.

<http://elpaso.ttuhsu.edu/fostersom/curriculum/ClinicalAnatomicalTerminology.aspx> was created by AACA member Dr. Tom Gest as a quick reference for Terminologia Anatomica and most commonly used clinical anatomical terms. The CAT committee is working with Dr. Gest to update the website.

[http://clinical-anatomy.org/content.php?page=CAT\\_Abstracts](http://clinical-anatomy.org/content.php?page=CAT_Abstracts) **CAT Abstracts** is a collection of abstracts and citations of papers that focus on clinical anatomical terminology. These materials are accessible on the Clinical Anatomical Terminology Committee page.

### CAT Committee Members

**Clinical Councilor, ex officio** - Robert Spinner, ex officio, [spinner.robert@mayo.edu](mailto:spinner.robert@mayo.edu)

#### Presidential Appointees

2012-2015: Tom Gest [thomas.gest@ttuhsc.edu](mailto:thomas.gest@ttuhsc.edu)  
2012-2015: Rebecca Pratt [Rebecca.Pratt@radiology.msu.edu](mailto:Rebecca.Pratt@radiology.msu.edu)  
2013-2016: Sherry Downie, Chair [sherry.downie@einstein.yu.edu](mailto:sherry.downie@einstein.yu.edu)  
2013-2016: Brad Martin [bdmartin@llu.edu](mailto:bdmartin@llu.edu)  
2014-2017: Paul Gobee [p.gobee@lumc.nl](mailto:p.gobee@lumc.nl)  
2014-2017: Ian Whitmore [iwhitmore@argonet.co.uk](mailto:iwhitmore@argonet.co.uk)

#### Members-at-Large Elected at Annual SIG Meeting of Committee

2012-2015: Brion Benninger [bbenninger@westernu.edu](mailto:bbenninger@westernu.edu)  
2013-2016: Anthony Olinger [aolinger@kcumb.edu](mailto:aolinger@kcumb.edu)  
2014-2017: Alan Richards [richards5@cox.net](mailto:richards5@cox.net)

## Educational Affairs Committee

### Purpose of Committee

The Educational Affairs Committee (EAC) shall promote the teaching of clinical anatomy, track national and international curricular changes, and develop educational initiatives that will benefit the Association's members, health care professionals, the educational community, and the general public. The Committee shall disseminate data and recommendations for best practices for all aspects of anatomical education as it relates to clinical practice. The Committee shall plan and implement the Educational Affairs Symposium when scheduled by the Meeting Oversight and Program Planning Committee.

The Committee shall consist of six (6) members, each serving a three (3) year term. The President-Elect shall appoint one (1) member in the second year of his/her term, and the President shall appoint one (1) member in the first year of his/her term. One (1) member shall be nominated and elected by the Active Members in attendance at its annual open meeting.

### EAC Members

#### Presidential Appointees

2012-2015: Jennifer Burgoon, Chair (jennifer.burgoon@osumc.edu)

2013-2016: Erin Fillmore (efillmor@imail.iu.edu)

2014-2017: April Richardson-Hatcher (arich3@uky.edu)

#### Members-at-Large Elected at Annual SIG Meeting of Committee

2012-2015: Ann Poznanski (ann.poznanski@cnsu.edu)

2013-2016: Lonnie Salkowski (lsalkowski@gmail.com)

2014-2017: Vaughan Lee (vaughan.lee@ttuhsc.edu)

During the 2014-2015 committee meetings, the EAC prepared for the upcoming breakfast at the 2015 annual meeting, as well as began discussions and planning regarding the EAC symposium for the 2016 annual meeting. For the 2015 EAC breakfast, besides holding a short business meeting, Dr. Adam Fisch (i.e., author of *Neuroanatomy: Draw It to Know It*) will speak about the importance of drawing in anatomy education. After the short talk by Dr. Fisch, **breakfast attendees will be asked to provide examples of drawings that they themselves use in their classrooms and laboratories.** They can either bring their completed drawings with them to the breakfast or create their drawings in-person at the breakfast using provided paper and markers.

Discussions for the 2016 EAC symposium topic have primarily consisted of utilizing ultrasound in anatomy education including ultrasound training for anatomists, integration of ultrasound in the anatomy curriculum, and securing funding for ultrasound equipment. Early planning continues with a possible selection soon of a final topic area and speaker(s) for the 2016 EAC symposium.

Lastly, at the EAC breakfast at the 2014 annual meeting, attendees formed sub-interest groups in the areas of: 1) *educational technology in anatomy education*; 2) *educational research methods*; 3) *post-graduate courses in anatomy*; and 4) *humanities and anatomy education*. During 2014-2015, the EAC worked with ASG to create listservs for the sub-interest groups. Listservs for 3 of the 4 sub-interest groups have been developed and conversations have begun; a listserv for the remaining sub-interest group (i.e., humanities and anatomy education) will be created next, followed by any additional sub-interest groups created at the EAC breakfast at the 2015 annual meeting.

## **Journal Committee**

Committee Members: Neil S. Norton (chair), Brian MacPherson, Carol Lomneth, Shane Tubbs (ex officio).

Following the conclusion of the 2014 AACA Annual Meeting in Orlando, the Journal Committee worked with Shane Tubbs, Editor in Chief of Clinical Anatomy on the financial plan for the upcoming 2015 developmental funds. Pursuant with the new Publishing Agreement, each year the EIC develops a plan for the development funds which must be discussed and approved by the Journal Committee. Additionally, based on the successful symposium organized by Shane Tubbs at the Annual Meeting, another symposium was proposed for the 2015 Annual Meeting to be held in Henderson, NV. A new area that arose from the Annual Meeting was the possibility of journal-based CME. Tiffany McKarahan of Wiley spoke with Wiley's internal CME development expert, Sally Cowlard to examine the feasibility. A conference call between members of the Journal Committee and Wiley occurred to form the foundation of offering CME through Clinical Anatomy.



# **MOPP Committee Annual Report, 2014-2015**

## **Members**

### **Executive Committee**

Program Secretary - Noelle Granger, MOPP Chair  
President - Brian MacPherson  
President-Elect - Neil Norton  
Past President - Anne Agur  
Treasurer - Carol Lomneth  
Association Secretary – H. Wayne Lambert

### **Special Interest Committees**

Anatomical Services, Co-Chair - Brandi Schmitt  
Anatomical Services, Co-Chair – Todd Hoagland  
Career Development Committee, Chair – Jon Wisco  
Educational Affairs, Chair – Jennifer Burgoon  
Clinical Anatomical Terminology Committee – Sherry Downie

### **Annual Program Committee Co-Chairs**

David Porta  
Sherry Downie

### **ASG Representatives**

Shanan Atkinson  
Caitlin Hyatt

The MOPP Committee meets on the first Thursday of every month by teleconference. During the past year the following issues were addressed:

### **Site of Annual Meetings**

- Site for the 2015 meeting: Las Vegas. This meeting is unusual in that there is no local host, and the post-graduate course on ultrasound instruction will only be held if sufficient members enroll to offset the cost.
- Site for the 2016 meeting: Oakland, CA. Brandi Schmidt and Kimberly Topp will be local co-hosts.
- Site for the 2017 meeting: Minneapolis, MN. The hotel site is currently being chosen. CME credits should be available for this meeting. Tony Weinhaus at the University of Minnesota Medical School will be the local host.
- Site for the 2018 meeting: San Antonio, TX is being discussed. The local host would be Chris Walter, Professor and Chair, Department of Cellular and Structural Biology, UTSA Health Sciences Center
- Site for 2019 meeting: Fort Worth, TX is being discussed. Rusty Reeves at the UNT/UNT Health Science Center in Fort Worth has expressed interest in hosting the annual meeting.
- Site for 2020 meeting: Charlotte, NC. This will be a joint meeting with BACA.

### **Discussion items from this year**

- Honorarium guidelines for speakers were proposed by the Committee and will be presented for acceptance by Council at the annual meeting.
- Changes in registration and abstract submission guidelines were approved by Council and subsequent changes in Policies and Procedures were made. Continuing difficulties with abstract submissions are currently being addressed by further modifications.
- There was a discussion of symposium expenses. The normal annual amount was retained but it was decided to allow a roll-over of unexpended monies for a two year period. This would allow the Committees with a major symposium each year to pay for good outside speakers.

*continued on next page*

- Changes in the structure of the annual meeting with the addition of a fourth committee (CAT) were successfully employed at the 2014 meeting in Orlando. A further change, which would move the banquet to Friday night of the meeting instead of Thursday, cannot be tested until the 2016 meeting in Oakland because of room rental patterns in Las Vegas related to casinos.
- A new fee schedule for registration and events for non-members was created for the 2015 Las Vegas meeting: the banquet cost is rolled into the registration fee, as requested by members, and attendance at various social events for non-members is offered at both a flat rate for all events and at individual rates for each event.
- It was suggested that the AACA offer an Early Career membership option, similar to what is offered by the American Association of Anatomists. It was decided because our membership fees are already low compared to the AAA and because tracking the careers of young professionals would be impossible, not to offer this option.
- The organization of the first regional meeting in Salt Lake City was completed by local host Jon Wisco. Advertisement of the meeting will begin after the annual meeting in June. The second regional meeting will be held in Chapel Hill, NC in October 2016 and will be organized and hosted by Kurt Gilliland.
- AACA membership cost for anatomical services staff was finalized at \$100. This would cover the cost of the electronic version of Clinical Anatomy. The Anatomical Services Committee will check on all those who apply for this category of membership.
- The AACA will advertise an Anatomical Services Prize for the best presentation by an Anatomical Services member at the annual meeting. The Anatomical Service Committee will oversee the selection of the prize winner.
- ASG reminded the MOPP Committee that prices charged exhibitors have not changed in many years. The majority of the Council voted for \$100 increase, followed by a cost of living increase of \$5-10 each year. This will be offset by the offering to the exhibitors participation in all social events and the banquet.
- A survey of members on the value and content of the post graduate courses offered at the annual meeting is planned.

## Membership Committee

Committee Members: Neil S. Norton, Anne Agur, Samuel Franklin

The Membership Committee is pleased to report that the following new members have joined the AACA from August 2, 2014 – April 22, 2015

### **REGULAR MEMBERS – ELECTRONIC**

Cheryl Purvis  
Amy Burnell  
James Lewis  
Devendra Sawant  
Sanjay Patel  
Laura Welke  
Enyinnaya N Merengwa  
Evan Garofalo  
Paul Walker  
Evan Daugherty  
Lennox Francis  
Marco Segovia  
Zhenyun Yang  
Eiman Abdel Meguid  
Krystle Theriot  
Thomas Perrault  
Melanie McCollum  
Adel Mohamed  
Paul Brisson  
Eileen Kalmar  
Virginia Pascoe  
Noel Guison  
Sherif Hassan  
Lauren Arms  
Daniel Roe  
Jay Crutchfield  
Mukarram Uddin  
Matthew Zdilla  
Miguel Angeles  
Thomas Mark Vesely  
Vasudha Saralaya  
Bulent Yalcin  
Terrel Master  
Itsuko Okuda  
Nihal Apaydin  
Carol Bisnath  
Olutayo Ariyo  
Hugo Bergen  
Rehana Lovely  
Liana Merrill  
Mark Blais  
Rachael George-St Bernard  
Syed Mustafa Raza Ali Kazmi  
Geoffroy Noel  
Kristina Pugh  
Ivan Varga

Ahmed Mahgoub  
Deepak Sharma  
Arlene Blake-McCain  
olufemi Bogunjoko  
Priya Debnath  
Temitope Kehinde  
Olufemi Obadina  
Feimatta Sowa  
Kristna Thompson  
Danny Burns  
Dipen Patel  
Madonna Phillip  
Stanley Lliff  
Nan Lin  
Sean Newton  
BV Murlimanju

### **REGULAR MEMBERS – PRINT**

Allan Besselink  
Oleg Alekseev  
Shrish Patil  
Matthew Thomason  
Deepak Tikoo  
Robert Edward Clemency, III  
Anthony Hewetson  
Kerry Gilbert  
Sebastian Laza  
James Coey  
David Ezra  
Elizabeth R. Whitney  
Soumitra Trivedi  
Dana Mihaila

### **AFFILIATE MEMBERS**

Darryl John McAndrew  
Philip Adds  
Charmaine Lok

### **ASSOCIATE – POST DOC/ RESIDENT**

Sung Deuk Kim  
Vijay Krishna  
Bradley Charran  
Alper Cesmebasi  
Natasha Flack  
Yasmin Carter

### **ASSOCIATE – ELECTRONIC**

Melissa Sorrells  
Justin Harrell  
Teresa Patitucci  
Mika Hirano  
Djavlon Khakimov  
Alisha Poonja  
Eduardo Camara  
Juan Dominguez  
Tatiana Ndjatou  
Abubakar Bello  
Joyce Kuik  
Vuvi Nguyen  
Ashley Olson  
Mai-Lan Johnston  
Ellis Kelly  
Yolanda Scoleri  
Trudy Hong  
Juston Owens  
John Khoushoo  
Alison Longo  
Saskia Richter  
Christopher Hutton  
Mandalyn Kautz  
Kristen Giefer  
Alyssa Greenwell  
Philip Nation  
William Puetz  
Shireen Sachdeva  
Matthew Steritz  
Justin Oveyssi  
Johanna Gerwer  
John Ko  
Julie Ronecker  
Danielle Severns  
Maxine Vienneau  
Kyle Busch  
Jason Kum  
Laura Palmer  
Riad Bankusli  
Ian Blandford  
Nicholas Elwert  
Caleb Vass  
Lacey Colvin  
Stephen Housley  
Kelsey Baran  
Daphnee Beaulieu  
John Carter

Brian Gould  
Brayden Healey  
Raksha Hemanth  
Tom Iwan  
Adam Kimball  
Robert Tomasz Wawrzyniec  
Kosalka  
Robert Kosalka  
Kyler Kozacek  
Lisa McLane  
Vitaliy Natkha  
Ankura Patel  
Jainesh Patel  
Matthew Richardson  
Gillian Richmond  
Michael Romani  
Pamela Schultz  
Anton Semechko  
Naveen Sooknanan  
Michael Sunderland  
Abbatiello Thomas  
Sunay Patel  
Victoria Flores  
Hanan Yassa  
Yair Blumberg  
Daniel Barrack  
Michal Miko  
Jonathan Wright  
Nathan Hua  
Chen-En Hsieh  
Jefferson Li  
Anthony Whitlow  
Aisha Athar  
Khoi Paul Dang-Ho  
Zoe McKinnell  
Sanjay Singh  
Wesley Nilsson

### **ASSOCIATE – PRINT**

Corey Hounsshell

## Nominating Committee

A call for nominations was distributed to the membership in August of 2014 for the 2015 AACA Election for President-Elect, Program Secretary, Special Councilor (Anatomical Services), and 2 Councilor-at-Large positions.

**President-Elect** – There were two nominations, but several other candidates were discussed. The nominating committee selected three names and two agreed to be on the final ballot: Marios Loukas and Brandi Schmitt.

**Program Secretary** – There were two nominations for this position and the nominating committee selected both for the final ballot: David Porta and Gregory Smith.

**Special Councilor** – Anatomical Services – There were two nominations for this position and the nominating committee selected both for the final ballot: Frank Daly and Angela McArthur.

**Councilor-at-Large** – There were five nominations for the two positions available and the committee also discussed several other candidates. The nominating committee selected four names and three agreed to be on the final ballot: Stephen Carmichael, Anthony D'Antoni and Alan Detton.

### Method of Slate Selection

Email correspondence and a telephone conference call of the nominating committee occurred from December 2014 through February 2015 to discuss the protocol for the nomination process and to discuss candidates. The call for nominations began August 1, 2014 and closed December 31, 2014 via email reminders to the AACA membership. A list of nominees and CV's were collected and distributed electronically to all members of the nominating committee. Each committee member was asked to review the nominees in preparation for a committee conference call. A conference call was held on January 23, 2015 to discuss and vote on the names to be placed on the final ballot.

Committee members 2014-2015:

Anne Gilroy, University of Massachusetts Medical School

Todd Hoagland, Medical College of Wisconsin

Rebecca Lufler, Tufts University School of Medicine

David Porta, Bellarmine University

Thomas Quinn, Creighton University

Respectfully submitted,  
Rebecca Lufler, Chair

## 2015 Annual Meeting Committee (AMC) Report – April 22, 2015

**Committee Members:** David Porta (2014 and 2015 AMC Co-Chair), Sherry Downie (2015 AMC Co-Chair and CAT Chair), Brandi Schmitt (ASC Co-Chair), Todd Hoagland (ASC Co-chair), Jennifer Burgoon (EAC Chair), Jon Wisco (CDC Chair), Noelle Granger (MOPP Chair), Carol Lomneth (Finance Committee Chair), Caitlin Hyatt (ASG), and Shanan Atkinson (ASG).

**Committee Charge:** The committee worked as a team to produce the highest quality AACA annual meeting possible for this year. This included, but was not limited to oversight of:

a) The abstract submission and review processes; and b) Setting the meeting composition and schedule. An attempt was made to hold a Post-graduate course in Henderson titled “Fundamentals of Bedside Ultrasound – A Hands on Course.” Sakti Srivastava offered the course but registrations fell short of the minimum 30 necessary to operate the course at only a minor revenue loss and it was cancelled effective 4/21/15.

This year: Our work began with a debriefing meeting on the last day of the 2014 AACA Meeting in Orlando. Various logistical problems were discussed and plans were made to avoid such issues in the future. This included a site visit to the Green Valley Ranch resort in order to be sure the facility was adequate for our meeting and the various ancillary events. The AMC continued with conference call meetings every 3rd Wednesday of the month. All of the members of this committee also serve on the MOPP. This year, David Porta and Sherry Downie served as AMC Co-chairs with the intention of starting a process whereby Co-Chairs will serve alternating 2 year terms. Next Year Sherry Downie will serve her second year and Rebecca Pratt will serve her first.

### Highlights:

- 1) Timeline.** Council decided to move the annual meeting from July to June. In concert with ASG, the timeline for abstract submission deadlines & review, as well as the annual meeting planning were adjusted accordingly.
- 2) Committee Plans.** The Clinical Anatomical Terminology (CAT) committee and the Career Development committee (CDC) planned for symposia at the 2015 meeting. All 4 committees planned meetings for elections and committee business (CDC, Educational affairs and Anatomical Services planned breakfast meetings). The CDC also planned for the Mentor-Mentee Reception and judging of posters and platforms. The ASC instituted a new award for the best presentation by an Anatomical Services staff member.
- 3) Abstract submissions & review.** Following up the process created last year, the AMC Co-Chairs performed initial format reviews of the 147 abstracts submitted for the 2015 annual meeting (vs. 139 in 2014). 60 were submitted by Regular members and 87 by Associates. 55 had minor errors that were repaired by the AMC Co-Chairs. Another 51 did not pass the format review and were returned to authors (vs. 20 in 2014). Most of these were revised and resubmitted with an additional \$20 resubmission fee. Each submission was then sent to 3 reviewers and judged using a 20-point scale. Reviewers also suggested a presentation format (poster or platform) and whether or not the abstract should be published in our journal. Like last year, a late-breaking abstract submission date was utilized and 21 additional abstracts were received and reviewed (vs. 26 in 2014). The late-breaking abstracts, if accepted, are only presented as posters and are ineligible for awards or abstract publication.
- 4) Reviewing Results.** At this time, a total of 24 abstracts have been withdrawn or rejected (vs. 10 in 2014). The highest rated abstracts were designated for Platform presentations, provided the author agreed. 22 Authors were invited to present from the platform and have their abstracts published (29 in 2014). 3 authors were approved for Tech Fair presentations (vs 6 in 2014). 78 abstracts were accepted for poster presentation and publication (vs 80 in 2014). 43 were accepted for poster presentation only (vs 40 in 2014).
- 5) 2015 Block Schedule and Program.** The Annual Meeting Block Schedule was built on the 2014 model, but revised numerous times. The 4 poster sessions were extended by 15 minutes to 1 hr and 15 mins each. A serious effort was made to group the posters by anatomical regions. Additional afternoon breaks were added and the lunch period was scheduled in graduated fashion- 1.5 hrs on Wednesday, 1:15 on Thursday and 1 hr on Friday. The Business Mtg and Awards ceremony were moved to Friday afternoon in order to accommodate the Thursday banquet and the need for extended judging time for platforms and posters. In addition to the scientific portion of the meeting, plans were also made for a special social event on Wednesday evening. Bob Acland has arranged for a short series of talks and the showing of examples of the “High Point in Anatomical Art.” There will also be a Thursday lunch event planned by EIC Shane Tubbs and sponsored by our publisher.

In summary, the Annual Meeting Committee has worked diligently to produce a top quality conference. We sincerely hope that you enjoy it. Should you have suggestions for next year, please don't hesitate to forward them to Sherry Downie, 2016 AMC Co-Chair, at [sherry.downie@einstein.yu.edu](mailto:sherry.downie@einstein.yu.edu).

Respectfully submitted on behalf of the committee,  
David Porta & Sherry Downie, 2016 AMC Co-Chairs



# Educational Issues Listserve

## Annual Subscriber & Activity Report

In March, 2015, the "AACA" Educational Issues List turned 20 years old.

The number of subscribers to the List, as of May 15th, is 1,391. In the period reported upon here (Jan. 1, 2014 – May 15, 2015), fifty-five "unsubscribe notifications" were sent to me by the mailserver. The vast majority of these notices, indicating a subscriber's address was deleted from database, were generated because the server was receiving bounced email in a frequency and pattern that it interpreted as coming "non-functioning" address. Please note that turning on your "Auto-Reply" or "Out-of-the-Office" auto-responder generates a message that is almost universally interpreted by mailserver programs as a bounced-message from a non-working external email address. During the same period of time, I received forty "subscription notifications" that a new email address was added. I have not determined how many of these were first time new subscribers vs. people rejoining the list.

Since its inception in 1995, over 10,500 messages on a wide variety of topics have gone out to subscribers (average about one message every 2 days). In the period reported upon here, there were 276 subjects posted. Those that received the most responses are listed in the table at the end of the report.

I think the most exciting news to report about the Educational Issues List is that the twice-unsuccessful effort to create an interactive searchable archive of the entire list of messages has been vigorously renewed thanks to the interest, generosity and enthusiasm of Sakti Srivastava at Stanford University. During the List's infancy, Einstein's IT team made an initial attempt to store outgoing messages in a searchable format but this project was rapidly replaced by tasks deemed more important. Ten years later, Tom Gest made a valiant attempt to create a searchable archive for the first fifteen (15) years of List messages during what would be his last year at University of Michigan. Needless to say moving to Florida prevented him making as much progress as he had hoped. However, Tom did succeed in beginning the archive process (for the most recent several years of messages) through 2009. Tom is giving Sakti all of the archived messages he finished at Michigan. Tom and I will work with Sakti to ensure he has a complete database of all messages that have been distributed to the list over the past 20 years. Sakti believes new technologies for identifying key words and phrases will make scanning and archiving messages in a searchable format much easier. I think we can all agree, based upon the frequency subjects reappear on the List – pregnant students, lab environment conditions, curriculum issues, etc. - that having a searchable format will greatly increase the value of this resource to AACA members.

Todd R. Olson  
List Administrator & Moderator  
May 15, 2015

**AACA Education List** <AACA@lists.aecom.yu.edu>

**Total Subscribers** (as of May 15, 2015) = **1,391**

**Activity 1/1/14 – 5/15/15** = 276 messages

**Discrete Threads / Conversations** = 88

**Monthly Email Activity** (past 12 full months only)

May '14	= 4
June	= 24
July	= 20
August	= 9
September	= 49
October= 23	
November	= 32
December	= 5
January '15	= 4
February	= 10
March	= 5
April '15	= 28

**Most Commented upon Threads** (number includes original post):

Gross Anatomy in the Integrated Medical Curriculum.....	25
Surgical lighting advice.....	12
Median Nerve fibre pearls .....	12

"On call" duty .....	11
Do students get to see their exams afterwards .....	10
Image software in the Lab .....	7
Fees for Anatomy Lab use .....	7
Policy for Outside Visitors .....	7
3d and virtual anatomy and anatomomage.....	7
6 threads had 5 comments on the original posted subject	

**AACA Anat Serv S.I.G. List**

<aaca-anatomical-services@lists.aecom.yu.edu>

Total Subscribers (as of May 15, 2015)	= 163 #
Activity 1/1/14 – 5/15/15	= 27 messages
Discrete Threads / Conversations	= 18

**Most Commented upon Threads** (number includes original post):

Policy for Outside Visitors .....	3
"On call" duty .....	3
Last –minute enrollees .....	3
7 threads had 1 comment on the original posted subject	

# = just over 100 of these subscribers also subscribe to the Educational Issues List.

# Abstracts – Platform Presentations

(listed by presenting author last name)

AL SAFFAR<sup>1</sup>, Radi A. and Quentin A. FOGG<sup>1,2</sup>. <sup>1</sup>Laboratory of Human Anatomy, School of Life Sciences, University of Glasgow, Glasgow, G128QQ, UK; <sup>2</sup>Centre for Human Anatomy Education, Monash University, Melbourne, Australia 3800.

## Palmar triquetrum-hamate ligaments determined by lunate type.

**INTRODUCTION.** The ligaments of the wrist are highly variable and poorly described; this is more extreme on the ulnar side of the wrist. Previous studies highlighted the potential differences within the ligaments of the wrist but no consensus has been reached. Poor tissue description and inconsistent use of terminology hindered the reproducibility of the results. This study aims to establish clear definition and quantitative description of the key palmar ligaments around the triquetrum-hamate joint categorised by lunate type. **METHODS.** Fifty-three embalmed and 10 unembalmed cadaveric specimens were dissected blind to lunate type. Individual ligamentous fascicles were traced under 6x magnification. A digitiser was used to reconstruct a 3D model of each wrist and to map the ligamentous attachment sites. Length, width and area of each ligament in addition to the area of each attachment were reported. **SUMMARY.** Variable patterns of ligamentous attachments were identified. Differences were not only obvious between samples but also between the right and left counterparts. While the type I wrists were predominantly identified with triquetrum-hamate-capitate complexes, the type II wrist were characterised by an extra segmental attachment between the triquetrum and hamate. There were no significant differences between the quantitative data obtained from the embalmed and unembalmed specimens ( $p>0.05$ ). **CONCLUSIONS.** The current study demonstrated variable ligamentous patterns that suggest different bone restraints and variable patterns of motion. These findings should be complemented with an extensive histologic analyses of the entheses to determine the mechanically significant attachments. Future studies will be dedicated to studying the functional variability of these ligaments in relation to bone morphology.

BENNINGER Brion<sup>1,2</sup>, Steven Carmicheal<sup>1</sup> and Tom Schlundt<sup>1</sup>. <sup>1</sup> Willd Body Donation Program, Medical Anatomy Center, Departments of Medical Anatomical Sciences, Neuromuscular Medicine, Family Practice, Western University of Health Sciences, COMP - Northwest, Lebanon, OR. USA; <sup>2</sup> Orthopaedic and General Surgery residency faculty, Samaritan Health Services, Corvallis, OR. USA.

## Comparing DirectVision urinary catheterization on multiple cadaver preparations for ideal teaching of healthcare trainees.

**INTRODUCTION.** Urinary catheterization (UC) is a common procedure that is often performed by a trainee with very little experience. Blind catheterization is associated with increased injury to the urethra. Anatomy courses do not teach students to conduct first time catheterizations on cadavers, which could minimize trauma to patients and provide confidence to the trainee. Simulators are not able to provide a lifelike experience regarding tissue resistance and urethral imaging. The DirectVision (DV) UC system enables viewing the urethra during UC with an actual tri-lumen Foley catheter (FC). There are several donor cadaver (DC) preparations one can choose to create the optimum form for a desired teaching effect. The objective of this study was to assess which preparations would be ideally suited to conduct UC by a medical student using the DV UC system. **METHODS.** Literature search was conducted regarding preparation types of DC's for UC during an anatomy course. A 3-way Foley catheter using the DV system was used on 4 separate DC preparations (fresh frozen-FF, Freedom Art-FA, Carolina-C, Western-W). Further 20 UC's was performed on C DC's by medical students. **SUMMARY.** Literature search revealed no known studies comparing DC preparations using the DV UC system. The FF (2-48hrs), FA (14 days), C (1year) and W (1 year) had successful UC performed using the DV system. Initially the urethra was not adequately viewed on all 4 DC preparations. Generally, continuous saline infusion is used in live patients to maintain a patent urethra for unobstructed viewing during DV UC. This study opted for an air infusion via the voiding lumen of the FC, which proved successful rather than the saline infusion, which would cause flooding on the DC table. All 20 C DC urethras were successfully viewed. **CONCLUSION.** This study revealed that DirectVision UC system can be successfully performed to view the urethra on several DC preparations making it ideal to teach UC in anatomy labs.

## Abstracts - Platform Presentations continued

BRUECKNER-COLLINS, Jennifer<sup>1</sup>, Paul KLEIN<sup>2</sup>, Leslee MARTIN<sup>2</sup>, Susan SAWNING<sup>2</sup>, Craig ZIEGLER<sup>2</sup>, Emily CARR<sup>2</sup>, Ann SHAW<sup>2</sup> and Amy HOLTHOUSE<sup>2</sup>. <sup>1</sup>Anatomical Sciences and Neurobiology and <sup>2</sup>Undergraduate Medical Education Office, University of Louisville School of Medicine, Louisville, KY 40202, USA.

### Tracking peer professionalism measures in preclinical medical students.

**INTRODUCTION.** Professionalism is a key competency in gross anatomy instruction, as evidenced by the 2006 special issue of Clinical Anatomy. However, there is a paucity of studies addressing medical students' ability to evaluate peers' professionalism in anatomy laboratory and to longitudinally track professionalism attributes into year 2. This study longitudinally compared 160 preclinical medical students' peer professionalism evaluations in 2 small group settings (year 1 anatomy lab and year 2 team based learning (TBL) sessions) for 2013-14 and 2014-15. **METHODS.** Students were evaluated by their small group peers on a scale (0-3) on 5 professionalism domains (teamwork; honor/integrity; caring/compassion/communication; respect; responsibility/accountability) at midterm and end of semester in years 1 and 2. Statistical comparisons were made between the formative and summative anatomy ratings and between the summative anatomy and midterm TBL ratings. **SUMMARY.** Anatomy professionalism evaluations showed an increase from an average ranking of 2.49 at midterm to 2.6 at the end of the semester ( $p<0.001$ ), with increases in teamwork ( $p<0.001$ ), honor/integrity ( $p<0.001$ ), caring/compassion/communication ( $p<0.001$ ) and respect ( $p<0.001$ ). Summative anatomy evaluations were compared to midterm 2nd year TBL, showing an increase in peer professionalism rankings ( $p<0.002$ ) with improvements in teamwork ( $p=0.036$ ), honor/integrity ( $p<0.002$ ), responsibility/accountability ( $p<0.005$ ) and respect ( $p<0.001$ ). **CONCLUSIONS.** Significant improvements in peer evaluated professionalism were observed in multiple domains over time in the anatomy lab, with the exception of responsibility and accountability. These gains were maintained into year 2 TBL evaluations, with the exception of caring, compassion and communication, suggesting that graded peer evaluation may improve professionalism behavior in small group settings.

CARTER Yasmin<sup>1</sup>, Adam MCKENZIE<sup>2</sup>, John COSTA<sup>3</sup> and Brent BURBRIDGE<sup>1</sup>. <sup>1</sup> Medical Imaging, College of Medicine, University of Saskatchewan; <sup>2</sup> Information Communications Technology, University of Saskatchewan. <sup>3</sup> Information Technology, College of Medicine, University of Saskatchewan, Canada.  
Creation of an online 'Medical Imaging Solution for Teaching and Research' (MISTR).

**INTRODUCTION.** Whilst clinical imaging is the most common way medical professionals experience anatomy in their careers, it has a small place in anatomical education. This is due to a number of factors; including reduction in anatomical program time, lack of educator experience, and lack of representative images. With this in mind, we have created the 'Medical Imaging Solution for Teaching and Research' (MISTR), an online image education resource. **RESOURCES:** MISTR is built on a two-pronged approach; first, we have the radiologists at the Department of Medical Imaging at the Royal University Hospital acquiring a library of useful cases of normal and variant anatomy into an adapted version of the Radiological Society of North America's Medical Imaging Resource Center-Teaching File System (MIRC-TFS). Second, we have the integration of these images into lectures and practical laboratories, through a unique online dicom image navigator 'ODIN' which preserves image resolution and facilitates easy image access. **DISCUSSION:** The key to MISTR's success is collaboration. While numerous images can be found online, non-specialist lecturers have no guarantee they were appropriately acquired or that they accurately represent the anatomy requested. Collaboration between academics and radiologists is flexible with more guidance available by consult, including pre-labeled images and case building with patient histories etc. Pilot projects in a number of departments have demonstrated high usefulness and interest on the part of students but a steep learning curve in "knowing what they are looking at"; we are currently building on this by incorporating mini lectures on the principles of radiology into classes and the creation of online modules. **SIGNIFICANCE:** Integrating clinical imaging earlier into the anatomical undergraduate curriculum allows students to better assimilate their understanding of anatomical structures as viewed in labs and text books with that seen through different imaging modalities, long term we suggest this will allow for easier comprehension of advanced clinical imaging and patient outcomes.

## Abstracts - Platform Presentations continued

CASTANOV, Valera and Anne M.R. AGUR. Division of Anatomy, Department of Surgery, University of Toronto, Toronto, ON M5S 1A8, Canada.

### Comparative analysis of the 3D musculotendinous architecture of the anterior thigh muscles.

**INTRODUCTION.** The anterior thigh muscles are important for gait and stability of the hip and knee joints. The musculotendinous architecture of these muscles has not been studied in 3D or compared in terms of their geometry and volumetric distribution of fiber bundles (FB) and aponeuroses. The purpose was to determine the spatial arrangement of the FBs and aponeuroses throughout the volume of sartorius (S), rectus femoris (RF) and tensor fasciae latae (TFL), and to compare their architectural parameters. **METHODS.** S, RF and TFL fiber bundles and tendons/aponeuroses, from one cadaveric specimen, were serially dissected and digitized using a Microscribe™ G2X Digitizer. Digitized data were reconstructed in Autodesk® Maya®, and fiber bundle length (FBL), pennation angle (PA) and physiological cross-sectional area (PCSA) were computed and compared between muscles. **SUMMARY.** The architecture of the FBs and tendinous components were found to differ in S, RF and TFL. RF had a thick posterior aponeurosis that extended the full length of the muscle, with a perpendicularly attached septum that divided the superior  $\frac{3}{4}$  of RF into medial and lateral parts. FBs of RF (n=4755 digitized) attached proximally to the posterior aponeurosis and septum in a bipennate fashion, and converged onto the quadriceps tendon. S (n=217 FBs digitized) and TFL (n=538 FBs digitized) had no internal aponeuroses; the FBs were arranged in parallel. S was found to have the longest mean FBL, which was 7.3 and 4.2 times greater than that of RF and TFL, respectively. RF had the largest PCSA (12.7cm<sup>2</sup>); the PCSA of TFL (3.5 cm<sup>2</sup>) and S (2.2 cm<sup>2</sup>) was markedly less. **CONCLUSIONS.** The extensive internal aponeuroses of RF provide a greater area of attachment for a larger number of FBs, than S and TFL, which have no aponeuroses. Therefore, RF had the largest PCSA and thus the greatest force-generating capability, while S had the longest FBL and smallest PCSA, indicating its role as an excursion muscle.

CESMEBASI, Alper<sup>1,2</sup>, Jay SMITH<sup>3</sup>, and Robert J SPINNER<sup>1</sup>. <sup>1</sup>Department of Neurologic Surgery, Mayo Clinic, Rochester, MN 55905, USA; <sup>2</sup>Department of Anatomical Sciences, St George's University, Grenada, West Indies; <sup>3</sup>Department of Physical Medicine and Rehabilitation, Mayo Clinic, Rochester, MN 55905, USA.

### The role of ultrasound in surgical decision-making for iatrogenic spinal accessory nerve injuries: A paradigm shift.

**INTRODUCTION.** The spinal accessory nerve (SAN) is susceptible to iatrogenic injury in the posterior cervical triangle. Early diagnosis and management of suspected SAN transection injuries is crucial to restore shoulder stability and function. While neurologic examination and electrodiagnostic testing can assess SAN function, they cannot assess nerve continuity. We present the use of US to prospectively evaluate the SAN in 6 patients with suspected iatrogenic SAN transection injury. **METHODS.** Six patients with suspected SAN transection injury following surgical procedures within the posterior cervical triangle were prospectively studied with high resolution US. All patients underwent a thorough neurologic examination and electrodiagnostic testing, as well as an US examination. US findings were used to assist in surgical decision making. Operative findings were correlated with the US results. **SUMMARY.** Sonography directly visualized SAN transection in 4 cases, while it reported "probable" transection in a fifth case and was non-diagnostic in the sixth case in the setting of extensive scarring. All patients underwent surgical exploration, and transection of the SAN was confirmed intraoperatively in all patients in this series. **CONCLUSIONS.** High resolution US shows great promise in the management of iatrogenic transection injuries of the SAN. With further development of technique and training of sonographic operators, the identification of a transected SAN early on by US will represent a paradigm shift by hastening surgical intervention and potentially improving patient outcomes.



## Abstracts - Platform Presentations continued

CESMEBASI, Alper<sup>1,2</sup>, Shawn W O'DRISCOLL<sup>1</sup>, Jay SMITH<sup>1</sup>, John A SKINNER<sup>1</sup>, and Robert J SPINNER<sup>1</sup>. <sup>1</sup> Mayo Clinic, Rochester, MN 55905, USA; <sup>2</sup>St George's University, Grenada, West Indies.  
The snapping medial antebrachial cutaneous nerve.

INTRODUCTION. Snapping elbow is a well-known condition where elbow flexion and extension elicits a painful, popping sensation. The most frequent etiology is anterior dislocation of the ulnar nerve over the medial epicondyle. We introduce a new entity, snapping of the medial antebrachial cutaneous nerve (MABC) over the medial epicondyle, as a cause of medial elbow pain. METHODS. Four patients presented with complaints of a popping sensation in the elbow, pain over the medial aspect of the forearm, and ulnar neuritis. All patients underwent preoperative dynamic ultrasound and surgical exploration of the medial elbow. SUMMARY. Three female and one male patient presented with complaints of a popping sensation in the medial elbow region, pain over the medial aspect of the forearm, and ulnar neuritis. At operation, snapping of the MABC was discovered in all 4 patients. In 3 patients, there was abnormal displacement of the medial triceps and ulnar nerve: in 2 of these, both structures dislocated over the medial epicondyle and in one patient both structures subluxated to the medial epicondyle (but not over it). In each case, the MABC was decompressed (n = 1) and transposed (n = 3), and in 3 cases, the medial triceps and ulnar nerve were addressed as well. Symptomatic improvement was achieved in all cases. Retrospective review of the ultrasound revealed the snapping MABC, though it was less effective prospectively in the cases when snapping MABC was not suspected. CONCLUSIONS. Snapping of the MABC broadens the spectrum of disorders that results in snapping elbow.

FOGG, Quentin A.<sup>1,2</sup>. <sup>1</sup>Centre for Human Anatomy Education, Monash University, Melbourne, Australia 3800; <sup>2</sup>Laboratory of Human Anatomy, School of Life Sciences, University of Glasgow, Glasgow, G128QQ, UK.  
Palmar radiocarpal ligaments: morphological asymmetry between external and internal surfaces.

INTRODUCTION. The palmar radiocarpal ligaments are essential for wrist stability. Their damage or disfigurement is involved in a number of common instability disorders and contributes to degenerative joint disease. The traditional, or open, view of the palmar ligaments is the mainstay of research and education when considering this area. However, an increasing number of surgical procedures are done arthroscopically and hence only involve visualisation of the internal (dorsal) surface. This study aims to quantify and demonstrate the morphological differences between the two surfaces of the same ligaments. METHODS. Embalmed (n=34) and unembalmed (n=6) specimens were dissected. Dorsal arthroscopic dissection followed by an "expanded arthroscopic" approach, previously described by Fogg (2010), was used to expose the internal surface of the palmar ligaments. The ligaments were photographed and rendered into a 3D virtual environment. The external dissection followed a traditional approach to expose the palmar surface of the wrist and the same imaging employed. Ligaments were identified and measured on both surfaces for comparison. SUMMARY. The external surface revealed 3±1.2 distinct bands. The internal surface demonstrated 4±1.7 distinct bands. The size and arrangement of the ligamentous surfaces were different. CONCLUSIONS. Arthroscopic wrist surgery presents a unique view of the radiocarpal ligaments. This view is not compatible with the external understanding of these ligaments that most surgeons and anatomists will have. It is therefore important to highlight these differences and continue to describe the arthroscopic view of anatomy at all levels of training.

GAMBOA, Jakob E<sup>1</sup>, Luke SANDERS<sup>2</sup>, Geoffrey DORIUS<sup>2</sup>, David A. MORTON<sup>2</sup> and Jonathan J. WISCO<sup>1,2</sup>.

<sup>1</sup>Department of Physiology and Developmental Biology, Brigham Young University, Provo, UT. 84602;

<sup>2</sup>Department of Neurobiology and Anatomy, University of Utah School of Medicine, Salt Lake City, UT 84132, USA.

Anatomical analysis of the ulnar collateral ligament in cadaveric specimens and implications for joint stability and surgical recovery.

INTRODUCTION. First performed in 1974, the Tommy John's reconstructive surgery (TJS) has become prevalent today among overhand throwing athletes. Many new techniques improving upon TJS have been developed to repair the damaged ulnar collateral ligament (UCL) of the elbow, but the results continue to vary and may not

*continued on next page*



## Abstracts - Platform Presentations continued

restore function to previous levels of performance. The orientation of the individual fibers determines the ligament's macro-architecture, and may indicate predispositions to injury and surgical outcomes. We hypothesized that the UCL has anatomical variations in the anterior and posterior bundles that may contribute to the varying incidence of UCL tears and success of TJS. METHODS: Eleven cadaveric specimens were dissected, and the anterior, posterior, and transverse bundles were visualized with light magnification and digitization. Using a MicroScribe digitizer, individual fibers for each bundle were traced in layers and reconstructed in Autodesk Maya for analysis. Caliper measurements of the length (l) and diameter (d) of the fibers at multiple levels were recorded. SUMMARY: Fibers of  $15.5 \pm 6.0$  mm (l) and  $0.09 \pm 0.03$  mm (d) comprised the bundles, with greatest geometrical variation among anterior and transverse bundles, not the posterior bundle. Five of the 11 specimens exhibited the transverse bundle extending beyond the olecranon process to the posterior surface of the medial epicondyle. CONCLUSIONS: The anterior ligament resists most valgus strain and folds in distinct patterns at elbow extension. A prominent transverse bundle elongation (45% of specimens) could provide a structural benefit when the anterior bundle reaches a position of greatest valgus strain and susceptibility to injury. During reconstruction of the UCL, this connective tissue, if present, may also be considered for replacement structures, increasing efficacy of surgery recovery.

HERRING, Nicole R., Rebecca L. BARKER, Jennifer K. BRUECKNER-COLLINS. Department of Anatomical Sciences and Neurobiology, School of Medicine, University of Louisville, Louisville, KY USA.

From grave-robbing to a willed body program: 143 years of donor history at University of Louisville.

INTRODUCTION. The University of Louisville Willed Body Program received 181 self-enrolled whole body donations in 2014 primarily consisting of Caucasian individuals and with an average age of  $79.17 \pm 0.88$  years. However, historical evidence has indicated that a majority of the whole body donations in Louisville have been from unclaimed bodies. The purpose of this study was to determine the demographic changes within the program from bodies procured from unclaimed sources to self-enrolled donors. RESOURCES. Donor information records dating from 1923 to the present from the University of Louisville Willed Body Program along with historical records from the University of Louisville Kornhauser Health Sciences Library. DESCRIPTION. At least 2 "resurrectionists" are known to have procured bodies for the 7 medical schools that existed in Louisville during the mid-to-late 1800s. By 1900, state legislature regulated the acquisition of bodies and the procurement of unclaimed bodies became the primary resource. During the first decade of written records (1923-1932), average demographics were 55.08% African-American male (AM), 21.86% Caucasian male (CM), 15.19% African-American female (AF), and 7.87% Caucasian female (CF). The average age of donors were AF  $47.57 \pm 3.07$ , AM  $50.64 \pm 1.05$ , CF  $58.64 \pm 2.27$ , and CM  $60.49 \pm 1.30$ . Bodies were acquired primarily from City Hospital, Lakeland State Hospital, Western State Hospital, and from 2 local funeral homes. The first documented self-donated body to the University of Louisville occurred in 1968. By 2014, the demographics of the donors consisted of 49.72% CF, 46.41% CM, 2.21% AM, and 1.66% AF. The average age of the donors were CF  $81.22 \pm 1.22$ , CM  $77.88 \pm 1.22$ , AF  $75.33 \pm 12.99$ , and AM  $63.50 \pm 5.98$ . SIGNIFICANCE. Over the course of the history of body donation in Louisville, significant changes have occurred in the demographics of donations likely due to the transition from unclaimed to self-enrolled body donations.

LI<sup>1</sup>, Zhi, Adel FATTAH<sup>2</sup>, Dongwoon LEE<sup>3</sup>, Nancy MCKEE<sup>1</sup>, and Anne AGUR<sup>1</sup>. <sup>1</sup>Division of Anatomy, Department of Surgery, University of Toronto, Toronto, ON M5S 1A8, Canada; <sup>2</sup>Department of Plastic Surgery, Alder Hey Children's NHS Foundation Trust, Liverpool L12 2AP United Kingdom; <sup>3</sup>Department of Computer Science, University of Toronto, Toronto, ON M5S 3G4, Canada.

A comparative 3D architectural study of the oral musculature at the fibre bundle level.

INTRODUCTION. Simulation models of oral muscles have been used for surgical planning and outcome prediction, but are limited in the accuracy of the anatomical data. In the literature, the lips and their surrounding musculature were found to be difficult to simulate largely due to a lack of detailed architectural data. Our aim was to document and quantify in 3D the fibre bundle (FB) architecture, morphology and spatial relationships of orbicularis oris and para-oral muscles. METHODS. Dissection and digitization were used to capture the FB trajectory of the orbicularis oris (OO), zygomaticus major (ZMa) and minor (ZMi), levator labii

*continued on next page*

## Abstracts - Platform Presentations continued

superioris (LLS), depressor labii inferioris (DLI), levator anguli oris (LAO), depressor anguli oris (DAO), risorius (R), mentalis (M) and buccinator (B) in 1 cadaveric specimen. The digitized data and a CT reconstruction of the skull were combined into a single model using Autodesk® Maya®. The FB trajectories and architectural parameters were quantified and compared, and symmetry of the muscles analyzed. SUMMARY. The OO had two distinct parts that did not interdigitate at the commissures of the lips. The FBs of the upper lip were superficial to those of the lower lip. The FBs of LAO and DAO interdigitated with the upper lip OO and B interdigitated with the lower lip OO. In contrast, ZMa, ZMi, LLS, DLI, M, and R attached to deep fascia surrounding the mouth. Substantial asymmetry was found in muscle shape, size and architecture. For example, a 27% difference in fibre bundle length was found between the right and left LLS and DLI and a 45% difference in ZMa physiological cross-sectional area. CONCLUSIONS. Interdigitation of OO and para-oral muscles is not global, as some muscles terminating as interdigitating fibres and others ending directly in fascia. Architectural parameters showed marked asymmetry. Many of the muscular relationships found in this study are novel, and provide a foundation for a better understanding of facial expression.

LOK, Charmaine E.<sup>1</sup>, Surendra SHENOY<sup>3</sup>, Marc GLICKMAN<sup>4</sup>, William COHN<sup>5</sup>, and Dheeraj RAJAN<sup>2</sup>. Divisions of <sup>1</sup>Nephrology and <sup>2</sup>Radiology, University Health Network, Toronto, ON M5G 2C4, Canada; <sup>3</sup>Division of General Surgery, Section of Transplantation Surgery, Washington University, St. Louis, MO 63110, USA; <sup>4</sup>Sentara Vascular Specialists, Eastern Virginia Medical School, Norfolk, VA 23507, USA; <sup>5</sup>Division of Cardiovascular Surgery, Texas Heart Institute, Baylor College of Medicine, Houston, TX 77030, USA.

### A new and lifesaving use for old, undefined anatomy.

INTRODUCTION. Most people with endstage kidney failure require life-sustaining hemodialysis. A surgical arteriovenous (AV) fistula is the preferred access between the dialysis machine and patient's circulation. However, in part due to surgical injury, 20-60% of AV-fistulas fail to mature and cannot be used for dialysis. We aimed to find suitable upper extremity anatomy to create a non-surgical, endovascular AV-fistula that may have greater maturation success and dialysis use. METHODS. We used 20 fresh frozen human cadaver arms. After thawing, we injected the brachial artery with a polymethyl methacrylate (PMMA)-based bone cement mixed with red dye and the brachial vein with PMMA mixed with blue dye; the soft tissue was then dissolved with sodium hydroxide, leaving a vascular skeleton. The vessels were visually examined to identify pairs of arteries and veins that were in consistent location and proximity to allow adequate approximation by magnetic technology to create an endovascular AV-fistula. SUMMARY. We identified in each of the 20 cadaveric arms, a short segment of the proximal ulnar artery between the brachial bifurcation and the origin of the interosseous branch that is flanked closely on either side by median and lateral ulnar veins. Here, the ulnar veins connect to the median antecubital, cephalic, and basilic veins by deep perforating branches. The distance between the short segment of ulnar artery and concomitant ulnar vein was consistently <2mm, a distance permitting magnetic approximation of these vessels for AV-fistula creation. CONCLUSIONS. Based on our cadaveric findings, we were able to identify new vasculature (artery-vein pairing) that was consistently present and within close proximity to allow for a new location to create an AV-fistula non-surgically - using endovascular magnetic and high radiofrequency ablation therapy. To date, over 50 endovascularly created AV-fistulas have been created in humans for dialysis based on this anatomic discovery.

ROQUE, Rouel, Marianna KEGEYAN-TERZIAN, Dan BOLLARD, Yehia MARREEZ, Noel GUISON, and William ROY. Department of Basic Sciences, Touro University Nevada, Henderson, NV 89014 USA.

### Group-based peer teaching with lab quizzes improve student performance in anatomy practical exams.

INTRODUCTION. The ability to identify gross structures and their relationships in cadavers is an essential objective in the medical gross anatomy course. Medical schools test anatomy competencies using traditional lab practical exams where students identify structures pre-selected and "tagged" by the faculty. To prepare our first year medical students at Touro University Nevada for the lab practical exams, we introduced a new lab activity consisting of group peer-teaching with lab quizzes (PTLQ). During the lab quiz, each dissection group is provided a set of tags to be distributed among the group members. Each student member of the group must place 1-2 "tags" independently on their assigned cadaver within a specified time interval; then, the

*continued on next page*

## Abstracts - Platform Presentations continued

placement of tags are corrected and incorporated into a single group grade. **RESOURCES.** The results of practical exams for the Posterior Abdominal Wall and Pelvic Regions (Practical Exam 1) and Head and Neck Regions (Practical Exam 2) during the spring semesters with PTLQ (2009 and 2010) or without PTLQ (2013 and 2014) were compared. **DESCRIPTION.** Students exposed to PTLQ performed significantly higher in the lab practical exams as compared with those who were exposed only to traditional dissection activities and examinations. Students who took Practical Exams 1 and 2 in the Spring Course in 2009 had means of 77.7% and 78.4%, respectively; and 75.0% and 76.7%, respectively, in 2010. Those who took the exams in 2013 achieved significantly higher means of 80.9% and 80.0%, similar to those who scored 83.0% and 81.8%, respectively, in 2014. Student surveys at the end of the school year showed ~80-85% of students preferred having PTLQ than without. **SIGNIFICANCE.** These findings support our hypothesis that group-based peer teaching and lab quizzes significantly improve student performance in traditional anatomy lab exams and could provide an effective approach towards enhancing student performance and learning in gross anatomy.

ROYER, Danielle F. Department of Cell & Developmental Biology, University of Colorado School of Medicine, Aurora, CO 80045, USA

### A new curriculum model for developing pedagogical competencies in future medical educators.

**INTRODUCTION.** There is a need for improved pedagogical training in medical education. The Advanced Teaching Experience in Gross Anatomy, a new elective in the MS Modern Human Anatomy program at the University of Colorado Anschutz Medical Campus, allows students to develop and apply pedagogical competencies through a supervised hands-on teaching experience. **RESOURCES** The elective is offered concurrently with a graduate gross anatomy course, which provides a real classroom setting in which the students practice implementing pedagogical competencies. The course employs readings, discussions, and facilitated application workshops focused on 5 areas: learning objectives, effective lecturing, assessment, evaluation, and non-didactic strategies. Students develop their own educator materials, including learning objectives, MCQs, lab demo, and 1 hour lecture, related to a predetermined regional anatomy topic. Students refine their educational materials after multiple rounds of peer, facilitator, and faculty evaluation. Presentations are video recorded to facilitate self-evaluation. Final educational materials are incorporated into the gross course offered concurrently; the classroom lecture and lab demo are also evaluated by students in the gross course. At the end of the semester, students write a paper reflecting on their progress in applying pedagogical competencies. **DESCRIPTION** The elective was piloted in 2014 and offered again in 2015. Enrollment is capped at 4 students, to allow for robust feedback and supervision across all educator activities. Preliminary evaluations suggest the course is a highly valued addition to the program, and provides a good foundation in pedagogical competencies. **SIGNIFICANCE** This course helps to develop pedagogical competencies in future gross anatomy educators. The curriculum model can be easily adapted to train future educators across anatomical sciences and other basic sciences, which may help to improve medical educator training.

SANGARI, Santosh K. <sup>1</sup>, Thomas E. HEINEMAN<sup>2</sup>, Mathew S. CONTI<sup>2</sup>, Paul-Michel F. DOSSOUS<sup>2</sup>, David J. DILLON<sup>2</sup>, Se Young PYO<sup>4</sup>, Apostolos J TSIOURIS<sup>3</sup>, Estomih P. MTUI<sup>1</sup>, Roger HARTL<sup>4</sup>. <sup>1</sup>Program in Anatomy and Body Visualization, Weill Cornell Medical College, New York; <sup>2</sup>Medical student, Weill Cornell Medical College, New York; <sup>3</sup>Clinical Radiology, New York Presbyterian Hospital, Weill Cornell Medical Center, New York; <sup>4</sup>Brain and Spine Center, Weill Cornell Medical College, New York.

### Gross and CT measurements of typical cervical vertebrae - guidelines for lateral mass screw fixation.

**INTRODUCTION.** The study was aimed at analyzing various dimensions of articular pillars of typical cervical vertebrae (C3 – C6) by Vernier calipers and computed tomography (CT) scans to develop guidelines for the selection of lateral mass screws. **METHODS.** The height, transverse, antero-posterior and oblique diameters of the cervical articular pillars were measured by Vernier calipers and on CT scans of the same set of vertebrae. The data was statistically evaluated. **SUMMARY.** The transverse diameter of the articular pillars with the help of Vernier calipers varied from 6.0 to 15.4 mm (mean=10.5 mm  $\pm$  1.5) and on CT scans ranged from 8.2 – 16.1 mm (mean=11.6 mm  $\pm$  1.4). The antero-posterior diameter of the articular pillars, an estimate of the screw length by Roy-Camille technique varied from 3.9 to 12.7 mm (mean=8.6 mm  $\pm$  1.6) by Vernier calipers and from 6.4 to

*continued on next page*

## Abstracts - Platform Presentations continued

13.3 mm (mean =  $9.1 \pm 1.2$ ) on CT scans. The oblique antero-posterior diameter of the articular pillar, an estimate of screw length by Magerl method varied from 10.8 to 20.3 mm (mean =  $14.9 \text{ mm} \pm 1.8$ ) by Vernier calipers and from 11.4 to 19.3 mm (mean =  $14.5 \text{ mm} \pm 1.7$ ) on CT scans. **CONCLUSION.** The study provides true anatomical and CT based measurements to guide surgeons in the selection of screw sizes for one of the most commonly performed spinal fixation procedures. It highlights the anatomical variance between the individuals. Although the means of the measurements correspond to the length of the screws used, but the smaller dimensions seen in relatively significant number of specimens should be kept in mind by the surgeon. The surgeons should be aware that CT measurements may overestimate the desired screw length. Careful preoperative planning and intraoperative confirmatory with X-ray visualization or CT scanning, if available are recommended.

SATO, Tatsuo. Tokyo Ariake University of Medical and Health Sciences, Koto City, Tokyo, 135-0063, Japan.  
DVD demonstration of dissection of the female pelvic lymphatic pathways to the thoracic duct: Special reference to the para-aortic chains.

**INTRODUCTION.** In function-preserving operations of female pelvic cancer, precise knowledge of the topographic anatomy, not only that of the pelvic lymphatics but also their ascending pathways along the abdominal aorta is crucial. However, due to the difficulty of dissection, demonstration of minute dissection is necessary to obtain a clearer understanding of these complex structures. **METHODS.** In a special dissection of an adult female cadaver, after removal of the hip bones, the intrapelvic blood vessels and their lymphatics and autonomic nerves were dissected. The pelvic lymphatics were traced upwards via the subaortic nodes to the abdominal aortic lymphatics to reach the thoracic duct. The process of dissection was recorded on a video and edited for the reference of students and young surgeons. **SUMMARY.** Lymphatic vessels of the pelvic organs first accompany their supplying arteries which originate from the internal iliac artery, but tend to leave them for the external iliac vessels and then ascend along the common iliac vessels to reach the aortic bifurcation area. Lymphatic chains are detected not only in front of the iliac vessels but also behind them. The paraaortic lymphatics surround the aorta and IVC, and their mutual communication is detected after the removal of these two great vessels. The paracaval lymphatics join the para-aortic lymphatics up to the level of the renal vessels and together continue to reach the thoracic duct. **CONCLUSIONS.** Such a dissection demonstration is valuable for students to obtain a full view of the abdominopelvic lymphatics and their relationships to the surrounding structures and also for surgeons for the development of future surgical techniques.

SCOLERI, Yolanda<sup>1</sup>, Shannon ROBERTS<sup>1</sup>, Anne M. AGUR<sup>1</sup>, and Nalini PATHER<sup>2</sup>. <sup>1</sup>Division of Anatomy, Department of Surgery, University of Toronto, Toronto, ON M5S 1A8, Canada; <sup>2</sup>Department of Anatomy, School of Medical Sciences, University of New South Wales, Sydney, NSW 2052, Australia.  
Architectural partitioning of gluteus medius: An in situ 3D computer modelling study.

**INTRODUCTION.** Injury to gluteus medius (GM) during total hip arthroplasty has been shown to result in pathological changes and gait disturbances. Electromyographic studies have shown that the anterior, middle and posterior regions of GM can be selectively activated during gait, suggesting that GM may be architecturally partitioned. To understand the magnitude of pathological changes, baseline knowledge of normal GM architecture is necessary. The purpose of this study was to visualize and quantify the musculotendinous architecture of GM to delineate and characterize any architectural partitions. **METHODS.** Fibre bundles and tendons of GM from 2 cadaveric specimens were dissected, digitized with a Microscribe® G2X Digitizer and modeled in 3D with Autodesk® Maya®. Architectural parameters, fibre bundle length (FBL), pennation angle (PA), physiological cross-sectional area (PCSA), and muscle volume (MV), were computed and compared to determine the presence of architectural partitioning. **SUMMARY.** GM was found to have superficial and deep heads, each with anterior, middle and posterior parts. The deep head attached to the proximal margin and the superficial head more distally via an aponeurosis to the single tendon of insertion. FBL was consistent throughout the MV. The mean PAs of the posterior parts of the superficial ( $46.6 \pm 12.8^\circ$ ) and deep ( $35.1 \pm 11.6^\circ$ ) heads were about 1.5 times greater than the anterior parts, while those of the middle parts were the smallest. In contrast, the PCSA of the anterior part of the superficial head was about 1.5 times greater

*continued on next page*



## Abstracts - Platform Presentations continued

than the posterior part; in the deep head, the difference was 3-fold. CONCLUSIONS. The differences in PCSA and PA suggest that GM consists of architectural partitions that may have different roles in dynamic stabilization of the pelvis and femoral head during gait. Further work considering the muscle-joint complex is needed to determine if such architectural differences translate to in vivo functional heterogeneity.

STERITZ, Matthew J., Lisa M.J. LEE. Modern Human Anatomy Program, University of Colorado School of Medicine. Aurora, CO, 80045, USA.

### Efficacy of undergraduate medical education in anatomical sciences for pathology residency preparation.

INTRODUCTION. Pathology is a branch of medicine that studies and diagnoses diseases at various levels ranging from gross anatomy to molecular pathways. As such, competency in pathology practice requires a comprehensive mastery in basic sciences. Because medical schools are increasingly emphasizing an integrated curriculum and decreasing the contact hours for anatomical sciences, the question remains as to the effect the new curricular design has on the preparedness of new graduates for various residency programs. We hypothesized that these changes would decrease the preparedness in new medical school graduates for pathology residency. METHODS. Two 18-item surveys were constructed; one for administrative personnel and one for residents. Both surveys were validated by three experts in the field and delivered to 102 pathology programs from around the United States using SurveyMonkey Select™. The survey participants were requested to distribute the survey to other faculty and residents in their respective programs. SUMMARY. Total of 83 respondents representing 37 pathology residency programs in the US completed the survey (36% response rate). 66.3% of the respondents were in pathology program administrative positions including program directors and instructors. 33.7% of respondents were current pathology residents in various stages of residency. The results reveal that: 1) 30% of residency program admins report a decline in the quality of interns in the past several years; 2) 8% of admins credit a post sophomore pathology fellowship (an extra anatomical sciences training in medical school) for increased intern quality; and 3) both the admin and residents identified histology and problem solving as the most valuable skills to acquire in medical school and also the skills most deficient in pathology interns. CONCLUSION. These findings call attention to the necessity for increasing basic anatomical sciences training in undergraduate medical education.

SUAMI, Hiroo, Alexander T. NGUYEN, and Edward I. CHANG. Department of Plastic Surgery, The University of Texas, MD Anderson Cancer Center, Houston, TX 77030, USA.

### Use of indocyanine green lymphography for identifying lymphatic structural changes in lymphedema.

INTRODUCTION. Lymphedema after cancer treatment can be a morbid and debilitating condition affecting the quality of life in cancer survivors. While circumferential tape measurement provides a simple objective measure of the affected limb, the difference does not necessarily correlate with severity of disease. However, in some patients, a difference may not be appreciated until the most advanced stages of lymphedema. Our clinical experience demonstrated superior outcomes when surgical intervention was performed in earlier stages prior to the onset of fibrosis. A reliable technique is needed to detect anatomical changes in lymphatic structure in asymptomatic extremities and to assess the severity of the lymphedema in later stages. RESOURCES. Surgical treatment for lymphedema including lymphovenous bypass and vascularized lymph node transfer has demonstrated promising results at our institution. Indocyanine green (ICG) fluorescence lymphography was developed for visualizing the lymphatic vessels in clinical settings. ICG lymphography was performed in 154 patients undergoing surgical treatment for lymphedema from 2009 to 2015. Control ICG images were also taken from 4 healthy volunteers. DESCRIPTION. In healthy volunteers, the lymphatic system was delineated as linear channels. The dermal backflow pattern, which represents reflux to the lymph capillaries in the dermis, was only seen in lymphedematous limbs. The dermal backflow area was correlated with the symptomatic area detected on physical examination. SIGNIFICANCE. The ICG lymphography can provide real-time imaging of the structure of the lymphatic system. This is a useful device for evaluating lymphedema allowing clinical grading of the severity of lymphedema based on the degree and distribution of dermal backflow noted on lymphography.

## Abstracts - Platform Presentations continued

SUAMI, Hiroo, Department of Plastic Surgery, The University of Texas, MD Anderson Cancer Center, Houston, TX 77030, USA.

The lymphosome concept: comparative morphology for a better understanding of the sentinel node.

**INTRODUCTION.** The sentinel lymph node biopsy technique has become the standard of care for staging in breast cancer and melanoma patients. While lymphoscintigraphy is useful in identifying the sentinel lymph nodes, its resolution is insufficient to trace the lymphatic vessel, and the gross anatomy of the lymphatic system remains poorly studied. The present study aims to describe the lymphatic anatomy in humans and animals which can serve as models for advancing clinical applications and understanding of the lymphatic system in patients. **RESOURCES.** Our novel microinjection technique enabled us to inject radiocontrast medium into each lymphatic vessel under a microscope and to delineate the lymphatic anatomy on radiographs and computed tomographic images. Radiographic imaging was performed in fresh non-embalmed cadavers. Identical imaging studies were performed in vivo in a rat, rabbit, canine, and swine model. Indocyanine green (ICG) fluorescent lymphography was also used to trace the lymphatic vessels and lymph nodes prior to dissection of human and animal cadaveric specimens. **DESCRIPTION.** We were able to map the lymphatic vessels and lymph nodes in animals and cadavers by using ICG lymphography and radiographic microinjection technique. We color-coded them in correspondence with their sentinel nodes. The color-coded lymphatic vessels revealed that the superficial lymphatic system could be divided into skin territories, namely, "lymphosomes." **SIGNIFICANCE.** The lymphosome concept may help with an accurate prediction of cancer metastasis. Comparison of the lymphosomes between animals and humans will be valuable for future lymphatic research.

SUNDERLAND, Michael J.<sup>1</sup>, Tom IWAN<sup>1</sup>, James HAMIL<sup>2</sup>, and S. Ali MIRJALILI<sup>1</sup>. <sup>1</sup>Department of Anatomy with Radiology, Faculty of Medical and Health Sciences, University of Auckland, Auckland, New Zealand; <sup>2</sup>Department of Paediatric Surgery, Starship Hospital, Auckland, New Zealand.

Neonatal anatomy of the mediastinal structures at the level of the manubriosternal angle.

**INTRODUCTION.** Anatomical planes used in clinical practice and teaching anatomy have previously been revisited in vivo in adults using computed tomography (CT) imaging techniques. Neonatal surface anatomy has never been visited, and so best practise is to assume the same surface anatomy as adults. The aim of this study was to investigate the sternal angle in neonatal populations using CT imaging. **METHODS.** High resolution thoracic CT scans of neonates aged between 0-2 years old from Starship Hospital were analyzed using dual consensus reporting. The vertebral level and the structures found at the sternal angle; the concavity of the aortic arch, azygos vein draining to superior vena cava (SVC) and tracheal bifurcation were evaluated. Patients with distorting space-occupying lesions and congenital disorders were excluded. **SUMMARY.** Among 50 thoracic CT scans (mean age 6 months, 55% female), the preliminary results show that the vertebral level of the sternal angle was considerably higher on average in neonates than adults. 40% of cases were found at T2/T3 intervertebral disc or the upper half of T3. The concavity of the aortic arch, azygos vein draining to superior vena cava (SVC) and tracheal bifurcation were a mean of 10±4mm, 10±2mm and 15±6mm below the level of the sternal angle, respectively. **CONCLUSIONS.** Surface anatomy of neonatal anatomical planes needs revisiting in the light of results from living subjects. Knowing that there are fundamental structural anatomical differences between adult and neonatal populations, current lack of evidence-based knowledge of neonatal surface anatomy may fail to ensure safety and success among neonatal patients undergoing clinical procedures.

VAN SCHOOR Albert-Neels<sup>1</sup>, Marius C BOSMAN<sup>1</sup>, and Adrian T BOSENBERG<sup>2</sup>. <sup>1</sup>Department of Anatomy, School of Medicine, Faculty of Health Sciences, University of Pretoria, Pretoria, South Africa; <sup>2</sup> Department of Anesthesiology and Pain Management, University of Washington and Seattle Children's Hospital, Seattle, USA. Revisiting the anatomy of the ilio-inguinal/iliohypogastric nerve block.

**INTRODUCTION.** The ilio-inguinal/iliohypogastric nerve block (INB) is one of the most common peripheral nerve block techniques in pediatric anesthesia, which is largely due to the introduction of ultrasound (US) guidance. Despite the benefits of US guidance, the absence of an US machine should not deter the provider

*continued on next page*



## Abstracts - Platform Presentations continued

from performing INB, considering that many institutions, especially in developing countries, cannot afford to provide ultrasound machines in their anesthesiology departments. The aim of this study was to revisit the anatomical position of the ilio-inguinal and iliohypogastric nerves in relation to the anterior superior iliac spine (ASIS), in a large sample of neonatal cadavers, and compare the results with a similar group in a previously published US-guided study. **METHODS.** With Ethics Committee approval, the ilio-inguinal and iliohypogastric nerves were carefully dissected in 54 neonatal cadavers. **SUMMARY.** In the total sample, the ilio-inguinal nerve was found to be  $2.2 \pm 1.2$  mm from the ASIS, on a line connecting the ASIS to the umbilicus. The iliohypogastric nerve was on average  $3.8 \pm 1.3$  mm from the ASIS. For the entire sample, the optimal needle insertion site was 3.00 mm from the ASIS. Although there is a strong correlation between the needle insertion point and the weight of the neonate, this will only 'fit' for 60% of the population. **CONCLUSION.** The linear regression formula; needle insertion distance (mm) =  $0.69 \text{ weight} + 1.8$  can be used as a guideline for the position of the ilio-inguinal and iliohypogastric nerves.

## Abstracts – Tech Fair Presentations

(listed by presenting author last name)

MACPHERSON, Brian R.<sup>1</sup>, and Jennifer K. BRUECKNER-COLLINS<sup>2</sup>. <sup>1</sup>Anatomy and Neurobiology, University of Kentucky College of Medicine, Lexington, KY 40536; <sup>2</sup>Anatomical Sciences and Neurobiology, University of Louisville School of Medicine, Louisville, KY 40202, USA.

Development of a programmed learning tool for an innovative approach to the laboratory component of dental gross anatomy.

**INTRODUCTION.** North American dental schools exhibit very dense curricula in years one and two that many students have trouble navigating academically. New schools, and some schools with new curricula, have reduced or eliminated the dissecting laboratory component of dental gross anatomy – without any noticeable effect on their board scores. We remain committed to the basic principle of the value of the laboratory in establishing a 3-dimensional understanding of the components of dentally-relevant areas in head and neck anatomy that studying 2-dimensional images cannot impart. **RESOURCES and DESCRIPTION.** The head and neck section of the dental gross anatomy laboratory was reconstructed into modules organized into a proven programmed learning tool format. We present a fully functional module for the infratemporal fossa demonstrating the incorporation of a series of learning enhancements harnessed into a programmed learning format that is composed of two sections. The first is a step-wise, chronological, description of the dissection of the area, including line drawings, dissection video-clips, still images of the various stages of dissection and an accompanying linear schematic of structures found moving superficial to deep. Periodic formative assessment with feedback is seamlessly integrated into this section. The second component is completion of viewing a series of prosections representing the stages of dissection outlined in the programmed component - complete with clinical applications. This series must be completed in a chronological, superficial to deep order. **SIGNIFICANCE.** It is clear that dissecting the head and neck does not reflect in better board scores, but we strongly feel it will enhance the clinical experience - for both student and patient - if they have a 3-dimensional understanding of clinically-relevant areas of the head and neck. The format developed will increase the time efficiency needed to master these complex regions.

*continued on next page*

## Abstracts - Tech Fair Presentations continued

LEE, Lisa M.J., Oana ROSENTHAL, Jessica KAHL. Department of Cell and Developmental Biology, University of Colorado School of Medicine. Aurora, CO, 80045, USA.

### Quantitative assessments on achieving histology competency; first-step toward evidence-based education.

INTRODUCTION. A recently developed virtual histology lab that features instructor-simulation tools such as interactive annotations and game-based quizzes have been shown to enhance histology learning and retention compared to a conventional virtual lab. In order to maximize the educational value of the instructor-simulation tools on the new virtual lab, it is important to quantitatively assess exactly how students learn pattern-recognition skills on virtual slides. The objective of the study was to elucidate how learning takes place in a visually oriented subject such as histology. METHODS. Fourteen first year graduate students enrolled in a histology course were recruited. Using an eye-tracking device, the recruits' eye-movements while viewing the new virtual lab during passive (identification-quiz) and active (tasked to find structures) interactions were recorded and analyzed for emerging patterns across time and evolving level of expertise. The same data points were collected for five second year students who completed the course a year previously, and three histology experts for comparison. SUMMARY. The results show that all first-year students decreased both passive- and active-task completion time, and demonstrated increases in pattern recognition skills as the course progressed. With increasing skills, the eye-movement patterns of the first year students approached those of the experts and matched the experts' key areas of focus. Quantitative analyses revealed that expert level pattern recognition skills were characterized by longer saccadic eye-movements over key areas of interest, and overall, faster recognition of tissue or structure identity. CONCLUSION. By extracting key areas of interest and elucidating quantitative pattern of the most effective way of approaching histological tissues, the instructor simulation tools can be customized, based on evidence, to yield effective learning.

SRIVASTAVA, Sakti, Matt HASEL, Sarah HEGMANN, Joe LANG, Leslie WHITE, Ian WHITMORE. Division of Clinical Anatomy, Stanford School of Medicine, Stanford CA 94305 USA.

### The role and value of highly customized 3D models in the anatomy curriculum.

INTRODUCTION. Anatomy courses for medical students are constrained in time due to the reduction in available curriculum hours. In order to present all relevant curricular content efficiently, the use of highly customized 3D models was explored. RESOURCES. A library of anatomical 3D models created in the division using Maya can be displayed using our in-house 3D model viewer. This viewer uses the Unity gaming engine and can be deployed on iPads and accessed online through a web browser. For each lecture in each body region the requisite anatomical parts of the 3D model are made available in a customized scene. For each following lecture an additional customized scene is added to the model, tailored for that specific lecture. Scenes for previous lectures continue to be available alongside sequentially added new scenes. At the end of the anatomical region being taught, all individual lecture scenes are accompanied by the complete 3D model for that region. DESCRIPTION. All 3D model scenes were made available to our students through our university-wide Learning Management System for use in a self-study mode. For some topics that were particularly difficult to orientate the model was also shown during the lecture. The 3D model viewer was also available during all lab session on pre-loaded iPads stationed alongside their cadaver dissection table. Initial informal responses suggest that the students appreciate the close match between anatomical structures described in lecture, dissected in the lab and depicted in the 3D model. We are currently collecting further objective data to further study and quantify this view. SIGNIFICANCE. The use of highly customized 3D models enhances the efficient delivery of information, which, in turn, improves student learning. The close match of anatomical data between the lecture, lab and model provides a rich learning experience.

# Abstracts – Poster Presentations Session 1

(listed by presenting author last name)

ABDEL MEGUID, Eiman M.<sup>1</sup>, and Amany E. AGAWANY<sup>2</sup>. <sup>1</sup>Centre of Biomedical Sciences Education, Queen's University Belfast, BT7 1NN, United Kingdom; <sup>2</sup>Department of Anatomy, Faculty of Medicine, University of Alexandria, Egypt

An anatomical study of the arterial and nerve supply of the infrahyoid muscles.

INTRODUCTION. Infrahyoid myocutaneous flap is of interest in head and neck reconstruction surgery given its versatility, and the quality of its cosmetic results. It represents the golden standard for reconstruction of extensive defects after resection of cancer. There are no sufficient references on the arterial supply to infrahyoid muscles. This information would be beneficial to improve the quality of surgical reconstructions as it will aid surgeons in planning their operations. METHODS. Fourteen cadavers were unilaterally dissected. The cadavers were injected with red latex. The cervical arterial pedicle, and the neural supply of the sternohyoid (SH), sternothyroid muscle (STM) and superior belly of omohyoid (OM) were identified. The superior thyroid artery (ST) and ansa cervicalis (AC) were examined as they are the main supply for the infrahyoid myocutaneous flap. The length of the arterial pedicles was measured to evaluate their potential application in reconstructive surgery. SUMMARY. For the SH, two arterial pedicles originated from the ST and supplied it in 57.1%. The inferior pedicle was absent in 42.9%. As regards the STM, one arterial pedicle from the ST supplied its upper end in 57.1% of cases. In 14.3% of cases, the inferior thyroid artery also supplied it. As regards OM, two arterial pedicles originated from the ST and supplied its upper and lower ends in 64.3% of cases. SH usually had a double nerve supply from AC. In 57.1% of cases, its superior part was innervated by the nerve to the superior belly of OM. In 35.7% of cases, it received direct branches from AC. As regards STM, in 71.4% of cases, a common trunk arose from the loop and supplied the inferior part of both the SH and STM. The nerve supply to superior belly of OM originated from the AC below the loop. CONCLUSIONS. These data will be useful for surgeons as precise knowledge of the location of vascular pedicles is required for the successful transposition of a myocutaneous flap.

AVONDET, McKay R.<sup>1</sup>, Tanner GRAY<sup>1</sup>, Adam JORGENSEN<sup>1</sup>, and Jonathan J. WISCO<sup>1,2</sup>. Brigham Young University, Provo UT 84602, USA; <sup>2</sup>University of Utah School of Medicine, Salt Lake City, UT 84132, USA.

Analysis of rotator cuff muscle attachments in the late cocking and follow through phases of baseball pitching on cadaveric specimens.

INTRODUCTION. Previous research mapped the fibers of the rotator cuff muscles from proximal to distal attachment sites of two different cadaveric specimens in anatomical position. This allowed us to visualize the anatomy of the muscles overlaid on a 3D Magnetic Resonance Imaging (MRI) reconstruction in great detail. The next step of our research involved mapping the muscles of the rotator cuff in dynamic positions, particularly in the late cocking phase and the follow-through phase of the baseball pitching motion, as these phases are believed to place the greatest force on the shoulder in pitchers. RESOURCES. We performed a structural T1 and T2 MRI on a shoulder specimen for the creation of a 3D reconstructed bony template of the scapula and humerus. We then exposed the supraspinatus (SS), infraspinatus (IS), teres minor (TM), and subscapularis (sub) muscles in two additional unembalmed specimens. We created external fixation devices to place these specimens in either the late cocking phase or follow-through phases. Specimens were fixed in 10% formaldehyde solution for one month. DESCRIPTION. Muscle fibers were mapped using a 3D MicroScribe tool and virtual models were reconstructed in Autodesk Maya. We overlaid and registered the MicroScribe data onto the 3D reconstructed shoulder model in both the late cocking and follow-through phases of pitching. SIGNIFICANCE. The complexity of attachments in fixed dynamic positions provide a unique anatomical view to inform the understanding of rotator cuff injuries. A next step in our research will be to test whether our models can predict the forces placed on the rotator cuff muscles in the baseball pitching motion, and if the results can inform or improve therapeutic and orthopedic approaches to rotator cuff injuries.

*continued on next page*

## Abstracts - Poster Presentations Session 1 continued

BOSMAN Marius C.<sup>1</sup>, Lané PRIGGE<sup>1,2</sup>, Adrian T. BOSENBERG<sup>3</sup>, and Albert-Neels VAN SCHOOR<sup>1</sup> <sup>1</sup>Department of Anatomy, School of Medicine, Faculty of Health Sciences, University of Pretoria, Pretoria, South Africa.

<sup>2</sup>Department of Anatomy, Sefako Magkatho Health Sciences University, Garankuwa, South Africa, <sup>3</sup>Department of Anesthesiology and Pain Management, University of Washington and Seattle Children's Hospital, Seattle, USA.

### Evaluation of the pediatric maxillary nerve block.

INTRODUCTION. Anatomical landmarks in children are mostly extrapolated from studies in adults, yet regional anesthetic procedures are frequently performed on pediatric patients. Sophisticated imaging techniques are available but the exact position, course and/or relationships of the structures are best understood with appropriate anatomical dissections. Maxillary nerve blocks are being used for peri-operative analgesia after cleft palate repair in infants, although the best approach for this nerve block has yet to be established.

METHODS. In an attempt to define an optimal approach for maxillary nerve block in this age group, three approaches were simulated and compared on 24 dried pediatric skulls as well as 30 dissected pediatric cadavers. The needle course, depth and angles to block the maxillary nerve, as it exits the skull at the foramen rotundum within the pterygopalatine fossa, was measured and compared. SUMMARY. No statistically significant difference ( $p > 0.05$ ) was found between the left and right side of each skull or cadaver. Only the supra-zygomatic approach from the frontozygomatic angle towards the pterygopalatine fossa (method B) exhibited no statistical significance when other measurements made on the skulls and cadavers were compared. Method A, a supra-zygomatic approach from the midpoint on the lateral border of the orbit, as well as method C, an infra-zygomatic approach with an entry at a point on a vertical line extending along the lateral orbit wall, showed statistical significant differences during measurement comparison. CONCLUSION. On the basis of these findings method B produces the most consistent data and supports the clinical findings recently reported.

BUSCH, Kyle J., and Anthony B. OLINGER. Department of Anatomy, Kansas City University of Medicine and Biosciences, Kansas City, MO 64106, USA.

### Pterygospinous and pterygoalar ligament presence as an etiology of trigeminal neuralgia.

INTRODUCTION. The characteristics of the pterygoalar and pterygospinous ligaments in the infratemporal fossa have been extensively documented in studies using dried crania and, to a much lesser extent, cadavers. Researchers have hypothesized about the potential role these ligaments may play in the entrapment of nearby neurovasculature resulting in facial neuralgias, more specifically trigeminal neuralgia. The purpose of this cadaveric study was to characterize the ligaments, their relation to the local neurovasculature, and determine whether or not the presence of a ligament was associated with neuralgia symptoms using patient history. METHODS. Measurements were taken by 2 individuals on 54 cadavers. Our specimens were divided into three groups: no ligament, pterygoalar ligament, or pterygospinous ligament. A living relative of those cadavers with a pterygospinous ligament were then contacted and asked to complete a trigeminal neuralgia questionnaire pertaining to their loved one. SUMMARY. Pterygospinous ligaments were found in 11 cadavers (20%), 3 of which were ossified. No pterygoalar ligaments were present in our cadaver population. Of the individuals contacted, none indicated that their loved one had ever suffered from trigeminal neuralgia or symptoms relating to facial neuralgia pathology. CONCLUSIONS. The pterygospinous and pterygoalar ligaments will continue to draw attention for their significance in anesthesia and surgical procedures. However, the presence of a pterygospinous ligament is less likely a culprit of producing compression neuralgias than previously hypothesized. More research needs to be done to identify an etiology of trigeminal neuralgia in those refractory to traditional medical interventions.

## Abstracts - Poster Presentations Session 1 continued

CESMEBASI, Alper<sup>1,2</sup>, and Robert J SPINNER<sup>1</sup>. <sup>1</sup>Department of Neurologic Surgery, Mayo Clinic, Rochester, MN 55905; <sup>2</sup>Department of Anatomical Sciences, St George's University, Grenada, West Indies.

Medicolegal strategies for iatrogenic spinal accessory nerve injury after prior surgery: An anatomic based approach.

INTRODUCTION. Iatrogenic spinal accessory nerve (SAN) injury is a well-described complication of surgical procedures in the posterior cervical triangle. It is most commonly associated with cervical lymph node biopsy, affecting 3-6% of patients, and serves as a major cause of avoidable medical malpractice litigation. Medical malpractice cases not only affect the primary surgeon but also may include the repairing surgeon through a shift of blame. For this reason, we discuss the strategies all clinicians may utilize in approaching iatrogenic SAN injuries. RESOURCES. A literature review of SAN anatomy, iatrogenic injuries, and medical malpractice was done to compile a compendium of information. Experiences from a peripheral nerve surgeon who treats iatrogenic nerve injury cases were taken into account to formulate management strategies for iatrogenic SAN injuries. DESCRIPTION. Utilizing the compilation of information and experiences, we were able to formulate basic strategic steps based in the management of iatrogenic SAN injury patients for all clinicians. SIGNIFICANCE. Taking basic precautionary measures based on simple application of anatomy in the management of iatrogenic SAN injury patients, clinicians protect themselves from needless malpractice litigation. These strategies may provide guidance for clinicians for prevention of iatrogenic injuries, what to do when accidental injuries occur, and ensures the treating surgeon is not at fault if litigation is pursued.

COLLINS, James D, Ernestina H SAXTON, Hugh GELABERT, Alfred CARNES. Department of Radiological Sciences, David Geffen School of Medicine, University of California, Los Angeles, Los Angeles, CA 90024, USA. Botox injections into the scalene triangle compromises thoracic outlet syndrome (TOS) patients as displayed by MRI, MRA, MRV.

INTRODUCTION. Bilateral multiplanar magnetic resonance imaging and 2D time of flight magnetic resonance angiography and venography (MRA/MRV) of the brachial plexus display costoclavicular compression of the draining veins within the neck, supraclavicular fossae, and neurovascular bundles as the diagnostic cause of thoracic outlet syndrome. METHODS. Bilateral MRI/MRA/MRV displays sites of obstruction of the draining veins of the neck and the subclavian and axillary arteries with binding nerve roots. Monitored multiplanar images were acquired on a 1.5 Tesla GE Signa LX unit, 44 cm field of view, 512 x 256 matrix and saline water bags to enhance signal to noise ratio.

SUMMARY. Thoracic Outlet Syndrome (TOS) patients are normally managed conservatively with physical therapy (PT) and may undergo scalenectomy and first rib resection when PT fails. Other patients alternatively select Botox injections for relief of pain and muscle spasms. CONCLUSIONS. In our TOS patients' post-Botox injection, some developed difficulty in swallowing, loss of upward gaze, increase rounding of shoulders, and progressive loss of upper extremity mobility, complicating their management.

COLVIN, Lacey D., Nicholas C. ELWERT, and Natalie R. SHIRLEY. Anatomy Department, Lincoln Memorial University-DeBusk College of Osteopathic Medicine, Harrogate, TN 37752, USA. Secondary pathologies of clavicle fractures: length discrepancies and osteoarthritic changes.

INTRODUCTION. This study examines boney pathological changes associated with clavicle fractures, specifically length discrepancies and osteoarthritic changes at the acromioclavicular (AC) and sternoclavicular (SC) articulations. METHODS. Fifty-five individuals with conservatively treated clavicle fractures were compared to 55 individuals without fractures from the University of Tennessee McCormick Clavicle Collection. Maximum clavicle length was measured bilaterally. Absolute and percentage differences in length were calculated for fractured and control samples. Osteophytic lipping on the superior and inferior AC and SC joint

*continued on next page*



## Abstracts - Poster Presentations Session 1 continued

margins was scored as absent, present/minimal-moderate, or present/severe. Marginal homogeneity tests were used to evaluate asymmetry in lipping in the control and fracture samples. SUMMARY. Mean absolute difference between the fractured and paired non-fractured clavicle was 6.17mm, or 5.72% of non-fractured clavicle length; the fractured clavicle was typically shorter than its non-fractured counterpart. Mean absolute difference of the controls was 0.18 mm (1.88% difference); the left clavicle is typically longer than the right. Significant differences in bilateral expression of osteophytic lipping were detected at the superior ( $p<.001$ ) and inferior ( $p=.039$ ) AC joint margins in the fractured group. A compensatory pattern of osteophytic change was noted, with the majority occurring on the paired non-fractured clavicle. The majority of lipping on the SC joint occurred on the inferior aspect of the joint, rather than the superior aspect. Bilateral differences in degree of lipping were also significant at the superior AC joint margin in the control sample ( $p=.002$ ). CONCLUSIONS. Significant length discrepancies exist in individuals with clavicle fractures, as well as a trend of compensatory contralateral osteophytic changes. These secondary pathologies indicate a pattern of compensation that could portend somatic dysfunction.

D'ANTONI, Anthony V<sup>1</sup>, and Carlos A. G. MACHADO<sup>2,3,4</sup>. <sup>1</sup>Department of Pathobiology, The Sophie Davis School of Biomedical Education, The City College of New York, CUNY, New York, NY 10031, USA; <sup>2</sup>Medical Illustrator, Austin, TX 78759, USA; <sup>3</sup>Department of Pathophysiology, The University of Saint Augustine for Health Sciences at Austin, Austin, TX 78739, USA; <sup>4</sup>Department of Cellular and Structural Biology, The University of Texas Health Science Center at San Antonio, San Antonio, TX 78229, USA.

Medical illustration highlighting the 3D morphology of the temporomandibular joint articular disc.

INTRODUCTION. The articular disc of the temporomandibular joint (TMJ) has often been depicted solely in the sagittal plane in anatomy atlases to highlight the relationship of the disc to the upper and lower joint spaces. Such depictions do not highlight the relations of the disc to the various soft-tissue structures that attach to it and do not give the observer an understanding of the function of the disc and how it maintains its shape as forces pass through it during mandibular movement. RESOURCES. We examined several popular anatomy atlases and found no three-dimensional (3D) illustration of the disc. In fact, all of the illustrations depicted the disc in the sagittal plane. DESCRIPTION. Using data from an original research study that investigated the 3D morphology of the disc and biofidelic plastic models, several illustrations were created using graphite (basic drawing) and digital colorization. These illustrations emphasize the complex 3D morphology of the disc and its bony and soft-tissue relations. SIGNIFICANCE. These illustrations better depict the 3D morphology of the disc and can help anatomists and clinicians better understand the functional aspects of the TMJ.

DEWAN, Dale, and Sherif HASSAN. A. T. Still University, Missouri School of Dentistry and Oral Health, Kirksville College of Osteopathic Medicine, Kirksville, MO 63501, USA.

A cadaver study of the Gow-Gates nerve block technique approximation to the maxillary artery and inferior alveolar nerve.

INTRODUCTION. The Gow-Gates nerve block (GGNB), a technique given to anesthetize the inferior alveolar nerve (IAN) for dental mandibular procedures, is based on the "textbook" courses of the IAN and maxillary artery (MA) in the infratemporal fossa (ITF). Though the GGNB is reputed to have low aspiration rates, the reported high variability of the MA course and the technique parameters appear to indicate a higher incidence of contact could occur. The purpose of this study was to determine if the needle tip of the GGNB is closer to the MA than the IAN. METHODS. A 25 gauge needle was inserted using the GGNB into 42 half-heads of human cadavers with the ITF dissected. The distance of the needle tip to the MA and IAN was measured. The mean distance for each was determined. These measurements were categorized to determine if left and right side variability within the same cadaver is predictably small compared to variability between cadavers. SUMMARY. The mean distance from the needle tip to the MA was 5.9 mm and the IAN was 7.1 mm. There was no significant difference in the variance of the left and right side within the same cadaver when compared to the

*continued on next page*



## Abstracts - Poster Presentations Session 1 continued

variance between cadavers. Since the MA supplies blood to structures of the cranium and face, care should be taken to prevent vascular damage and or intravascular injection. CONCLUSIONS. The GGNB technique deposits anesthetic closer to the MA than its intended target, the IAN. The reported MA variations make reliable avoidance of the MA problematic using the GGNB. Understanding the approximate MA location on one side of an individual is not a reliable indicator of MA location on the other side. Further study, including needle insertion contacts to the MA and maxillary vein and live human studies is needed to determine if modification of the GGNB warrants consideration.

IWANAGA Joe<sup>1,2</sup>, Tsuyoshi SAGA<sup>1</sup>, Yoko TABIRA<sup>1</sup>, Sadaharu KITASHIMA<sup>1,2</sup>, Koichi WATANABE<sup>1</sup>, Jingo KUSUKAWA<sup>2</sup>, Koh-ichi YAMAKI<sup>1</sup>. <sup>1</sup>Department of Anatomy, Kurume University School of Medicine, Kurume, Fukuoka, 830-0011, Japan; <sup>2</sup>Dental and Oral Medical Center, Kurume University School of Medicine, Kurume, Fukuoka, 830-0011, Japan.

### Anatomic and radiologic correlation of accessory mental foramina and nerves.

INTRODUCTION. It is generally known that there is one mental foramen on each side in a human mandible. Accessory mental foramina (AMFs) are defined as foramina occasionally located near the mental foramen, with continuity with the mandibular canal, and from which nerves and/or arteries may emerge. AMFs have received more attention since three-dimensional computed tomography developed and began to reveal them. However, there have been few reports of the accessory mental nerves (AMNs) deriving from the AMFs. In this study, we investigated the AMNs and AMFs anatomically and radiographically. METHODS. In 2014, 31 mandibles with overlying soft tissues isolated from cadavers donated to our laboratory were examined by micro computed tomography (mCT). As a result, we identified three mandibles which had AMFs. They were investigated using cone-beam computed tomography (CBCT). We also dissected the overlying soft tissues using gross anatomical methods with the aid of a stereomicroscope. We compared mCT and CBCT images to anatomical findings. SUMMARY. There were differences among observation results by mCT, CBCT, and gross anatomical methods. The total number of AMFs found using mCT and gross anatomical methods was larger than the number revealed using CBCT. This may be due to differences of the resolution between mCT and CBCT. In addition, gross anatomical dissection could reveal the small AMFs and also reveal nerves and/or arteries emerging from those foramina. Outside of gross anatomical dissection or surgery in the clinical setting, there is no way to identify the structures emerging from AMFs. CONCLUSIONS. These results should be taken into consideration for preoperative diagnosis. Further studies in gross anatomy and radiology of the mental regions are needed.

KAUTZ, Mandalyn J. and Anthony B. OLINGER. Department of Anatomy, Kansas City University, Kansas City, MO 64106, USA.

### The internal carotid artery, oculomotor, trochlear, ophthalmic, maxillary and abducens nerves in relation to the cavernous sinus.

INTRODUCTION. Previous research suggests the oculomotor, trochlear, ophthalmic, maxillary and abducens nerves (cranial nerves III, IV, V1, V2, and VI) and the cavernous portion of the internal carotid artery (ICA) pass through the cavernous sinus (CS) with different positional relationships between each of these structures. Based on the disparity of anatomical representations portraying the CS, the objective of the study was to clarify relationships of the major structures contained within. RESOURCES. The craniums of 20 female and 23 male totaling 43 adult embalmed cadavers were utilized for dissection. The aforementioned cranial nerves were identified along with the ICA after removing the pituitary gland from the sella turcica and dissecting medial to lateral through the CS. DESCRIPTION. Oculomotor, trochlear, ophthalmic, and maxillary nerves were found within leptomeninges in descending order superomedial to inferolateral in the lateral wall while the ICA and abducens nerve were located within the CS independent of the arachnoidal and dural sheath. It is important to note the abducens nerve was found inferolateral relative to the ICA often loosely adhered to the vessel. SIGNIFICANCE. Due to the position of the abducens nerve, it may be more vulnerable to injury in

*continued on next page*

## Abstracts - Poster Presentations Session 1 continued

comparison to the nerves located within the lateral wall when the CS is compromised. The findings of the study may be applied when considering neoplasms, infection, microsurgery, sella enlargement and other clinical pathology which warrant an understanding of the gross anatomy of the cavernous sinus.

KUM, Jason M., Laura C. BARRITT, William J. PUETZ, Sonia M. SANCHEZ, Shikha TARANG, and Barbara J. O'KANE. Department of Oral Biology, School of Dentistry, Creighton University, Omaha, NE 68178, USA.

### Determination of Expression of TREM-1 and TREM-2 in Oral Keratinocytes.

**INTRODUCTION.** Chronic periodontitis is an inflammatory disease of the supporting tissues of the teeth caused by microorganisms. This oral disease induces a systemic inflammatory response and increases the risk of developing cardiovascular disease. TREM-1 and TREM-2 are receptors that propagate an inflammatory response due to bacteria. Studies have identified TREM-1 and TREM-2 modulation in hematopoietic tissue and lung airway cells during chronic inflammation, but current research is unclear of their role in the oral cavity. The purpose of this study is to determine if TREM-1 and TREM-2 are expressed in gingival keratinocytes and if it can be differentiated in the gingiva of normal healthy patients versus those with periodontitis. **METHODS.** Gingival samples were obtained from discarded teeth of patients from Creighton University School of Dentistry. Western blot analysis was performed on 22 samples using a primary antibody, mouse-anti  $\beta$ -actin, and a secondary antibody anti-rabbit and anti-mouse for TREM-1 and TREM-2 protein expression. Semi-quantitative PCR assay was performed on the same samples using SYBR green. Amplification was performed using primers set specific for TREM-1 and TREM-2 genes and normalized to endogenous  $\beta$ -Actin using StepOne Software. **SUMMARY.** The data from Western blot suggested an increase in TREM-1 expression in healthy tissues, while TREM-2 expression was elevated in periodontitis samples. Interestingly, the qPCR results showed upregulation of TREM-2 in healthy tissue while TREM-1 expression is increased in periodontal samples. **CONCLUSIONS.** Both TREM-1 and TREM-2 can be identified in oral gingiva. The results from the Western blot and qPCR were inconclusive regarding differential expression of these proteins when comparing perio versus healthy tissue. Increasing sample size should help to determine if there is a statistically significant difference between the amounts of transcript and protein found in normal versus perio gingival tissue.

LEE, Vaughan H, Christian BEZBORUAH, Carlos MARTINEZ, Fahmida MUSHAROF, Christine RIDDLE, and Phuong TRINH. Texas Tech University, Department of Medical Education, Lubbock, TX 79430, USA.

### Bilateral agenesis of the facial arteries: compensation by inferior transverse facial arteries.

**INTRODUCTION.** Anatomical variations are emphasized in the dissection laboratory with reference to clinical relevance. Variations that alter anatomical landmarks or the position of critical structures may impact the physical examination or endanger structures during surgery. Common variations receive much attention; however, rare variations are not well emphasized, yet may have important clinical relevance. **RESOURCES.** Bilateral agenesis of the facial arteries was observed in an eighty-year-old male donor. Following bisection and dissection of the head and neck regions, the course and branching of the external carotid arteries were evaluated. **DESCRIPTION.** Both external carotid arteries branched at the level of the hyoid bone and gave rise to typical branches including the lingual arteries. Submental arteries arose from the lingual arteries, although no arteries following the traditional path of the facial over the mandible were observed. The occipital and posterior auricular branches arose from the external carotid arteries which ended by trifurcation into superficial temporal, maxillary, and inferior transverse facial arteries. The inferior transverse facial arteries traversed the surfaces of the masseter muscles to pass anteriorly, providing labial branches before terminating lateral to the nose as angular arteries. **SIGNIFICANCE.** Although of no apparent pathological consequence to the donor, this anomaly could have presented in clinical encounters, including the lack of a facial artery pulse over the mandible just anterior to the masseter or the presence of a significantly sized artery in the surgical field superficial to the masseter muscle. This case of bilateral facial artery agenesis highlights the value of not only emphasizing common anatomical variants during dissection, but also instructing future anatomists and surgeons to remain cognizant of those variations that may not be so common.

*continued on next page*

## Abstracts - Poster Presentations Session 1 continued

MAHDI, Ali, Zhi LI, Shannon ROBERTS, and Anne AGUR. Division of Anatomy, Department of Surgery, University of Toronto, Toronto, ON M5S 1A8, Canada.

### Illustration of the mylohyoid muscle: a historical overview.

INTRODUCTION. The mylohyoid muscle (MH) is thought to have an integral role in elevating the hyoid bone during swallowing. However, it is evident from the current literature that we still do not fully understand the precise role of MH in the swallowing process. Since the 16th century, illustrations depicting MH morphology have evolved in parallel with our knowledge of anatomy and physiology, through dissection of the human body. The purpose of this study was to review illustrations of MH from the 16th century to the present day to enhance our understanding of MH morphology from a historical perspective. RESOURCES. Illustrations of MH by Da Vinci, Vesalius, Bildoo, Guido, Spiegel, Eustachi and Bourguery were reviewed using plates from the Thomas Fisher Rare Books Library at the University of Toronto, and compared with dissections, modern illustrations and three-dimensional computer models of the muscle as in situ. DESCRIPTION. The MH has evolved from being depicted as a flat sheet to a 3D structural entity. Initially, the MH was illustrated as horizontal fiber bundles lying between the inferior borders of the mandible with no raphe or hyoid attachment. Subsequently, a stylistic linear raphe was added with extremely oblique fiber bundles extending to the mandible. The hyoid attachment was included. Later, the raphe and orientation and pennation angle of the fiber bundles became more realistic. More recent 3D models have shown the MH as having three parts with only the middle and posterior parts attaching to a raphe of varying width. The anterior part has been shown to consist of horizontal fiber bundles, with no central raphe, as in the earliest illustrations. SIGNIFICANCE. Comparisons of dissected specimens do not always correspond to historical or modern illustrations. Advancements in the accuracy of depictions of MH's architecture have been made since the 16th century and have contributed to our current understanding of this muscle's anatomy and function.

NATION, Philip B. and Margaret A. JERGENSON. Department of Oral Biology, School of Dentistry, Creighton University, Omaha, NE 68178, USA.

### A literature review of the influence of the stomatognathic system on body posture.

INTRODUCTION. The stomatognathic system (SS) is a functional unit made up of the jaws, dental arches, masticatory muscles, and associated structures. The components of the SS act in unison to influence or control functional activities such as phonation, deglutition, mastication, and respiration. The aim of this literature review was to determine the impact of functional activities of the stomatognathic system on overall body posture based on available research studies. RESOURCES. A thorough literature review of scholarly publications from peer reviewed journals was conducted. DESCRIPTION. The review included available research material dealing with the functional impact of the SS on body posture. Emphasis was placed on similar findings and correlations to dental occlusion. SIGNIFICANCE. A proven causal link or predictable relationship between stomatognathic function and positioning of the spine, ribcage, or pelvis would influence clinical treatment methods for a wide range of orthopedic issues such as scoliosis and low back pain. The literature has shown that body posture appears modifiable under experimental conditions, however, these findings seem limited to the head and neck region and in the case of occlusal interference evidence points to predominantly transient changes. A causal link or predictable relationship between dental occlusion and body posture did not emerge from the studies included suggesting low clinical significance of findings.

NILSSON, Wesley, Dae KIM, Ijoma NWOSU. American University of the Caribbean, Cupecoy, Dutch Lowlands, Sint Maarten, Dutch West Indies.

### Circle of Willis vasculature anomalies - a comparison between Dutch and American cadavers.

INTRODUCTION. We are privileged at the American University of the Caribbean to have access to cadavers from two separate populations, America and the Netherlands. It has allowed us to compare a unique aspect of the blood supply to the brain, the branching of the vasculature on the Circle of Willis. As we endured our

*continued on next page*

## Abstracts - Poster Presentations Session 1 continued

studies in medicine it became apparent how vital the smallest anomalies could be in determining clinical presentation of strokes to the brainstem. For that reason we began to dissect, measure, and catalog all of the major arteries branching off the Circle of Willis. It became apparent that the posterior inferior cerebellar artery in particular was the most often abnormality. METHODS. At the American University of the Caribbean we work on a trimester schedule. Therefore three times a year we extract the brains from the cadavers after craniotomies are performed. The craniotomy technique we choose to use allows us to keep the brainstem fully intact. Upon extraction photographs of the brain are taken for our records. Then over the course of the semester the vasculature is removed, digitally measured using a caliper, and photographed. SUMMARY. The posterior inferior cerebellar artery, a critical blood supply for the medulla, had three different presentations: branching off of the vertebral arteries, branching off of the basilar artery, or uniquely presenting unilaterally. An unexpected finding was the difference in diameter of the vasculature between the two populations, a now ongoing accumulation of data. CONCLUSIONS. This data should be used clinically to better formulate at risk populations for a stroke in the posterior inferior cerebellar artery due to hypertension.

OKUDA, Itsuko<sup>1</sup>, Keiichi AKITA<sup>2</sup>, and Yasuo NAKAJIMA<sup>3</sup>. <sup>1</sup>Department of Diagnostic Radiology, International University of Health and Welfare, Mita Hospital, Tokyo, 1088329, JAPAN; <sup>2</sup>Department of Clinical Anatomy, Graduate School of Medical and Dental Sciences, Tokyo Medical and Dental University, Tokyo 1138519, JAPAN; <sup>3</sup>Department of Radiology, St. Marianna University School of Medicine, Kanagawa, 2168511, JAPAN.

### Anatomic imaging analysis for the facial structures affect facial aging.

INTRODUCTION. Aging is an inevitable physiological phenomenon, and the first aging signs often are noted on the face. Facial aging is caused not only by age-related changes in the skin, but also by changes in muscles, soft tissues, and adipose tissues. Understanding the superficial facial anatomy is important to understanding the physiologic changes that occur with aging. We present the imaging anatomy of these structures based on anatomic knowledge and describe the radiographic manifestations of facial aging. RESOURCES. Cadaver faces were dissected, and soft tissue structures such as the muscles of facial expression, the superficial musculoaponeurotic system (SMAS) and the adipose tissue were examined. The SMAS was also confirmed histologically. Imaging features were obtained by a 64- or 320-multidetector row CT (MDCT) scanner and 3-T magnetic resonance (MR) imager. These imaging features were compared to the anatomic and histological findings. DESCRIPTION. CT and MR imaging techniques can visualize the facial structures. These detailed imaging features provide the subcutaneous anatomic information, and analysis of the facial structures provides much needed insight into the age-related changes in the face. With age, the most of the face muscles were attenuated and the SMAS had been thinning. The superficial cheek fat became atrophic and drooped. The buccal extension of the buccal fat was remarkable in the elderly. These produced a hollowed-out look in the midface and less firm of the jaw line. SIGNIFICANCE. It is necessary to know the physiological changes of the facial aging and anatomy of the facial anatomy. It is important to understand the facial imaging features based on anatomy for the analyses mechanism of facial aging. CT and MR images could depicted subcutaneous anatomical information, and contribute to evaluate for the facial aging. These imaging analytical methods can be applied to the field of aesthetic plastic surgery of the facial anti-aging.

PUETZ III, William J., Laura C. BARRITT, Jason M. KUM, Sonia M. SANCHEZ, Shikha TARANG, Barbara J. O'KANE. Department of Oral Biology, School of Dentistry, Creighton University, Omaha, NE 68178, USA.

### TREM-1 and TREM-2 protein expression in normal and healthy human gingival tissue.

INTRODUCTION. Inflammation of gingival tissue (periodontitis), affects both the gingiva and the supportive alveolar bone leading to tooth loss and other health risks. Studies have shown that chronic inflammation in some systems is modulated by TREM-1 and TREM-2. TREM-1 amplifies inflammation while TREM-2 functions as an inhibitor. This study aimed to analyze the expression of TREM-1 and TREM-2 proteins in situ and to determine if there is differential expression of these markers in normal versus inflamed gingiva. METHODS. Gingival tissue was harvested from the coronal area of extracted teeth, and processed for frozen sections.

*continued on next page*



## Abstracts - Poster Presentations Session 1 continued

Tissues were submitted to immunohistochemistry with antibodies against TREM-1 & TREM-2 and qualitative analysis of protein expression was performed by fluorescent microscopy. SUMMARY. Preliminary data from the immunofluorescence studies showed little expression of TREM-1 & TREM-2 in oral keratinocytes. Moreover, TREM-1 expression was found to be slightly increased in healthy tissues, while TREM-2 expression was decreased in inflamed tissues. CONCLUSIONS. Preliminary data showed no significant changes in TREM-1 and TREM-2 expression in oral keratinocytes. Noteworthy, some cells in the connective tissue, as well as a subgroup of cells in the epithelial basal layer showed positive reaction for both proteins in healthy and inflamed gingiva. Whether this observation is the result of a technical artifact, decreased sensitivity of the immunofluorescence method compared to Western blot, or the actual expression pattern for both proteins, remains to be assessed. The possibility of decreased sensitivity on immunofluorescence is highlighted by our Western Blot findings from our pilot study, suggesting an association between TREM-1 and TREM-2 with tissue from healthy and periodontitis patients, respectively. Further studies are required to specifically identify the epithelium where these proteins are expressed.

ROBERTS, Shannon L.<sup>1</sup>, Zhi LI<sup>1</sup>, Adel FATTAH<sup>2</sup>, Nancy MCKEE<sup>3</sup>, and Anne M. AGUR<sup>1</sup>. <sup>1</sup>Division of Anatomy, Department of Surgery, University of Toronto, Toronto, ON M5S 1A8, Canada; <sup>2</sup>Department of Plastic Surgery, Alder Hey Children's NHS Foundation Trust, Liverpool L12 2AP, United Kingdom; <sup>3</sup>Division of Plastic and Reconstructive Surgery, Department of Surgery, University of Toronto, Toronto, ON M5T 1P5, Canada. Pectoralis minor transfer for facial reanimation: Architectural study of donor and recipient muscles.

INTRODUCTION. Facial reanimation to restore smile requires a viable donor muscle that matches the recipient muscle's architecture as closely as possible. Pectoralis minor (PM) has been used as a donor muscle by placing its superior border inferiorly in the face and suturing either the coracoid or rib attachment to the oral commissure. However, the architecture of PM has not been quantified in 3D and compared to recipient facial muscles. The purpose was to compare, in one cadaveric specimen, the architecture of PM with risorius (RI), zygomaticus major (ZM) and levator labii superioris (LLS). METHODS. Fibre bundles of each muscle were serially dissected and digitized (Microscribe™ MLX Digitizer), along with tendons/aponeuroses and skeleton. Data were reconstructed into 3D models (Autodesk® Maya®). Fibre bundle length (FBL), pennation angle (PA), physiological cross-sectional area (PCSA), muscle volume (MV), and principal fibre bundle orientation (line of action) were quantified and compared between donor and recipient muscles. SUMMARY. PM has superior, middle and inferior parts. Mean PA of the superior part of PM ( $22.4 \pm 5.2^\circ$ ) was similar to RI ( $24.7 \pm 12.3^\circ$ ), the middle part ( $7.5 \pm 3.4^\circ$ ) to ZM ( $6.2 \pm 3.7^\circ$ ), and the inferior part ( $15.3 \pm 3.6^\circ$ ) to LLS ( $17.8 \pm 13.0^\circ$ ). Mean FBL of the superior part was about 1.5 times greater than RI, the middle part 2 times greater than ZM, and the inferior part 6 times greater than LLS. PCSA of all parts was greater than the recipient muscles. CONCLUSIONS. Similarities in the PAs of the recipient muscles and their respective PM donor parts suggest that comparable lines of action may be achieved by anchoring the donor part to the recipient muscle's attachment sites, resulting in similar movement patterns. A comparative study of the musculotendinous architecture of PM and other donor muscle options, including gracilis, masseter and latissimus dorsi, is needed to determine the conditions under which each donor muscle may be suitable to restore smile.

RONECKER, Julie C., Brandon M. GEOSLING, and Anthony B. OLINGER. Department of Anatomy, Kansas City University of Medicine and Biosciences, Kansas City, MO 64106, USA. Characterization of the clavicular deltoid tubercle by gender for use as a palpable landmark.

INTRODUCTION. Subclavian vein cannulation is a common procedure to gain central venous access of a patient. Several landmarks exist to determine site of entry and angle, but require additional patient manipulation and anatomical measurements. Recent studies suggest that the deltoid tubercle, located on the anterior surface of the lateral third of the clavicle, would simplify this procedure because of its proximity to the vein and ability to be palpated easily. This study aims to characterize the location of the deltoid tubercle on the clavicle and determine its prevalence in the general population for its use as a palpable surgical landmark.

*continued on next page*

## Abstracts - Poster Presentations Session 1 continued

**RESOURCES.** A total of 68 right and left clavicles (30 male and 38 female) were used from 47 embalmed cadavers in this study. Skin, muscle, and connecting structures were removed from the clavicle to access the deltoid tubercle. The tubercle was characterized by its length (mm), its distance from the sternal and acromial ends to the tubercle's center (mm), and its ability to be palpated in both male and female cadavers.

**DESCRIPTION.** The clavicles revealed statistically similar deltoid tubercle sizes in both genders. The average male and female tubercles were 12.46mm +/- 5.37mm and 13.09mm +/- 4.50mm, respectively. Tubercles were also similar distances from the sternal and acromial ends in both males and females. The majority of tubercles (80%) were palpable, and the ability to be palpated was dependent on tubercle size (palpable tubercle 14.22mm +/- 4.36mm, and non-palpable tubercle 6.94mm +/- 1.55mm). **SIGNIFICANCE.** Because this structure can be palpated easily in both genders, is located in the same relative location on the clavicle in both males and females, and requires no additional measurements to perform central venous access, the deltoid tubercle represents a prevalent, reliable surgical landmark.

SAKAMOTO, Yujiro. Graduate School of Medical and Dental Sciences. Tokyo Medical and Dental University. Tokyo 113-8549, Japan.

### Interrelationships between the insertions of the infrahyoid muscles.

**INTRODUCTION.** Many muscles attach to the hyoid bone with an overlap, and their interfusion or anomalous bundles are often found in this region. This gross anatomical study investigated the insertions of the infrahyoid muscles to clarify their spatial relationships. **METHODS.** The attachments of the thyrohyoid and the insertions of the other infrahyoid muscles were examined under a binocular microscope in 20 Japanese cadavers. **SUMMARY.** The sternohyoid was inserted into the medial half of the inferior border of the body of hyoid bone, and the insertion was away from the fellow. The superior belly of the omohyoid attached to the body just lateral to the sternohyoid, which was sometimes overlapped by the omohyoid. The thyrohyoid arose from the lateral half of the inferior border of the lamina and the oblique line of the thyroid cartilage. It was inserted into the body of hyoid bone and the inferior border of the anterior half of the greater cornu. The thyrohyoid attached to the body just lateral to the sternohyoid and inferior to the omohyoid, and the insertion was rarely overlapped by the sternohyoid or attached laterally to the omohyoid. The sternothyroid was inserted into the oblique line lateral to the thyrohyoid. Aside from the medial fibers that attached to the inferior thyroid tubercle, the external and internal fibers of the sternothyroid were frequently linked with the lateral fibers of the thyrohyoid and the middle fibers of the thyropharyngeal part of the inferior constrictor, respectively. The medial fibers of the sternothyroid were rarely linked with those of the thyrohyoid. **CONCLUSIONS.** The fusion between the lateral fibers of the thyrohyoid and the sternothyroid was frequently found. Although the insertion of the thyrohyoid is overlapped by the omohyoid, their interfusion was not found. The findings suggested that whereas the thyrohyoid can act separately from the sternohyoid and omohyoid, its function is often influenced by the sternothyroid in many cases.

SARALAYA, Vasudha V., and Murlimanju B. VIRUPAKSHAMURTHY. Department of Anatomy, Kasturba Medical College, Mangalore-575004, Manipal University, Manipal, Karnataka, India.

### Morphological study of the parietal emissary foramen and their clinical importance.

**INTRODUCTION.** The parietal emissary vein is the one which connects the veins of the scalp with the superior sagittal sinus. There are not enough studies available about these veins and the foramina which transmit them. In the present study, the objectives were to study the frequency of the emissary foramina in the parietal bones of the adult skull and to study their number. **METHODS.** The present study included 58 adult human skulls which were available at the gross anatomy laboratory of our institution. The study included 116 parietal bones which were macroscopically observed for the prevalence, number and morphology of the emissary foramina. **SUMMARY.** The emissary foramen was present in 83 (71.5%) parietal bones of the present study. It was present at the junction between the middle 1/3 and posterior 1/3 region of the parietal bone. The foramen was observed single in 73 parietal bones (62.9%), double in 8 bones (6.9%), and triple in 2 parietal

*continued on next page*



## Abstracts - Poster Presentations Session 1 continued

bones (1.7%). The emissary foramen was absent in 33 (28.4%) parietal bones. The bilateral absence of parietal emissary foramen was seen in 7 (12.1%) skulls. It was unilaterally absent in 19 (32.7%) skulls. It was observed that the accessory parietal emissary foramina were present in only 8 (13.8%) skulls. The mean distance of the foramen from the sagittal suture was  $6.7 \pm 2.9$  mms and  $6.8 \pm 2.8$  mms on the right and left sides respectively. CONCLUSIONS. Recognition of the parietal emissary veins and accessory parietal emissary veins during the neurological surgery is important to minimize the bleeding. In the neurosurgical practice, the knowledge is important due to their significance in connecting the extra cranial veins with the intracranial veins. They may be involved in the pathogenesis of the bacterial infections of the central nervous system. In this context, their morphology and morphometric data is essential to the clinicians as a basic reference.

SAWYER, F. Kip<sup>1</sup>, Stephanie M. SHAW<sup>2</sup>, and Anne M.R. AGUR<sup>1</sup>. <sup>1</sup>Division of Anatomy, Department of Surgery, University of Toronto, Toronto, ON M5S 1A8, Canada; <sup>2</sup>Department of Speech-Language Pathology, University of Toronto, Toronto, ON M5G 1V7, Canada.

### Evolution of the anatomical illustration and understanding of the digastric muscle.

INTRODUCTION. The digastric muscle has been the focus of illustrations of the suprahyoid region since the beginning of the modern era of anatomical study in the 16th century. The evolution of the depiction of the muscle over the following centuries is reflective of the progress that was made in both structural understanding and illustrative accuracy. By appreciating this progress, present day anatomists can gain insight into the current understanding of the digastric's morphology. RESOURCES. Illustrations depicting the digastric muscle were assembled from the Anatomical Plates Collection at the Thomas Fisher Rare Books Library, University of Toronto. The plates ranged from the 16th to 19th centuries, encompassing the work of such authors and artists as Da Vinci, Vesalius, Maurer, Hunter, and Ford. Plates were reviewed for their correspondence with dissections, modern literature, and three-dimensional computer models of specimens in situ. DESCRIPTION. Early illustrations sometimes depicted the digastric as a single-bellied muscle. Later works included two distinct bellies and the correct relationship to the stylohyoid, but accurate illustration of the intermediate tendon and connection to the hyoid was inconsistent. Further advancements incorporated fiber bundle architecture and tendinous and aponeurotic components. As early anatomists relied on observations of limited specimens, it was not uncommon to unknowingly produce faithful illustrations of anomalous digastric muscles. SIGNIFICANCE. The current understanding of the digastric has evolved over the last five hundred years as a result of observations from numerous surgeons, anatomists, and artists. This is reflected in the gradual fine-tuning of the muscle's depiction in the surveyed texts. It is also evident that recognition of anomalous morphologies may have posed challenges to earlier surgeons and anatomists, as the typical morphological patterns may not have been readily apparent.

SCHULTZ, Pamela E, Anthony WHITLOW, Holbert HODGES, Stanley ILIFF, and Donna HERMEY. LMU-DCOM, Harrogate, TN 35572, USA

### A head above the rest: An introduction to student plastination in medical gross anatomy.

INTRODUCTION. Medical Gross Anatomy (MGA) traditionally includes atlas guided lecture combined with small group dissection of the human body. Many students however fail to truly appreciate the dissection due to the difficulty of translating illustrations found in atlases to a real body. Osteopathic medical students' further struggle in conceptualizing structures found deep within the body that may not typically be dissected but which are relevant to osteopathic manipulative treatment. While dissection is meant to be the tool for understanding anatomical relationships, the difficulty of the dissection process under time constraints may hinder students' ability to effectively make use of this medium. RESOURCES. Student plastinated dissections were presented as supplemental learning to MGA as lecture style and hands-on lab demonstrations. Presentations highlighted various high yield structures of two separate, and different, human head and neck plastinations. DESCRIPTION. Supplementing traditional MGA curriculum with plastinated models as a three dimensional teaching tool provides a realistic model to guide students through the dissection process;

*continued on next page*

## Abstracts - Poster Presentations Session 1 continued

maximizing the learning potential of first year medical students. SIGNIFICANCE. Plastination aids in students' visualization of an actual dissection in conjunction with their scheduled lab dissection; enhancing the understanding of tissue types and delicate anatomical structures. This provides elements of reality that traditional models and 2D resources may inadequately portray. Student driven plastinated models are created from the student perspective accentuating structural relationships that he/she felt were somewhat elusive. With further relevance to osteopathic medical education, the interdisciplinary and conceptual learning of human anatomy is critical.

SINGH Rajani<sup>1</sup>, R. Shane TUBBS<sup>2</sup>. <sup>1</sup>Department of Anatomy, AIIMS, Rishikesh 249201 Uttarakhand, India;

<sup>2</sup>Pediatric Neurosurgery, Children's of Alabama, Birmingham AL, 35233 USA

Affect of cervical siphon of external and internal carotid arteries: A case report.

INTRODUCTION. Variations of the courses, configuration and branching pattern of the external and internal carotid arteries, especially when curved in S-shape, are very important for hemodynamic changes leading to clinically significant complications of blood flow. This study describes new variations in the courses of the external and internal carotid arteries simultaneously, from straight to highly tortuous, with two S-shapes and curved with one S-shape respectively in cervical region. The study is aimed at reporting abnormal cervical siphons in these arteries and to explore their clinical significance. RESOURCES. During routine dissection of the neck of a 70 year old female cadaver while teaching to the undergraduate medical students, the external and internal carotid arteries were discovered to follow curved/tortuous S-shaped courses in the neck resulting in a cervical siphon. The angles between inflow and out flow of the blood at the bends were measured and the change in velocity at each bend was computed for both arteries. Qualitative hemodynamic changes were assessed and their relevance to clinical complications considered. DESCRIPTION. The external carotid artery had five bends forming angles of 20°, 30°, 51°, 52° and 60° and the internal carotid artery two bends with angles of 28° and 48°. There is progressive decrease in velocities at each bend. Thus curved courses of these arteries might result in reduced velocity/stasis, turbulence and low shear stress causing atheromata, hypoperfusion and hypertension. Such kinks could be mistaken for tumors and abscess during imagery. SIGNIFICANCE. Knowledge of anatomical variants of the carotid arteries will be useful for anatomists, surgeons, radiologists, and physicians.

SNOSEK, Michael, and Marios LOUKAS. St. George's University, St. George's, Grenada, West Indies.

The anatomy of the cervical fascia of the spaces of the neck and their clinical significance.

INTRODUCTION. Anatomical spaces normally exist throughout the body. In the neck, these spaces are usually bounded by the fascial layers investing the surrounding musculature and viscera. Reports of these spaces and associated fasciae are scattered in the literature, with little uniformity and agreement on their anatomical descriptions and terminology. There also is no single compilation of this data in the context of clinical relevance. RESOURCES. Twelve (12) embalmed adult cadavers (6 male and 6 female) ranging in ages from 64 to 94 were used in the study. PubMed was used for a literature review. DESCRIPTION. The neck region was dissected in the cadavers to investigate the gross anatomy of the fascia involved in the spaces of the neck. Select fascial layers underwent histological investigation to determine its microstructure and organization. SIGNIFICANCE. Spaces in the neck can be involved in infections, tumors, imaging studies and in tracking injectate for nerve blocks. Based on the connections and properties of the associated fasciae, some of these spaces allow for communication with other body cavities and are therefore relevant in predicting outcomes of certain conditions. In this paper, we aimed to collect this information in hopes of educating clinicians and surgeons to allow for earlier identification of involved spaces in certain disease processes.

## Abstracts - Poster Presentations Session 1 continued

THERIOT, Krystle B<sup>1</sup>, Osama AHMED<sup>2</sup>, Jonathan WALTHER<sup>3</sup>, and Bharat GUTHIKONDA<sup>2</sup>. <sup>1</sup>Department of Cellular Biology and Anatomy; <sup>2</sup>Department of Neurosurgery; <sup>3</sup>School of Medicine, LSU Health Science Center, Shreveport, LA 71130, USA.

### Assessment of anterior petrosectomy: cadaveric and radiographic analysis of adjunct to subtemporal approach.

**INTRODUCTION.** The subtemporal approach is useful for lesions in the upper part of the posterior fossa, but retraction of the temporal lobe of the brain and the tentorium provides limited access since the petrous portion of the temporal bone blocks the view into the posterior fossa. The anterior petrosectomy approach, or removal of a rhomboid shaped area in the anterior aspect of the petrous portion of the temporal bone, is an adjuvant to the subtemporal approach to gain additional access to the posterior fossa. The present study aimed to describe and quantify the benefits this adjuvant provides. **METHODS.** Fifteen craniotomies were performed on fresh cadaver heads exposing the structures commonly seen in a subtemporal approach. Visible structures were recorded and preoperative CT scans were obtained. Anterior petrosectomies were then performed, newly visible structures were recorded and postoperative CT scans were obtained. The two scans for each cadaver were reconstructed into 3D models using InVivo software and superimposed. Measurements were determined for the amount of bone removed and increased angle of view. **SUMMARY.** The anterior petrosectomy gives surgeons an average increased view of approximately 120°, making it possible to view Cranial Nerves III, IV, VI, and VII, arteries such as the Basilar Artery, Posterior Cerebral, and Superior Cerebellar, and parts of the superior brainstem. **CONCLUSIONS.** The study shows that the anterior petrosectomy is an effective adjunct to the subtemporal approach when lesions are found between the Trigeminal Nerve (CN V) and the Facial Nerve (CN VII).

WATANABE, Koichi, Tsuyoshi SAGA, Joe IWANAGA, Yoko TABIRA, Moriyoshi NAKAMURA, Koh-ichi YAMAKI. Department of Anatomy Kurume University School of Medicine, Kurume, Fukuoka, 830-0011, Japan  
Two cases of the dual origin of left vertebral artery.

**INTRODUCTION.** The vertebral artery usually arises from the first part of the subclavian artery and enters into the transverse foramen of the sixth cervical vertebra. However, some anatomical variations of the vertebral artery have been reported. The vertebral artery of unusual origin or unusual entrance level to the transverse foramen of the cervical vertebra are sometimes experienced. We have experienced two cases of the dual origin of the vertebral artery in our anatomical dissection course for medical students. **METHODS.** Cases were 79 year-old male and 95 year-old female. In both cases, the dual origin of the vertebral artery was observed on the left side. One artery arose from the aortic arch between the origin of the left common carotid artery and the left subclavian artery and another artery arose from the subclavian artery as usual. The artery of aortic arch origin entered into higher transverse foramen of the cervical vertebra than the artery of the subclavian artery origin. In the first case, the entrance level to the transverse foramina was the third and the fifth cervical vertebrae. In the second case, the entrance level was the fourth, the sixth, and the seventh cervical vertebrae. In both cases, only the vertebral artery of aortic arch origin became the vertebral artery whereas the vertebral artery of subclavian artery origin became the radiculomedullary artery and flowed into the anterior spinal artery. **SUMMARY.** Dual origin of the vertebral artery is extremely rare anatomical variations and 36 cases have ever been reported except the cases in the 19th century. In the most cases, two vertebral arteries of different origin join to one vertebral artery in the various level. However, in our cases, two ipsilateral vertebral artery did not join but became the different arteries. **CONCLUSION** This anatomical variation is rare but the knowledge of this variation is extremely important for the radiologists and endovascular surgeons.

## Abstracts - Poster Presentations Session 1 continued

WEISS II, Robert O., Takanari MIYAMOTO, and Neil S. NORTON, Creighton University School of Dentistry, Omaha, NE 68178, USA.

### Pilot study of anatomical complications for maxillary dental implants using cone beam computed tomography.

INTRODUCTION. Dental implants allow clinicians to reestablish greater function in patients while providing ideal esthetics in the human dentition. Accurate anatomical placement of the implant is critical for both osseointegration and avoiding anatomical complications. RESOURCES. Fresh tissue cadaver heads were scanned using CBCT before and after implant placement. In order to demonstrate anatomical complications, implants were placed correctly on one side of the maxilla and incorrectly on the other. A thorough anatomical dissection was then performed. DESCRIPTION. Cone beam computed tomography (CBCT) is a relatively new radiological option for dentists. It provides 3-D imaging of the head and neck, allowing the clinician a more accurate view of a patient's anatomy. These scans provide submillimeter placement of a maxillary implant. While the cause of maxillary implant failures varies, nearly all will result in anatomical complications. The purpose of this study was to examine the anatomical complications that result from incorrect maxillary implant placement. SIGNIFICANCE. Anatomical dissections were compared to CBCT images in order to observe the anatomical complications to various surrounding structures of the maxilla. Upon incorrect placement, many complications may occur, such as injury to adjacent teeth, flap dehiscence, or intraosseous hemorrhage. Serious complications include perforation of the nasal cavity or Schneiderian membrane leading to potential sinus involvement and subsequent foreign body reactions or infection. Post-operative maxillary sinusitis, osseointegration failure, and displacement of various structures may result from incorrect implant placement. Therefore, proper placement of maxillary dental implants is a necessity.

YASSA Hanan D.<sup>1</sup> and Maha A.E. WAHED<sup>2</sup>. <sup>1</sup>Anatomy and Embryology Department, Faculty of Medicine, Beni Suef University, Beni Suef, 62511, Egypt; <sup>2</sup>Anatomy and Embryology Department, Faculty of Medicine, Fayoum University, Fayoum, 63514, Egypt.

### The correlation between acromion types and subacromial space dimensions among Egyptians.

INTRODUCTION. Acromion morphology is believed to be an important factor in shoulder impairments. It can be the primary etiologic factor in subacromial impingement syndrome pathogenesis. The correlation between acromion types according to Bigliani classification and the subacromial space dimensions is a matter of debate, especially with accompanying degenerative changes on the inferior surface of acromion. METHODS. Through measuring the acromion inclination angle, acromions of 132 Egyptian scapulae were sorted into three types according to Bigliani, type I: flat, type II: curved and type III: hooked. To measure the acromion inclination angle and the subacromial space surface area, each scapula was vertically fixed and photographed from its lateral angle parallel to the glenoid fossa at fixed parameters. The photos were then conveyed to an image editing computer program; Paint program and Klonk image measurement program. For each scapula, the relative ratio of subacromial space surface area to the total scapula surface area was calculated. Scapulae of each acromion type were divided into two groups; normal scapulae with smooth inferior surface of acromion and degenerative scapulae with osteophytes or facies articularis acromialis on the inferior surface of acromion. The measured parameters were statistically compared between different types and groups. SUMMARY. The incidence of acromion types was 31.8% flat, 51.5% curved and 16.7% hooked. The degenerative signs were more common in hooked acromion. No significant difference of the subacromial space surface area between the three types of acromion. However, there was a significant decrease of the subacromial space surface area to total scapula surface area of hooked acromion especially in scapulae with degenerative signs group. CONCLUSIONS. The current study can contribute to the anthropological studies of scapula as well as to the clinical studies of shoulder diseases especially impingement syndrome in Egyptians.

# Abstracts – Poster Presentations Session 2

(listed by presenting author last name)

AL HARBI<sup>1</sup>, Yasser. A and Quentin A. FOGG<sup>1,2</sup>. <sup>1</sup>Laboratory of Human Anatomy, School of Life Sciences, University of Glasgow, Glasgow, G128QQ, UK; <sup>2</sup>Centre for Human Anatomy Education, Monash University, Melbourne, Australia 3800.

Morphological and statistical descriptions of the trapezium and 1st metacarpal bones.

**INTRODUCTION.** The trapeziometacarpal joint is amongst the most common sites for degenerative arthritis. One factor responsible for this is its shallow joint surface combined with a large range of motion. The articulating surfaces between the trapezium and 1st metacarpal are unique. The joint surface is saddle-shaped and allows thumb motion in radial-ulnar and dorso-palmar planes as well as some rotation. This study aims to describe how the shape of these surfaces (and associated landmarks) vary within a sample population. **METHODS.** Fifty dry cadaver trapezium and 1st metacarpal bones (25 right and 25 left) of unknown age and sex were used. 3D modelling was rendered in a virtual space using a digital microscribe and modeled/analysed using three different programmes (Rhinoceros 5.0, Amira, and Landmark). The greatest and least length and width of both articulating surfaces were assessed in 3D. A comparison between the results of different software was made. **SUMMARY.** Both the trapezium and the 1st metacarpal could be reduced to having five critical points that accurately define variations across the sample population. There were no significant differences between different software results. **CONCLUSION.** The statistical shape model of trapezium and 1st metacarpal give quantitative descriptions of the variations of bone shape. The models were reliably produced in various programmes and provided detailed and exciting visualisations of this joint. These variations will help explain different soft tissue arrangements (esp. ligament attachments) and motion patterns. Better understanding of potential correlations between skeletal variation and soft tissue supports may help the prevention and diagnosis of injuries and degeneration of this vulnerable joint. These data provide a clinically useful and engaging means of describing and viewing the trapeziometacarpal joint.

AL SAFFAR<sup>1</sup>, Radi A. and Quentin A. FOGG<sup>1,2</sup>. <sup>1</sup>Laboratory of Human Anatomy, School of Life Sciences, University of Glasgow, Glasgow, G128QQ, UK; <sup>2</sup>Centre for Human Anatomy Education, Monash University, Melbourne, Australia 3800.

Quantitative analysis of triquetrum-hamate entheses.

**INTRODUCTION.** Accurate identification of ligamentous structures is reliant upon defining their attachments. Specific attachment sites and their functional properties within the wrist joint have been a source of a debate in recent literature. This study aims to quantitatively investigate the ligamentous attachments around the palmar aspect of the triquetrum-hamate joint. **METHODS.** Fifty-three embalmed and 10 unembalmed cadaveric wrist specimens were dissected. The palmar ligaments around the triquetrum-hamate joint were investigated. Tissue was removed in blocks that contained each ligament. The blocks were processed and stained using a modified Masson's Trichrome technique. Each enthesis area was measured from serial histological sections using ImageJ software. **SUMMARY.** Different patterns of ligamentous attachments have been identified. All entheses were well demarcated and predominantly fibrocartilaginous. The mean indexed area of each enthesis was significantly larger than the mean indexed area of capsular attachment ( $p < 0.05$ ). **CONCLUSIONS.** The current study supported the established definition in previous studies of mechanically significant attachments. The true enthesial attachment is suggestive of an essential biomechanical role of the investigated ligaments within the wrist. It is apparent that understanding the structure of the enthesis is a key for better selection of ligaments for surgical restoration, augmentation, or more appropriate sites for tissue transfers.



## Abstracts - Poster Presentations Session 2 continued

AMABILE, Amy H., and John H. BOLTE, IV, Division of Anatomy, School of Health and Rehabilitation Sciences, College of Medicine, The Ohio State University, Columbus, OH 43210.

### Size of gluteus maximus and psoas major muscles varies with multifidus size in a cadaver population.

INTRODUCTION. Decreased multifidus (MF) cross-sectional area (CSA) has been shown to be correlated with low back pain (LBP). Based on this research, exercise interventions have been developed to address deficits in MF strength. If gluteus maximus (GM) and psoas major (PM) CSA are shown to be correlated with MF CSA, this might indicate that these muscles have an impact on, or are affected by, LBP. This in turn could justify further research into GM, PM and LBP, and the development of interventions targeting those muscles. The objective of the present study was to determine whether there is an association between the CSA of MF and the CSA of GM and PM in a convenience sample of adult cadavers. METHODS. MF, GM and PM CSA were measured in 35 adult male and female cadavers via computed tomography scan, for a total of 70 sets of muscle measurements. Using the OsiriX region of interest tool, measurements were taken at the L4 vertebral body for MF and PM; and at the second sacral foramen for GM. SUMMARY. Both GM and PM CSAs were found to be significantly correlated with MF CSA in this sample. When CSAs were separately analyzed by sex, the correlations with MF remained significant for males for both PM and GM, and for female subjects for PM. CSA correlation was not found to be affected by stature. CONCLUSIONS. In this cadaver population, GM CSA does vary with MF CSA in males; and PM CSA varies with MF CSA in both males and females. This may indicate a relationship between GM, PM and LBP, similar to that of MF CSA and LBP. Further study is indicated on in-vivo subjects with and without LBP, to determine whether this relationship is real and potentially clinically significant.

CESMEBASI, Alper<sup>1,2</sup>, Robert J SPINNER<sup>1</sup>, Jay SMITH<sup>1</sup>, Stephen M BANNAR<sup>3</sup>, and Jonathan T FINNOFF<sup>3</sup>. <sup>1</sup>Mayo Clinic, Rochester, MN 55905, USA; <sup>2</sup>St George's University, Grenada, West Indies; <sup>3</sup>Tahoe Orthopedics and Sports Medicine, South Lake Tahoe, CA 96150, USA.

### The utility of diagnostic and interventional ultrasound in identifying common fibular (peroneal) neuropathy secondary to fabellae.

INTRODUCTION. The fabella is a sesamoid bone in the posterolateral knee which may present itself as an etiologic cause of pain. In close proximity to the common fibular (peroneal) nerve (CFN), the fabella may impinge upon the nerve to cause fibular nerve palsies. While anatomical studies have established a relationship between the fabella and CFN, we present cases where sonography was able to determine the source of the pain secondary to CFN compression by an adjacent fabella in posterolateral knee pain that radiates into the anterolateral leg pain. METHODS. Four patients presented with complaints of posterolateral knee pain radiating into the anterolateral leg pain. All patients underwent diagnostic and interventional ultrasound (US) in the evaluation of posterolateral knee pain. SUMMARY. Two female and two male patients presented with complaints of posterolateral knee pain radiating into the anterolateral leg pain. Diagnostic and interventional ultrasound was able to determine the source of the pain was secondary to CFN compression by an adjacent fabella. In three cases, pain symptoms were resolved with US-guided CFN block. One patient had temporarily relief with CFN block and required surgical treatment with fabellectomy for complete resolution of symptoms. CONCLUSIONS. Dynamic sonography plays a role in providing convincing in vivo evidence to establish a causal relationship between fabella and fibular neuropathy in posterolateral knee pain.

## Abstracts - Poster Presentations Session 2 continued

DOMINGUEZ, Juan C<sup>1</sup>, Tatiana NDJATOU<sup>1</sup>, Mika HIRANO<sup>2</sup>, Djavlon A. KHAKIMOV<sup>2</sup>, Alisha J POONJA<sup>2</sup>, R. Shane TUBBS<sup>3,4</sup>, Marios LOUKAS<sup>4</sup>, Piotr B. KOZLOWSKI<sup>5</sup>, Anthony C. DILANDRO<sup>6</sup>, and Anthony V. D'ANTONI<sup>7</sup>. <sup>1</sup>The Sophie Davis School of Biomedical Education, The City College of New York, CUNY, New York, NY 10031, USA; <sup>2</sup>New York College of Podiatric Medicine, New York, NY 10035, USA; <sup>3</sup>Pediatric Neurosurgery, Children's of Alabama, Birmingham, AL 35233, USA; <sup>4</sup>Department of Anatomical Sciences, St. George's University, Grenada; <sup>5</sup>NEUROMEDLAB, Staten Island, NY 10314, USA; <sup>6</sup>Division of Pre-clinical Sciences, New York College of Podiatric Medicine, New York, NY 10035, USA; <sup>7</sup>Department of Pathobiology, The Sophie Davis School of Biomedical Education, The City College of New York, CUNY, New York, NY 10031, USA.

### Anatomic study of the triangular fibrocartilage disc of the wrist with surgical relevance.

INTRODUCTION. Advances in minimally-invasive wrist arthroscopy has resulted in a need to investigate the 3D morphology and histology of the articular disc (AD) of the triangular fibrocartilage complex (TFCC). The purpose of this study was to describe AD morphology and morphometry with dissection, histology and plastic model fabrication. METHODS. The wrists of 24 embalmed cadavers (10 female, 2 male) with a mean death age of 77.3 years were used. The AD was dissected from the TFCC and its length (anteroposterior), width (midbase to the peak of the AD), and thickness at five distinct points were measured with a digital caliper. One TFCC and its bony attachments were sectioned and stained with modified Masson's trichrome. Biofidelic plastic models of ADs were fabricated and compared to cadaveric ADs. SUMMARY. Mean (SD) length and width of the right ADs were 17.95 (3.74) and 7.69 (1.82) mm, respectively. Mean (SD) thickness of the anterior, posterior, medial, lateral and center of the right ADs were 1.54 (0.61), 1.69 (0.56), 1.52 (0.79), 0.75 (0.36) and 1.45 (0.83) mm, respectively. Mean (SD) length and width of the left ADs were 17.33 (2.94) and 7.35 (1.92) mm, respectively. Mean (SD) thickness of the anterior, posterior, medial, lateral and center for the left ADs were 1.89 (0.72), 1.65 (0.71), 1.40 (0.70), 0.70 (0.24) and 1.47 (0.65) mm, respectively. When comparing means between variables, no significant differences were found between right and left sides. The AD has a complex triangular and biconcave shape with a transitional zone from bone to hyaline cartilage to fibrocartilage. CONCLUSIONS. The morphometric description of the AD and its relation to the TFCC may enable advancements in arthroscopically-guided surgical disc repair.

EBOT Derrick<sup>1</sup>, Haider HILAL<sup>1</sup>, James COEY<sup>1</sup> and Sara SULAIMAN<sup>2</sup>. <sup>1</sup>Department of Anatomy, St. George's International School of Medicine; Drill Hall, Faculty of Health and Life Sciences; Northumbria University, Newcastle upon Tyne, NE1 8ST, UK; <sup>2</sup>Department of Applied Sciences, Faculty of Health & Life Sciences, Northumbria University, UK.

### High originating radial artery: anatomical study through the use of ultrasound.

INTRODUCTION. Typically, the radial artery arises as a branch from the brachial artery at the level of the neck of the radius in the distal antecubital fossa. Anatomical variations in the radial artery are relatively common. Published literature demonstrates a wide variability in the prevalence of high originating radial artery (0.5-14.27%). The literature also shows inconsistent and vague nomenclature when describing the arterial system in cases of high originating radial artery. This study aims to investigate the incidence of a high originating radial artery in vivo through the use of ultrasound. It goes on to propose a classification system utilising precise nomenclature to help in discriminating between the various patterns. METHODS. Fifty-four upper limbs from 27 individuals were investigated using GE LOGIQ e and SonoSite MicroMaxx ultrasound machines with 12L-RS & A L38e 10-5MHz transducer respectively. The radial artery was initially identified and followed proximally to its origin and then distally to the wrist noting its course and relationships to other anatomical structures. SUMMARY. High originating radial arteries were found unilaterally in 4 individuals (4/54, 7.4%). CONCLUSION. Variations in the anatomical course and relationships of the radial artery are pertinent to surgeons, radiologists and anatomists. The presence of a high originating radial artery has both clinical and surgically significance in procedures, such as arterial grafting and cardiac catheterization. Due to its superficial course, it is more vulnerable to injury due to trauma or during cannulation and drug administration. Bedside ultrasound techniques can not only be of benefit in identifying variations prior to such procedures but also for future anatomical studies.

*continued on next page*

## Abstracts - Poster Presentations Session 2 continued

FLACK, Natasha A.M.S., Stephanie J. WOODLEY, and Helen D. NICHOLSON, Department of Anatomy, Otago School of Medical Sciences, University of Otago, Dunedin, New Zealand.  
Immunohistochemical fiber typing of the hip abductor muscles.

INTRODUCTION. Together the hip abductors, gluteus medius (GMed), gluteus minimus (GMin) and tensor fascia lata (TFL) act as pelvic stabilizers during gait. Differential function of these muscles may be important in the rehabilitation of patients with hip joint pathology. Dissection and electromyography data demonstrate that GMed and GMin are comprised of up to four anatomical compartments, but it is unclear whether each compartment is capable of independent function. The fiber composition of a muscle may indicate its functional potential, but this morphological parameter has not been comprehensively investigated in the hip abductors. This study aimed to identify the ratio of type I to type II fibers between the four compartments of GMed and GMin as well as between the three hip abductor muscles. METHODS. Deep and superficial samples were taken from the four proposed compartments of GMed and GMin, and the mid-length of TFL from 14 hips (10 cadavers, 6 male; 66-93 years). Samples were stained for type II fibers using immunohistochemistry, fiber type proportions were estimated with stereological techniques. Using analysis of variance statistics, comparisons were made between superficial and deep, across muscles, compartments and between sexes. SUMMARY. To date, examination of six hips has shown that the proportions of type I and II fibers are similar for GMed; GMin has more type I (postural), and TFL has more type II (phasic) fibers. Males have a higher proportion of type II fibers in all muscles. No differences between compartments, or superficial and deep samples were found. CONCLUSIONS. These data are the first to identify that the fiber type composition of the hip abductors are sexually dimorphic and differ between the three muscles. Therefore, their individual influence at the hip joint as well as sex differences should be considered in subsequent biomechanical studies. Further study using fine wire electromyography is necessary for functional validation.

FOGG, Quentin A., Michelle R. QUAYLE, Justin W. Adams and Paul G. McMENAMIN. Centre for Human Anatomy Education, Monash University, Melbourne, Australia 3800.  
3D printing of scaphoid types improves visualisation of structural variability.

INTRODUCTION. The increasing availability of 3D printing technology presents new avenues for the exploration and experimentation with anatomical variance. The scaphoid is the most important carpal bone in terms of functional contribution. An increasing body of research suggests that the scaphoid of different individuals contributes to function in different ways, with two distinct subtypes described. This is difficult to convey with current medical imaging. This study describes how 3D printing can be used to visualise these differences more clearly. RESOURCES. Data for printing was sourced from CT scans (n= 45) of cadaveric wrists and from virtual reconstructions (n = 64) of dry and dissected bones. The best source data were selected for printing. A ZPrinter 650 (3D Systems) was used for printing models, as the high resolution (0.1mm layer thickness) enabled visualisation of subtle differences in structure. The system also allowed the models to be printed at greater than life size. DESCRIPTION. The printing enabled greater visualisation than possible on a screen in a virtual environment. Feel the model made a difference in understanding articular facet variation. This was especially notable when facets on opposing surfaces needed to be considered at once. This is not possible in a virtual environment unless a fully immersive, haptic-enabled facility is available. The ability to print oversized models enabled greater understanding of the differences. SIGNIFICANCE. These results are of great value to understanding the functional role of scaphoid sub-types. The accuracy of the models also promises an exciting future. Experimentation on bone geometry can be undertaken independent of bone health (a problem with typical cadaveric sample populations) and without the requisite assumptions of digital testing. Furthermore, repeated testing of an individual specimen will be possible for the first time, creating exciting opportunities for a new age of experimental anatomy.

## Abstracts - Poster Presentations Session 2 continued

GIEFER, Kristen Y., Kyle J. BUSCH, Ashley M. OLSON, Anthony B. OLINGER. Department of Anatomy, Kansas City University of Medicine and Biosciences, Kansas City, MO 64106, USA.

### A novel bilateral branching pattern of the axillary artery and its clinical implications.

INTRODUCTION. This report describes a novel bilateral branching pattern of the axillary artery. The axillary artery classically produces six branches including the superior thoracic artery, followed by the thoracoacromial trunk, the lateral thoracic artery, the subscapular artery, and most distally, the posterior and anterior circumflex humeral arteries. RESOURCES. Upon routine cadaveric dissection of the axillary region, an anomalous branching pattern of the axillary artery was discovered bilaterally on a 93 year old male specimen. DESCRIPTION. Just distal to crossing the first rib, the axillary artery produced a large trunk that supplied five of the six classic axillary branches. On the right, the thoracoacromial trunk arose first, followed by the supreme thoracic and lateral thoracic arteries. On the left, the supreme thoracic artery arose at the same level as the thoracoacromial trunk, followed by the lateral thoracic artery. Bilaterally, the trunk then continued as the subscapular artery and produced its terminal branches, the circumflex scapular and thoracodorsal arteries, but terminated as the posterior circumflex humeral artery. The axillary artery produced only one of its classic branches, the anterior circumflex humeral artery, distal to its anomalous trunk. SIGNIFICANCE. Surgeons should be aware of the potential for this type of anomalous branching when utilizing a transaxillary approach for treatment of venous thoracic outlet syndrome and breast augmentation, and when performing infraclavicular incisions for first rib removal. Surgical biopsies and tissue excision of axillary lymphatics due to breast cancer metastases and the use of certain axillary branches as recipient arteries during autogenous breast tissue reconstruction also place these anomalous branches at risk for injury.

GILLESPIE, Michael<sup>1</sup>, Devon SMITH<sup>1</sup>, Randy HURD<sup>2</sup>, and Jonathan J. WISCO<sup>1,3</sup>. <sup>1</sup>Brigham Young University, Provo UT 84602, USA; <sup>2</sup>Incompressible Fluids Lab, Utah State University, Logan, Utah; <sup>3</sup>University of Utah School of Medicine, Salt Lake City, UT 84132, USA.

### High-speed video capture of anterior cruciate ligament femoral avulsion.

INTRODUCTION. We are interested in the tear dynamics of anterior cruciate ligament (ACL) fiber bundles. In an attempt to capture high-speed videos of a grade 3 ACL sprain, we instead observed an avulsion tear at the ACL's femoral attachment. RESOURCES. We first dissected an unembalmed human cadaveric knee to expose the ACL. The ACL was then stained with a technique that was developed in previous studies to increase the ability to visualize tendon fiber bundles. The femur was secured to a platform and a strong valgus force was imposed on the knee in slight flexion. With a high-speed camera in place, the valgus force was increased until an avulsion occurred. DESCRIPTION. The posterolateral (PL) bundle tore out of its femoral attachment site first, followed by the anteromedial (AM) bundle. SIGNIFICANCE. ACL avulsion tears occur most frequently at the tibial attachment site in skeletally immature patients. Less is known about the incidence of ACL avulsion tears in adults. Our observation of a femoral avulsion tear in a skeletally mature knee suggests the possibility of a shift in where avulsion tears typically occur as the bony attachment sites mature. Further studies are needed in order to confirm this assumption. Current literature also suggests that the PL bundle is tighter in extension, whereas the AM bundle is tighter in flexion. Considering that the knee was only slightly flexed, the PL bundle should have been under greater stress during this procedure. Since the PL bundle tore from its femoral attachment site first, due to an overload of tension, it would seem that our findings confirm this observation.

## Abstracts - Poster Presentations Session 2 continued

HOUSLEY, Stephen N.<sup>1</sup>, James E. LEWIS<sup>2</sup>, Deon L. THOMPSON<sup>1</sup>, and Gordon WARREN<sup>1</sup>. <sup>1</sup>Department of Physical Therapy, Georgia State University, Atlanta, GA 30302, USA; <sup>2</sup>Department of Physical Therapy, Brenau University, Gainesville, Georgia 30501, USA.

### Proximal peroneus brevis muscle insertion and the prevalence of split tendons: a cadaveric study.

**INTRODUCTION.** The anomalous distal musculotendinous (MT) junction of the peroneus brevis (PB) muscle has been hypothesized to contribute to the development of longitudinal PB tendon tears. Specifically, mass action of the PB muscle belly was thought to increase the pressure on the superior peroneal retinaculum and increase the probability of peroneal tendon subluxation. A recent examination of the PB tendon junction found, contrary to this hypothesis, an association between anomalous proximal MT junction and prevalence of longitudinal split tears. The present study examined the relationship between MT junction and prevalence of longitudinal PB tendon tears. **METHODS.** Twenty-four PB tendon lengths were measured bilaterally in 12 human cadaveric specimens. Tendon lengths were assessed as the vertical distance from the most inferior aspect of the lateral malleolus to the most distal PB MT extension. Only full-thickness tears were identified and included. Lengths of tendons with and without longitudinal tears were compared. **SUMMARY.** Of the twenty-four tendons examined, seven (29%) presented with full thickness longitudinal tears from four cadavers. The mean length for tendons with tears was significantly ( $p < 0.001$ ) longer than those without [ $28.9 (\pm 3.0)$  vs.  $16.3 (\pm 7.3)$  mm]. **CONCLUSION.** Our research confirms the recent findings, showing that there is a statistically significant association between anomalous proximal muscle belly extension and longitudinal PB tendon tears. Further, we propose that a more proximal MT junction may predispose individuals to a lesser stabilizing effect of the muscle belly against the posterior lateral surface of the fibula, increasing the probability of anterolateral subluxation, attrition, and longitudinal tear development.

JOHNSTON, Mai-Lan, Ellis C. KELLY, Zhi LI, Joshua ATKINSON, and Anne M.R. AGUR. Division of Anatomy, Department of Surgery, University of Toronto, Toronto, ON M5S 1A8, Canada.

### Intramuscular architecture of the bellies of flexor digitorum superficialis: a 3D modelling study.

**INTRODUCTION.** Flexor digitorum superficialis (FDS) is important for grasp and fine motor skills. More detailed knowledge of the structure of the forearm muscles including FDS is necessary to understand hand function. However, no volumetric studies of the architecture of FDS were found. Therefore, the purpose was to visualize and quantify the musculotendinous architecture of FDS in 3D. **METHODS.** The musculotendinous elements of FDS were sequentially digitized (MicroScribe™ Digitizer) in 3 embalmed specimens. The data were volumetrically reconstructed in Autodesk® Maya® into 3D models that were used to visualize relationships and attachments of the bellies. Fibre bundle length (FBL), pennation angle (PA), and physiological cross-sectional area (PCSA) were quantified in 3D and compared between bellies. **SUMMARY.** FDS consisted of 5 bellies: 1 proximal and 4 digital. The proximal belly had parallel fiber bundles spanning between the medial epicondyle and the superior part of an intramuscular aponeurosis. The 2nd and 5th digital bellies attached proximally to the inferior part of this aponeurosis and to a deep aponeurosis located on the posterior surface of FDS. The 3rd belly attached proximally to the deep aponeurosis; the 4th primarily to a superficial aponeurosis, as well as to the intramuscular aponeurosis. The proximal belly had the largest mean PCSA ( $3.5 \pm 1.2 \text{ cm}^2$ ), whereas the digital bellies had the longest mean FBL ranging from 40.8mm (2nd digit) to 78.6mm (3rd digit). **CONCLUSIONS.** In addition to four digital bellies, FDS was found to have a proximal belly that shared a common aponeurotic attachment with all digital bellies except the 3rd. Since mean FBL of 2nd, 4th and 5th digital bellies was shorter than the 3rd, the common attachment provided a linkage with the proximal belly, possibly increasing their excursion and force-generating capabilities. Further study is needed to investigate in vivo activation of these bellies.



## Abstracts - Poster Presentations Session 2 continued

KHAKIMOV, Djavlon A.<sup>1</sup>, Mika HIRANO<sup>1</sup>, Alisha J. POONJA<sup>1</sup>, R. Shane TUBBS<sup>2,3</sup>, Marios LOUKAS<sup>3</sup>, Piotr B. KOZLOWSKI<sup>4</sup>, Khurram H. KHAN<sup>5</sup>, Anthony C. DILANDRO<sup>6</sup>, and Anthony V. D'ANTONI<sup>7</sup>. <sup>1</sup>New York College of Podiatric Medicine; <sup>2</sup>Pediatric Neurosurgery, Children's of Alabama; <sup>3</sup>Department of Anatomical Sciences; <sup>4</sup>NEUROMEDLAB; <sup>5</sup>VA Connecticut Healthcare System; <sup>6</sup>Division of Pre-clinical Sciences, New York College of Podiatric Medicine; <sup>7</sup>Department of Pathobiology, The City College of New York, USA.

### Anatomic study of interosseous talocalcaneal and cervical ligaments of foot with surgical relevance.

INTRODUCTION. There is controversy and conflicting findings regarding the morphology and orientation of the interosseous talocalcaneal ligament (ITCL) and cervical ligament (CL). The morphology of the CL and its relationship with the ITCL were studied in order to obtain a better understanding of these structures.

METHODS. Twenty-six feet (13 left, 13 right) were obtained from formalin-fixed cadavers (14 female, 4 male) with mean (SD) age at death of 80.9 (12.9) years. The length and width of the foot, and the width and height of the talus were measured. The height (anterior and posterior points), width (superior and inferior points), and thickness (superoanterior, superoposterior, inferoanterior, inferoposterior, and central points) of the CL were measured using a digital caliper. The talus was cut coronally to expose the ITCL and qualitative observations were noted. SUMMARY. The mean (SD) height and width of the CL at the anterior, posterior, superior, and inferior points were 8.27 (2.52), 13.95 (5.96), 9.15 (2.45), and 11.90 (4.30) mm, respectively. The mean (SD) thickness of CL at the superoanterior, superoposterior, inferoanterior, inferoposterior, and central points were 0.62 (0.24), 1.05 (0.30), 0.70 (0.26), 1.20 (0.34), and 0.97 (0.31) mm, respectively. The fibers of CL are oriented vertically or at a slight superoanterior to inferoposterior angle, whereas the fibers of ITCL are oriented in a slight superomedial to inferolateral angle. The fibers of CL and ITCL overlap inside the tarsal sinus with the CL positioned anteriorly, which helps to distinguish the two ligaments. CONCLUSIONS. In this study, we identified the morphometrics for the CL and qualitatively described the CL and ITCL. These results are relevant in introducing innovative techniques for reconstructive surgery of the subtalar ligaments in order to repair, for example, subtalar instability.

KHOUSHOO, John. Xiao WANG, Zhi LI, Shannon L. ROBERTS. Adarsh RAO, Anne M.R. AGUR. Division of Anatomy, Department of Surgery, University of Toronto, Toronto, ON M5S 1A8, Canada.

### Architecture of the anterolateral and posteromedial bundles of the posterior cruciate ligament.

INTRODUCTION. The posterior cruciate ligament (PCL) consists of anterolateral (AL) and posteromedial (PM) parts that have been found to have different functional roles by resisting posterior translation of the tibia relative to the femur at different joint angles. To date, reconstruction of the PCL using single and double stranded repairs has had variable success. Detailed knowledge of the geometry of AL and PM would enable the development of grafts with comparable properties to a normal PCL. The purpose of this study was to document and compare the 3D geometry and spatial relationships of AL and PM in full extension and 90° flexion. METHODS. In 5 formalin embalmed cadaveric specimens, AL and PM were exposed, and the knee was stabilized in full extension or 90° flexion with metal plates. A Microscribe® G2X Digitizer was used to digitize the fibre bundles of AL and PM and their attachment sites. The digitized data were reconstructed into 3D models using Autodesk® Maya® and the orientation and attachments of the fibre bundles were analyzed. Parameters including fibre bundle length (FBL), volume (V), and degree of rotation (torsion) were computed. SUMMARY. The AL and PM present with different morphology in full extension and 90° flexion. In extension, the majority of PM fibres were obliquely oriented but some fibres were vertical between attachment sites, whereas the AL fibres were lax and appeared "C-shaped". On average, PM fibres were 4mm longer than AL fibres in extension. The torsion of AL was 108° and PM 103°. In flexion, the PM fibres were more horizontal, while AL fibres lost their "C-shape" and became more vertically oriented. CONCLUSIONS. The results provide a detailed view of the internal structure of the PCL at the collagen fibre bundle level and captures the changes in the geometry and spatial relationships of AL and PM in full extension and flexion. These findings could be applied to design and test alternate double stranded repairs.

## Abstracts - Poster Presentations Session 2 continued

KO, Jong Bum<sup>1</sup>, Rohit SACHDEVA<sup>2</sup>, David COLLINS<sup>3</sup>, Soo Y. KIM<sup>2</sup>. <sup>1</sup>College of Kinesiology, University of Saskatchewan, Saskatoon, SK S7N 5B2, Canada; <sup>2</sup>School of Physical Therapy, University of Saskatchewan, Saskatoon, SK S7S 0W3, Canada; <sup>3</sup>Faculty of Physical Education and Recreation, University of Alberta, Edmonton, AB T6G 2H9, Canada.

### From The Novice To The Experienced Ultrasound User: 7D imaging Is Your Personal Tutor.

**INTRODUCTION.** Over the past decade, anatomical and histological studies have advanced our understanding of the supraspinatus muscle. Supraspinatus is composed of anterior and posterior regions that are distinct in muscle architecture, fiber type distribution and innervation. To date, activation of these individual regions has not been investigated. A better understanding of how these regions function can aid in re-evaluating current exercise protocols. Thus, the aim of the study was to evaluate the relative electromyographic (EMG) activity of the anterior and posterior regions of supraspinatus during common isometric exercises. **METHODS.** Twelve healthy participants (5 males/ 7 females) free of shoulder pathology were recruited (mean age  $32.5 \pm 12.2$  years). Fine-wire electrodes were inserted into the anterior and posterior regions of supraspinatus on the dominant arm. Electrode placement was guided by ultrasound imaging. EMG signals during isometric contractions against resistance (5% of body weight) were recorded at 30°, 60° and 90° of abduction in the scapular plane using a NORAXON system. EMG data, sampled at 3000 Hz, was processed using MATLAB™. Non-parametric statistics were used to compare EMG activity ratios for anterior and posterior regions. **SUMMARY.** For all positions, greater activity of the posterior region was found. A significant difference in medians was found between 60° and 90° of abduction ( $P=0.01$ ). A wide range in activation levels between regions of supraspinatus was observed between participants. **CONCLUSIONS.** Findings provide insight into the relative activity of the anterior and posterior regions during isometric shoulder abduction tasks. Although the posterior region is significantly smaller in volume than the anterior, it plays an important role during isometric shoulder abduction tasks.

KOSALKA, Robert<sup>1</sup>, Zhe Shun J. LI<sup>1</sup>, Chen-En HSIEH<sup>1</sup>, Jason LATSKY<sup>1</sup>, Khoi P. DANG-HO<sup>1</sup>, Sean LEVY<sup>1</sup>, Sara SULAIMAN<sup>2</sup> and James COEY<sup>3</sup>. <sup>1</sup>St. George's International School of Medicine Keith B. Taylor Global Scholars Program with Northumbria University, UK; <sup>2</sup>Department of Applied Sciences, Faculty of Health & Life Sciences, Northumbria University, UK; <sup>3</sup>Department of Anatomy, St. George's University School of Medicine, Grenada, West Indies.

### Prevalence of the persistent median artery: an ultrasound study.

**INTRODUCTION.** The carpal tunnel is a gateway by which the median nerve and nine extrinsic hand muscles tendons pass to reach the hand. A persistent median artery that failed to regress during the second month of gestation can be found in a subset of the general population. Previous cadaveric, ultrasound and MRI studies have reported variable incidence of persistent median artery ranging from 2.2%-27.1%. The aim of this study is to investigate the prevalence of the persistent median artery in vivo through the use of ultrasound. **METHODS.** One hundred and twenty four wrists from sixty two individuals with no previous wrist injury were examined by using a Sonosite Micromaxx ultrasound machine. The wrists were examined using an L38e/10-5MHz transducer, from proximal to distal at the level of the carpal tunnel, at a depth of 3.8 cm using Doppler ultrasound. The diameter of the artery was measured at a depth of 1.9 cm. Allen's Test was performed on subjects with persistent median artery to determine vascular contribution to the hand. **SUMMARY.** The persistent median artery was found unilaterally in three individuals (4.84% of individuals 2.42% of wrists), with a mean diameter of  $1.3 \pm 0.5$  mm. The artery does not appear to provide significant blood circulation to the hand during Allen's Test. **CONCLUSIONS.** The findings obtained from this study demonstrate a prevalence rate in line with similar studies reported in published literature. Ultrasound is a quick and effective method of not only to conduct anatomical descriptive studies, but also as a tool to screen patients prior to surgery. Surgeons operating in the wrist region should be aware of the possibility of the presence of the persistent median artery to prevent iatrogenic injury.

## Abstracts - Poster Presentations Session 2 continued

KUIK, Joyce, and Natalie R. SHIRLEY. Department of Anatomy, Lincoln Memorial University-DeBusk College of Osteopathic Medicine, Harrogate, TN 37752, USA

### A study of obesity: the relationship between BMI and heel spurs.

**INTRODUCTION.** As obesity rates rise, it is important to understand changes in skeletal morphology associated with increased body mass index (BMI). This study examines enthesophytes on the calcaneus (i.e. heel spurs) in two locations: the attachment sites of the calcaneal tendon and plantar fascia. **METHODS.** Calcaneal and plantar heel spurs were measured on 228 individuals from the William M. Bass Donated Skeletal Collection at the University of Tennessee. Maximum spur length was measured bilaterally with digital calipers. BMI was categorized as normal (<25), overweight (25-29.9), or obese (>30). The effects of BMI on spur length were evaluated with a MANOVA and Bonferroni post-hoc tests. Pearson correlations were calculated to examine the strength of the relationship between BMI and spur length, and between age and spur length. **SUMMARY.** The MANOVA indicated significant differences in calcaneal and plantar spur length among BMI categories ( $p<.01$ ). Bonferroni post-hoc tests showed significantly longer plantar and calcaneal spurs in obese versus normal individuals ( $p<0.0001$ ). Additionally, plantar spurs are significantly longer in obese versus overweight individuals bilaterally ( $p<0.01$ ), and in overweight versus normal individuals on the right side ( $p=0.046$ ). The correlation between BMI and spur length is 0.255 for calcaneal spurs and 0.375 for plantar spurs. The correlation between age and spur length is 0.075 for calcaneal spurs and 0.235 for plantar spurs. **CONCLUSIONS.** Obese individuals have significantly longer plantar and calcaneal heel spurs than individuals of normal BMI. The correlation between BMI and spur severity is stronger than the correlation between age and spur severity, suggesting that obesity is a greater risk factor than age for developing painful heel spurs. This issue is of particular concern because heel spurs may affect a patient's willingness to walk or exercise, thus worsening the overweight or obese condition.

LEWIS, C.C.<sup>1</sup>, K. TUFTS<sup>2</sup>, Z. LI<sup>3</sup>, A. AGUR<sup>3</sup>. <sup>1</sup>Samuel Merritt University, Oakland, CA., Department of Basic Sciences; <sup>2</sup>Samuel Merritt University, Oakland, CA., Program of Occupational Therapy; <sup>3</sup>University of Toronto, Toronto, Canada. Division of Anatomy, <sup>2</sup>Division of Anatomy, Department of Surgery, University of Toronto, Toronto, ON M5S 1A8, Canada.

### Quantitative Analysis of Aberrant Forearm Muscle with Possible Flexor Function.

**INTRODUCTION.** Knowledge of typical and aberrant anatomy is essential to the hand specialist in order to properly diagnose, treat, and manage disorders of the hand. We report an aberrant muscle of the anterior forearm observed bilaterally in a single cadaver (male, 94 yo) after standard dissection. **RESOURCES.** The forearms from an embalmed cadaver were dissected from the cubital fossa distally to the distal interphalangeal joint and observed for attachment points, innervations, muscle shape, and fascicle orientation. High-resolution digital images were obtained of the aberrant muscles during incremental dissections and compiled to generate a 3D model of each muscle in its entirety. Geometric analyses of fascicle attachments are underway to determine the muscle's cross-sectional fiber dimensions, quantify pennation angle, evaluate the force contribution of the fascicles to the muscle movement, and ultimately infer clinical implications based upon evaluation of the muscle's function. **DESCRIPTION:** The aberrant muscle has superficial and deep bellies originating on the lateral surface of the radius and ulna, with muscle fascicles oriented obliquely. Each muscle has tendons arising from the radial (1 from right, 2 from left) and ulnar bellies (2 from right, 1 from left) that join to form a common tendon that travels distally across the radioulnar joint, through the floor of the carpal tunnel, inserting onto the capitate and the base of the second and third metacarpals bilaterally, and the scaphoid (left). **SIGNIFICANCE:** Collectively, the anatomical features of the aberrant muscle suggest its function in wrist flexion. The anatomical features are similar to a previously described but rare flexor carpi radialis brevis vel profundus. However, the attachment points are similar to pronator quadratus. In conclusion, awareness of diverse hand anatomy will assist specialists during clinical examination and management of hand disorders or injuries.

## Abstracts - Poster Presentations Session 2 continued

MCKINNELL<sup>1</sup>, Zoe A., Daphnee BEAULIEU<sup>1</sup>, Renee WONG<sup>1</sup>, Sara SULAIMAN<sup>2</sup> and James COEY<sup>3</sup>. <sup>1</sup>St. George's International School of Medicine Keith B. Taylor Global Scholars Program with Northumbria University, UK; <sup>2</sup>Department of Applied Sciences, Faculty of Health & Life Sciences, Northumbria University, UK; <sup>3</sup>Department of Anatomy, St. George's University School of Medicine, Grenada, West Indies.

### All or nothing: Investigating the anterolateral ligament of the knee by the use of ultrasound.

**INTRODUCTION.** Although first described in the late 1800s, there has been little mention of the anterolateral ligament (ALL) of the knee in published literature until recently. Its very existence remains controversial. Recent cadaveric studies have renewed interest in the anterolateral ligament and it has supposedly been identified once by ultrasound. The aims of this study are twofold: to determine whether or not the anterolateral ligament is a distinct anatomical structure, and to establish the efficacy of ultrasound as a tool to visualize it. **METHODS.** Twenty knees from ten randomly selected individuals were examined using a Sonosite MicroMaxx ultrasound machine. A L38e 10-5MHz transducer was used to examine the lateral aspect of the knee in two positions: legs flexed to 30°, and legs flexed to 30° with internal rotation. The iliotibial band, tendon of popliteus, lateral meniscus, lateral collateral ligament, distal part of the femur, tibia and fibular head were identified on each knee. **SUMMARY.** According to the literature, the anterolateral ligament shares its origin with the lateral collateral ligament, runs inferior to the iliotibial band, and inserts into the mid portion of the proximal tibia. In one of the subjects, a distinct structure that resembled the anterolateral ligament previously documented was visualized. There was no evidence of the anterolateral ligament in the other nine subjects. **CONCLUSIONS.** Our results suggest that ultrasound might not be an effective method of visualizing the anterolateral ligament. Further studies are necessary to determine if the anterolateral ligament is an artefact of knee position or indeed a distinct anatomical structure.

ROMANI Michael<sup>1</sup>, Georgios MIHALOPULOS<sup>1</sup>, Andrew SHLIMUN<sup>1</sup>, Jainesh PATEL<sup>1</sup>, Michael TOMANI<sup>1</sup>, Ryan TOEWS, Maximilian SOLOW<sup>1</sup>, Sara SULAIMAN<sup>2</sup> and James COEY<sup>3</sup>. <sup>1</sup>St. George's International School of Medicine Keith B. Taylor Global Scholars Program with Northumbria University, UK; <sup>2</sup>Department of Applied Sciences, Faculty of Health & Life Sciences, Northumbria University, UK; <sup>3</sup>Department of Anatomy, St. George's University School of Medicine, Grenada, West Indies.

### Ultrasound assessment of patellar tendon length in athletes & non-athletes.

**INTRODUCTION.** Variation in the patellar tendon length has been linked with knee injury, including patellar instability. Previous studies have related patellar length to force output suggesting sport participation as an influencing factor. Traditionally, lateral X-ray films of the knee have been used to assess patellar tendon length with magnetic resonance imaging (MRI) being a more recent alternative albeit resource dependent. Ultrasound has been proposed within the literature as a non-invasive, low-cost solution but there is currently no consensus as to the technique employed and inter-operator error. This study aims to address the inter-operator variability and evaluate the patellar tendon length between athletes & non-athletes using ultrasound. **METHODS.** Eleven athletes and eleven non-athletes had their patellar tendons measured using a modified version of an established technique. Each tendon was measured independently by two investigators who were blinded to each other's results using GE LOGIQ e system with a 12L-RS transducer. **SUMMARY.** There was no significant difference between the measurements obtained from each of the investigators once a technique was clearly delineated. Average patellar tendon length was found to be  $47.1 \pm 7.8$  mm and  $45.1 \pm 4.0$  mm in athletes and non-athletes respectively with no significant difference in means between the two groups regardless of limb dominance. **CONCLUSIONS.** This study validated a pre-existing ultrasound technique with specific modifications to control inter-operator variability. A previous study suggested patellar tendon length was related to force output rather than age but our findings show no significant correlation between the two. Further work to evaluate the patellar length as a predictor for patellar instability is needed. The technique suggested in this study validates ultrasound as a non-invasive, cost effective means of assessing the patellar tendon.



## Abstracts - Poster Presentations Session 2 continued

RUTLAND Marsha D., Jesse RAWLINGS, Rebecca LONEY, Kaylea AULT, and Kate BRUMLEY. Hardin-Simmons University Physical Therapy Department. Abilene, TX 79698, USA.  
Diagnostic implications of a popliteal cyst in physical therapy education.

INTRODUCTION. Cadavers obtained for a physical therapy (PT) education program only include cause of death on the death certificate. Thus, information on underlying rheumatic diseases is rarely known since these are not typically listed as a cause of death. This study evaluated the findings of a large Baker's cyst found in the left popliteal region of an embalmed cadaver. As further dissection of the cadaver unfolded, multiple joints were found to have arthritic changes. Without knowledge of diseases the cadaver had prior to death, this study allowed students to evaluate other joints of the body which assisted in their understanding of systemic diseases. RESOURCES. An embalmed cadaver (of 1 year) in a PT anatomy lab dissected over an 8-month time period. DESCRIPTION. A 78 year old female cadaver was dissected by first year PT students. A large popliteal cyst was found measuring 3.6 cm length x 1.8 cm width x 1.8 cm depth in the left popliteal region extending distal to the popliteal space. As further joints were dissected, multiple areas of degeneration were noted. Bilateral total knee and patellar arthroplasties as well as a right total shoulder arthroplasty were found. The left shoulder exhibited severe hypertrophic osteophytes. Elbows and wrists demonstrated significant changes in the joint surfaces. SIGNIFICANCE. The knee joint is a common site for cyst formation. Large popliteal cysts may be found in those with subacute and chronic rheumatic diseases, such as rheumatoid arthritis. The finding of a large popliteal cyst motivated students to consider arthritic conditions that lead to the cyst formation. Because the cadaver is a PT student's first patient, it is important for them to relate anatomical findings with diseases that cause the types of physical disabilities they will encounter in their future practice.

SACHDEVA, Rohit<sup>1</sup>, Jonathan FARTHING<sup>2</sup>, Soo Y. KIM<sup>1</sup>. <sup>1</sup>School of Physical Therapy, University of Saskatchewan, Saskatoon, SK S7S 0W3, Canada; <sup>2</sup>College of Kinesiology, University of Saskatchewan, Saskatoon, SK S7N 5B2, Canada.

Changes in the architecture of supraspinatus following exercise training.

INTRODUCTION. Architecture and contractile capacity of skeletal muscles are interrelated. Understanding of fiber bundle changes with different exercises can have significant clinical implications. Supraspinatus strengthening is an integral part of shoulder rehabilitation programs. However, there is a wide disparity regarding the best exercise to strengthen the supraspinatus. Thus, the purpose of this study was to investigate changes in muscle architecture following three common supraspinatus strengthening exercises. METHODS. Participants were randomized into 3 exercise groups: full-can (FC), empty-can (EC) and prone horizontal abduction (PHA), and performed 3 exercise sessions/week for 8 weeks. Each session involved 4 sets of exercise for weeks 1-4 and 6 sets for weeks 5-8 with 8 repetitions/set. A previously validated ultrasound protocol was used to measure fiber bundle length (FBL), pennation angle (PA), and muscle thickness (MT) at baseline, after 4 and 8 weeks in 0° (relaxed) and 60° active (contracted) glenohumeral abduction. Isometric shoulder abduction strength was measured in 3 positions: full-can, empty-can and prone horizontal abduction. Factorial ANOVA with repeated measures and paired t-tests were used for comparisons. SUMMARY. Thirty-four healthy (15M/19F) participants (mean age 29.8±7.3 years) were recruited. Mean FBL reduced after 4 weeks in the FC (relaxed, p=0.001; contracted, p=0.008) and EC (relaxed, p=0.008; contracted, p=0.013). For PA and MT, no significant differences were found (p>0.05). An increase in strength in prone horizontal abduction position was observed after 4 weeks in all the groups (FC, p=0.005; EC, p=0.014; and PHA, p<0.001), but it increased only in PHA (p=0.004) after 8 weeks. CONCLUSIONS. Architectural changes suggest that PHA may be a better exercise to strengthen supraspinatus. Anatomically driven and informed exercises could provide critical information that may help clinicians decide on exercise prescription for clients.



## Abstracts - Poster Presentations Session 2 continued

SACHDEVA, Shireen, Sunay PATEL, and Natalie R. SHIRLEY. Anatomy Department, Lincoln Memorial University-DeBusk College of Osteopathic Medicine, Harrogate, TN 37752, USA.

### Osteophytic lipping in response to BMI in the tibio-femoral and tibio-talar joints.

**INTRODUCTION.** Osteophytic lipping is a bony outgrowth on the periphery of articulating surfaces that develops in response to cartilage degeneration that occurs with use, load bearing, and/or age. This study investigates the effects body mass index (BMI) and age on arthritic lipping in the knee and ankle joints. Obese individuals are at a higher risk of developing osteoarthritis due to greater load bearing on joints. The hypothesis is that the degree of lipping will be greatest in obese individuals, regardless of age. **METHODS.** Skeletal remains from the University of Tennessee W.M. Bass Donated Collection were sampled ( $n=247$ ). Maximum lipping of the distal femoral condyles, proximal tibial condyles and tibio-talar articulating surfaces was measured with sliding calipers. BMI was classified as normal, overweight, or obese; age was classified into three categories: 23-40, 41-65, and 66-90 years. A two-factor MANOVA with Bonferroni post-hoc tests was used to evaluate the effects of age and BMI on lipping. Pearson correlations were also calculated to examine the correlation between lipping and the independent variables. **SUMMARY.** The two-factor MANOVA showed that BMI has a significant effect on the degree of lipping on all joint surfaces examined ( $p<.01$ ). Age has a significant effect on lipping in the knee joint ( $p<.05$ ), but not in the ankle joint. Pearson correlations between BMI and lipping ( $r=.23-.41$ ) were greater for both joints than the correlation between age and lipping ( $r=.01-.23$ ). The correlation between age and lipping on the ankle joint was nearly zero ( $r=.01-.03$ ) compared to BMI and ankle lipping ( $.27-.41$ ). **CONCLUSIONS.** BMI plays a greater role than age in the severity of osteophytic lipping, specifically in the ankle joint. In particular, individuals with BMI $>30$  show early onset of osteoarthritic changes in the knee and ankle joints. These findings have important implications for health care providers regarding the care of obese patients.

SEMECHKO, Anton<sup>1</sup>, Anne M.R. AGUR<sup>1</sup>, Azam KHAN<sup>2</sup>, and Jeremy P.M. MOGK<sup>2</sup>. <sup>1</sup>Division of Anatomy, Department of Surgery, University of Toronto, Toronto, ON M5S 1A8, Canada; <sup>2</sup>Autodesk Research, Toronto, ON M5A 1J7, Canada.

### Quantification of morphological variations of male and female carpal bones using spherical extent functions.

**INTRODUCTION.** Quantifying morphological variations of the carpal bones is important when constructing an anatomically accurate biomechanical model of the wrist joint complex. Conventional morphological analyses employ time-consuming optimization procedures which cannot guarantee optimal correspondences. The purpose was to investigate a correspondenceless technique to quantify morphological variations of the carpal bones and to determine if significant differences exist between males and females. **METHODS.** We used surface meshes of the carpal bones reconstructed from CT scans (30M/30F). First, the bones were rigidly aligned. Then, each bone was encoded as a scalar function on a unit sphere, so that the value of this function was equal to the distance between the bone's center of mass and the furthest point on the bone's surface along a particular direction. Each function was sampled at 2562 locations and the values merged into a single vector. Morphological variations were quantified using principal component analysis of these vectors. Null hypothesis (i.e., there are no shape differences between female and male bones) was tested with 10E3 permutation tests using Hotelling's T<sup>2</sup> statistic as a measure of similarity between groups. **SUMMARY.** The correspondenceless technique enabled highly efficient representations of morphological variations, with at least 95% of variations of all bones accounted by the first principal component. Gender-specific morphological differences existed for all bones. The trapezoid and capitate had the most significant difference ( $p=0.01\%$  and  $p=0.12\%$ , respectively), while pisiform and hamate had the least ( $p=4.98\%$  and  $p=1.68\%$ , respectively). **CONCLUSIONS.** The correspondenceless technique provides a simple and efficient alternative to standard morphological analysis methods to quantify anatomical variations. In the future, this method could be used to characterize and detect changes in the shapes of the carpal bones caused by pathology or injury.

## Abstracts - Poster Presentations Session 2 continued

SOOKNANAN, Naveen, Nadia SOLOMON, Prerana RODRIGUES, Gillian RICHMOND, Sara SULAIMAN<sup>2</sup> and James COEY<sup>1</sup>. <sup>1</sup>Department of Anatomy, St. George's International School of Medicine; Drill Hall, Faculty of Health and Life Sciences; Northumbria University, Newcastle upon Tyne, NE1 8ST, UK; <sup>2</sup>Department of Applied Sciences, Faculty of Health & Life Sciences, Northumbria University, UK.

### Guyon's Canal: An anatomical study of ulnar nerve and artery by the use of ultrasound.

**INTRODUCTION.** The ulnar neurovascular bundle passes through a fibro-osseous tunnel, Guyon's canal, to reach the hand. Pathological reductions in the size of the canal can compress the ulnar neurovascular bundle, resulting in functional deficits distal to the lesion. While ultrasound has proven useful to clinicians for visualizing wrist structures within the carpal tunnel, it has seldom been used to anatomically map the contents of Guyon's canal. This project aims to assess the efficiency of ultrasound in visualizing neurovascular structures in Guyon's canal and conduct anatomical studies in vivo. **METHODS.** Thirty-two wrists from sixteen participants (11 male, 5 female) were examined using a Sonosite Micromaxx ultrasound machine and L38e/10-5MHz transducer. Measurements were taken in the first part of Guyon's canal proximal to the bifurcation of the ulnar artery and nerve including: the distance between the lateraledge of the pisiform and the medialwall of the ulnar (i) artery; (ii) nerve; and (iii) scaphoid tubercle. Wrist circumference was measured. **SUMMARY.** The ulnar nerve and artery were easily identified lateral to the pisiform bone in Guyon's canal by ultrasound. The ulnar nerve was found coursing medial to the ulnar artery in all participants. The ulnar nerve and artery were found  $5.4 \pm 1.0$  mm and  $8.3 \pm 1.3$  mm respectively from the lateral edge of the pisiform. Additionally, strong correlations were found the wrist circumference and the distance between the ulnar artery and nerve ( $r = 0.620$  [0.408-0.778] p-value, 0.00). **CONCLUSIONS.** Anatomical variations in Guyon's canal are well reported in the literature. Based on our observations, no variations in the anatomy of the neurovascular structures in Guyon's canal were noted; however, ultrasound proved to be an effective and quick tool to conduct anatomical studies. The morphometric values obtained in this study can help establish typical parameters for the neurovascular structures in Guyon's canal.

VASS, Caleb A., Samuel ANTHONY, Natalie R. SHIRLEY. Anatomy Department, Lincoln Memorial University-DeBusk College of Osteopathic Medicine, Harrogate, TN, 37752, USA.

### The effects of total hip arthroplasty on femur length and enthesopathy.

**INTRODUCTION.** The aim of this study is to determine normal variation in femur length and compare it to variation in femur length following total hip arthroplasty (THA). This study also documents the boney response to THA in the form of enthesopathies (calcifications or ossifications at tendon and ligament attachments). We hypothesize that THA causes greater than normal femur length discrepancies, leading to enthesopathy as the musculoskeletal system accommodates. **METHODS.** Maximum femur length and bicondylar length were measured bilaterally on 29 individuals who underwent THA and on 30 non-pathological femoral pairs from the University of Tennessee William M. Bass Donated Collection. Mean percentage difference in length was calculated for each group. Three muscle and ligamentous attachment sites were scored visually: lesser trochanter, greater trochanter, and intertrochanteric line. Enthesophytes were classified as absent/mild, moderate, or severe. Marginal homogeneity tests were used to compare enthesopathy on left versus right femora in the control sample and on THA versus non-THA femora. **SUMMARY.** The mean percentage difference in maximum and bicondylar length was 0.88% and 0.77%, respectively, for the control sample and 1.30% and 1.27% for the THA sample. No pattern was detectable in post-THA femur length discrepancies; in some individuals the THA femur was longer, and in others the non-THA femur was longer. Bilateral enthesophyte development was significantly different in the THA sample on the lesser trochanter ( $p = .005$ ) and intertrochanteric line ( $p = .009$ ). Asymmetry in enthesophyte development was also detected on the intertrochanteric line in the control sample ( $p = .034$ ). **CONCLUSIONS.** Femur length discrepancies are greater in individuals who have undergone THA. Leg length discrepancies create several inter-related problems for patients including altered gait, muscle tension, the potential for low back pain, and enthesopathy.

## Abstracts - Poster Presentations Session 2 continued

VIENNEAU, Maxine D.<sup>1</sup>, Valera CASTANOV<sup>1</sup>, Diane TYCZYNSKI<sup>2</sup>, and Anne M.R. AGUR<sup>1</sup>. <sup>1</sup>Division of Anatomy, Department of Surgery, University of Toronto, Toronto, ON M5S 1A8, Canada; <sup>2</sup>The Michener Institute for Applied Health Sciences, Toronto, ON M5T 1V4, Canada.

### Biomechanical causes and structural changes associated with hallux valgus: A literature review.

**INTRODUCTION.** Hallux valgus (HV) is a common forefoot deformity characterized by the lateral deviation of the great toe at the first metatarsophalangeal (MTP1) joint that affects all age groups. A recent meta-analysis reported the prevalence of HV as 23% in juvenile and adult populations and 35% in individuals over 65. Multiple biomechanical factors have been suggested to result in HV, but the etiology is unknown. The purpose of this study was to conduct a literature review to provide an analysis of the etiology and structural changes associated with HV. **RESOURCES.** A systematic review of the literature was conducted to assemble the available data pertaining to current knowledge of the etiology and structural changes associated with HV. Medline, Google Scholar, PubMed, CINAHL, Scholar's Portal and Embase databases were searched to February 2015. **DESCRIPTION.** Several biomechanical etiologies were identified, including pes planus, hyperpronation of the foot and first digit hypermobility. Most studies were in agreement that these etiologies may result in stretching of the ligamentous structures associated with MTP1 joint. These ligamentous structures included the medial capsule, intrinsic medial collateral ligament of MTP1 joint and the medial sesamoid ligament. In other studies, a muscle imbalance between the abductor and adductor hallucis was thought to be the main factor in the development of HV. **SIGNIFICANCE.** This literature review summarizes the current hypotheses of the etiology of HV and the associated structural changes. Two main causative factors were identified: stretching of ligamentous structures and muscle imbalance. Further clinical anatomical study is needed to understand the underlying mechanisms causing HV.

VIRUPAKSHAMURTHY, Murlimanju B. Department of Anatomy, Kasturba Medical College, Mangalore-575004, Manipal University, Manipal, Karnataka, India.

### The width and thickness of the menisci of knee joint in South Indian cadavers.

**INTRODUCTION.** The allograft meniscal transplantation requires the proper sizing of the meniscus to prevent the complications due to the miss sizing. Due to this implication, the objective of the present study is to measure the width and thickness of the medial and lateral menisci in South Indian cadavers. **METHODS.** The present study included 23 adult cadaveric knee joints and 46 menisci were studied. The menisci were divided into 3 equal parts, the anterior 1/3, middle 1/3 and posterior 1/3 regions respectively. The width and thickness of the medial and lateral menisci were measured by using the Vernier caliper of 0.02 mm accuracy. **SUMMARY.** In anterior and middle third regions, lateral meniscus was wider than the medial meniscus ( $p < 0.05$ ). But in posterior 1/3 region medial meniscus was wider ( $p < 0.05$ ). The posterior 1/3 region of the medial meniscus was wider than its own anterior and middle 1/3rds ( $p < 0.05$ ). While in the lateral meniscus, the anterior and posterior 1/3 regions are of the same relative width ( $p > 0.05$ ) and they are greater than the middle 1/3 region ( $p < 0.05$ ). Related to the peripheral circumference thickness, the anterior 1/3 region of the medial meniscus is thicker than the lateral ( $p < 0.05$ ). The posterior 1/3 region of the medial meniscus is thicker than its anterior & middle 1/3rds ( $p < 0.05$ ). **CONCLUSIONS.** The present study has provided the morphometric data of the medial and lateral menisci with respect to their width and thickness at the anterior, middle and posterior regions. This data is important to the arthroscopic surgeons during the meniscus allograft transplantation.

## Abstracts - Poster Presentations Session 2 continued

WOODLEY, Stephanie. J, Natasha A.M.S. FLACK, Jill C. MUIRHEAD, and Samuel S. HAYSOM. Department of Anatomy, University of Otago, New Zealand.

Is ultrasound a valid and reliable method of measuring hip abductor volume in cadavers?

INTRODUCTION. Atrophy of the hip abductor muscles can occur in chronic conditions such as hip osteoarthritis and/or with increasing age. Evaluating hip abductor muscle morphometry using ultrasound may be a useful adjunct in the assessment and rehabilitation of hip joint function; however, no ultrasonographic volumetric data are available for gluteus medius (GMed), gluteus minimus (GMin) and tensor fascia lata (TFL). The aim of this study was to investigate the utility of ultrasound to measure hip abductor muscle volume, compared with magnetic resonance imaging (MRI) and dissection. METHODS. Eight hips from 4 male cadavers (mean age 86 years) underwent axial MRI and ultrasound. Muscle cross-sectional area (CSA) was measured at multiple, evenly spaced levels across the length of each muscle using OSIRIX. Volumes were estimated from CSA using Cavalieri's equation. Limbs were then dissected to obtain fascicular length and volume, to determine overall muscle volume. Mean data were compared between muscles, and methods, using Student's paired t-tests. Intra-rater reliability of the image analyses and of data obtained from repeat ultrasound scans were assessed with intra-class correlation coefficients (ICC). SUMMARY. Ultrasonographic volume data were unobtainable for GMin. Hip abductor muscle volumes varied between limbs and specimens, but were significantly different from one another, for all modalities (GMed: ~205cm<sup>3</sup>; GMin: ~70cm<sup>3</sup>; TFL: ~35cm<sup>3</sup>,  $p < 0.05$ ). Volume differences between methods were not statistically different. Intra-rater reliability for image analyses was almost perfect (ICCs  $\geq 0.98$ ) but was variable for analyses of repeat ultrasound scans (ICC, GMed: 0.80; TFL: 0.08). CONCLUSIONS. Ultrasound may be a valid and reliable alternative to MRI for determining GMed and TFL muscle volume. For future research, the accuracy of ultrasound to measure hip abductor muscle morphometry in participants of different ages and activity levels should be considered.

## Abstracts – Poster Presentations Session 3

(listed by presenting author last name)

ABBATIELLO, Thomas<sup>1</sup>, Malcolm ANTOINE<sup>1</sup>, Peter ABRAHAM<sup>1,2</sup>. <sup>1</sup>St Georges University school of medicine, WI, USA; <sup>2</sup>Warwick University Medical school, Coventry, West Midlands CV4 7AL, United Kingdom.

Art and anatomy, Vitruvian man- Two sexes.

INTRODUCTION. Closer inspection of Leonardo da Vinci's Vitruvian man, strongly suggest the portrayal of both sexes. Craniofacial structures, breast development, pubic hair, and female reproductive organs; are the features which, on careful inspection give us clues to the portrayal of the female sex which has previously been overlooked. Recent interest was sparked in the asymmetry of the groin region, it being attributed to an inguinal hernia. A closer look suggests that this might in fact be an ovary. In the context of modern anatomical knowledge of the female anatomy this may be missed. We therefore aimed to separate the individual features of the Vitruvian man in an attempt to assess the degree of sexual dimorphism. RESOURCES. A comprehensive review of da Vinci's anatomical studies reveals staggering synchronicity with his understanding and the uniqueness of his stylized rendering of female anatomy further establishes the correlation. The eminent da Vinci scholar Martin Kemp has described the Vitruvian man in part as "philosophical anatomy"; in this regard da Vinci's direct reference to Plato's Soul mate creates a contextual imperative for gender duality. DESCRIPTION. da Vinci's study of motion and superimposition is attributed to account for the asymmetry and multiple limbs; it would be naïve to consider this an exclusion of his other fascinations, and rather than limit the potential of his genius we garner further reverence for his masterful abilities. For over five centuries Leonardo da Vinci's inclusion of the female anatomy has been over looked; this radical reinterpretation supports a deeper appreciation of the artists intentions. Clearly there is more to be explored of ancient art and its relevance to anatomy. SIGNIFICANCE. This novel interpretation may lead us to an undiscovered a dynamic representation of the human body in one of the most iconic anatomical drawings ever created.

*continued on next page*

## Abstracts - Poster Presentations Session 3 continued

ABRAHAMS, Peter<sup>1,2</sup>, Letsogile NGWALONGWALOT, and Justine SCHOBBER<sup>3</sup>. <sup>1</sup>St Georges University school of medicine, WI; <sup>2</sup>Warwick University Medical school, Coventry, West Midlands CV4 7AL, United Kingdom; <sup>3</sup>UPMC Hamot, 201 State Street, Erie, PA 16550

### Art and anatomy, two professions, same story.

INTRODUCTION. The Rothschild's tiger nudes which have of late been of interest to art historians are a classic example of the many enthralling art pieces with remarkable details of anatomy. These were left unsigned and as a result, admirers were left puzzled about who this anatomically knowledgeable artists may have been. The adventure to attribute these art pieces consequently highlights the existing symbiosis between art and anatomy, and more specifically, the link that exists between anatomy and ancient art; which has not yet been fully appreciated. RESOURCES. Many well known artists from the early 16th century, who lived pre- Vesalius, produced drawings and incredible sculptures which exist in modern time museums and libraries. They have remarkable accuracy and detailed anatomy which appeals to both anatomists and historians. Mainly looking at nude sculptures and the portrayal of the genitalia on these, interesting details are evident which now help us to attribute many of these great works of art. DESCRIPTION. Size of the penis; circumcision; pubic hair, its distribution, shape and form; all are the features which give us clues of attribution for the pieces not yet accredited.. A close look suggests that the Rothschild's tiger nudes might in fact have been created by Michelangelo. SIGNIFICANCE. There is more to be explored of ancient art and its relevance to anatomy. This may lead us to yet undiscovered methods these artists used to understand anatomy before Vesalius revolutionised the "evidence –based" world of anatomy in 1543. Furthermore, perhaps renaissance art may be a tool of the future to be used in facilitating clinical anatomy education.

ARMS, Lauren E.<sup>1</sup>, David L. MEALIEA<sup>1</sup>, Darlene E. PETERSON<sup>1</sup>, Allison L. CIOLINO<sup>1</sup>, Sarah J. GREENE<sup>1,2</sup>. <sup>1</sup> University of Vermont College of Medicine, Burlington, VT 05456; <sup>2</sup>Department of Pathology and Anatomy, Morehouse School of Medicine, Atlanta, GA, 30314

### An anatomical study of Kartagener's syndrome.

INTRODUCTION. Situs inversus totalis (SIT) and primary ciliary dyskinesia (PCD) are two rare findings that can occur concomitantly in a condition known as Kartagener's syndrome (KS). The classic triad of KS consists of situs inversus, chronic sinusitis, and bronchiectasis. Patients with KS can experience numerous clinical manifestations due to underlying malformations and abnormal ciliary function. The purpose of this study was to perform an anatomical exploration of a whole body donor with KS. RESOURCES. The donor underwent a CT scan of the thorax, abdomen, and pelvis. A detailed anatomical dissection followed and histological sections were taken from the bronchi and bronchioles (BB). DESCRIPTION. CT scans confirmed SIT. Dissection revealed that all major structures in the thorax, abdomen, and pelvis were reversed in nearly textbook form. Abdominal sutures indicated previous surgery, however no surgical interventions were evident. The left-sided ascending colon was located intraperitoneally. Bilateral variations in the medial pectoral nerves were present. The fibular artery was absent on one side. Gross evaluation of the lower respiratory tract revealed marked dilatation of the major B-B bilaterally. Histologic sections revealed active bronchiectasis with acute and chronic inflammatory exudate involving the walls of the BB, areas of necrotizing ulceration and desquamation of the epithelial lining, as well as emphysematous changes and patchy pulmonary edema of the alveolar spaces. SIGNIFICANCE. Increased knowledge of the anatomic and histological findings found in patients with KS could improve our understanding of the underlying structure that physicians might encounter when treating a patient with KS.



## Abstracts - Poster Presentations Session 3 continued

BEE, Mary, Ami PATEL, Sheila PUTNAM, and Taylor MARSHALL. University of Detroit Mercy, Detroit, MI 48223  
Variations in the distances from the major to minor duodenal papilla and pylorus.

INTRODUCTION. Endoscopic Retrograde Cholangiopancreatography (ERCP) and other investigative procedures of the duodenum require injection into the major duodenal papilla or observation of nearby anatomical structures. As a result, a solid understanding of the distances of the major duodenal papilla to both the pylorus and the minor duodenal papilla is essential when examining in this region. The major duodenal papilla of Vater is the location where the main pancreatic duct of Wirsung and the common bile duct exit via the hepato pancreatic ampulla at the sphincter of Oddi. Typically superior and anterior to the major duodenal papilla lies the minor duodenal papilla, which drains the accessory pancreatic duct of Santorini. The major duodenal papilla has been reported to lie at a distance of 8 cm from the pyloric sphincter and 2.0 cm from the minor duodenal papilla. METHODS. In three-year study of twenty four cadavers, distances between these landmarks were quantified. SUMMARY. We have observed that the 8 cm distance from the pylorus to the major duodenal papilla is accurate. However, the 2 cm distance from the major to the minor duodenal papilla is significantly shorter than what has been previously recorded in most textbooks and journals ( $p < 0.05$ ). CONCLUSION. This study provides insight into the accurate distances of the duodenal structures.

CASIER, Craig B., Benjamin TURNER, R. Shane TUBBS, Marios LOUKAS. Department of Anatomical Sciences, St. George's University, Grenada, West Indies.  
Supernumerary muscles of the pectoral and axillary regions: A systematic review and meta-analysis.

INTRODUCTION. Supernumerary muscles located in the pectoral and axillary regions may be traced back to abnormal development of the hypaxial part of associated somites. This has resulted in many morphologic muscular variants, regarding origin and insertions, vascular and nerve supply. In the literature these muscles include, but are not limited to: pectoralis quartus, costohumeralis, chondroepithrochlearis and sternocoracoideus. With the advent of medical imaging, the clinical importance of this group of muscles has been re-emphasized. The aim of this study therefore is to provide a comprehensive analysis of supernumerary muscles of the pectoral and axillary regions limited to the muscles whose origins are anterior to the mid-axillary line. METHODS. A systematic review of the literature in which these supernumerary muscles were identified was conducted. This comprised of case studies, clinical and cadaver prevalence's including the identification of origin/insertion, vascular and nerve supply, and morphometric analysis of the dimensions of each variant. SUMMARY. A meta-analysis of the supernumerary muscles was performed which included the prevalence of vascular and nerve supply, as well as the dimensions of each variant. These data were correlated with clinical conditions related to these variations. CONCLUSIONS. This review will allow the correct identification of these muscular anomalies, especially in surgical procedures of the axilla such as axillary lymphadenectomy and sentinel node biopsy, as well as in procedures that require dissection of the axilla where neurovascular structures could be compromised.

GIEFER, Kristen Y., Barth W. WRIGHT, and Ashley M. OLSON. Department of Anatomy, Kansas City University of Medicine and Biosciences, Kansas City, MO 64106, USA.  
Assessing the relationship between levator ani nerve length and pelvic floor dysfunction.

INTRODUCTION. This report describes the existence of a correlation between levator ani nerve (LAN) length and the transverse diameter of the pelvic outlet. As the distance between ischial tuberosities increases, LAN length also increases. RESOURCES. 23 female cadavers were utilized for this study. The LAN was found via gross dissection after hemisection of the pelvis was performed. Nerve measurements were taken from their point of origin from the pelvic wall to their insertion into the pelvic floor musculature. The ischial tuberosities were stripped of their soft tissue attachments and the hemisected pelvis were re-approximated to measure the intertuberosity distance. DESCRIPTION. In each case, the LAN received contributions from the anterior rami of spinal nerves S3 and S4, or from S4 alone. It coursed forward in an anteromedial direction and then

*continued on next page*

## Abstracts - Poster Presentations Session 3 continued

disappeared as it pierced the iliococcygeus muscle deep to the pelvic parietal fascia. The portion of nerve that was not covered by muscle, but lying just deep to the pelvic parietal fascia, was accepted as LAN length for this study. The intertuberos distance was taken as the diameter between the inferomedial-most aspect of the ischial tuberosities. The correlation between ischial tuberosity breadth and LAN length was found to be significant ( $p < 0.05$ ). SIGNIFICANCE. This correlation is significant for obstetricians and gynecologists, and surgeons who should be aware that a longer LAN length may increase the risk for stretch injury during vaginal birth, or transection during gynecologic and rectal excision procedures. Thus, consideration of an increased intertuberos distance may help to inform decisions about the birthing process and other pelvic surgical procedures that may lessen the risk for developing pelvic floor dysfunction.

HUA, Nathan, Velma A RAWLINS, MD. Peter A. BELLOT, MD. Riad K BANKUSLI, Kunwar P KAUR, Astrid I CARRIÓN RODRÍGUEZ, Meghan E GUTHRIE, Sanjay SINGH, Aisha S ATHAR, Amber N USRY. Ross University School of Medicine, 2300 SW 145th Avenue, Suite 200, Miramar, FL 33027, USA.

### Lymphadenopathy investigation: an interdisciplinary approach to studying chronic lymphocytic leukemia.

INTRODUCTION. The dissection of human cadavers provides an essential learning experience for medical students. Besides this experience, obvious anatomical abnormalities raise curiosity as to the possible cause of death. In one such case in the anatomy laboratory at Ross University School of Medicine, the presence of enlarged lymph nodes was of particular interest. The aim was to determine whether or not this was indeed the cause of death as this would provide understanding and stimulate integrative study of gross anatomy, histology and pathology as a learning experience. METHODS. Lymph nodes measuring 3 cm in length in the cadaver of a 90 y/o African American female were harvested and taken to the histo-pathology laboratory for students to investigate gross anatomical and histological changes. Tissue samples were processed using the histological methods available including embedding in paraffin blocks, sectioning to 5  $\mu$ m and staining using the hematoxylin and eosin staining protocol. SUMMARY. Our results were reviewed by the Pathology department and determined to be consistent with chronic lymphocytic leukemia (CLL). This finding led us to research the epidemiology of the disease, current prognosis, available treatments, progression and staging, genetic predisposition, mutations, and the latest articles on the disease. Later, the anatomy department confirmed our finding from the cadaver's record, which indicated that the cause of death was accredited to CLL. CONCLUSION. Investigating the cause of death provides integrative understanding of both gross anatomy and histology. Furthermore, the investigation gave our team hands-on experience in preparing tissue slides for histological investigation. Additionally, this provided a platform to integrate the pathophysiology material taught in the classroom with the gross anatomical and histopathological findings, and interdisciplinary collaboration.

IWAN, Tom M.<sup>1</sup>, Michael SUNDERLAND<sup>1</sup>, James HAMIL<sup>2</sup>, Kiarash TAGHAVI<sup>3</sup>, and S. Ali MIRJALILI<sup>1</sup>. <sup>1</sup>Department of Anatomy with Radiology, Faculty of Medical and Health Sciences, University of Auckland, Auckland, New Zealand; <sup>2</sup>Department of Paediatric Surgery, Starship Hospital, Auckland, New Zealand; <sup>3</sup>Department of Paediatric Surgery, Royal Children's Hospital, Brisbane, QLD, Australia.

### Surface anatomy of the central venous structures in neonates.

INTRODUCTION. Thoracic surface anatomy has previously been revisited in adults using computed tomography (CT) imaging. There is relatively limited information on the thoracic surface anatomy in the neonatal population. Understanding central venous anatomy in neonatal patients is imperative for cardiothoracic surgery and accurate central venous catheterization. Neonatal cardiac surgery is technically more difficult and carries a higher risk of complications. The aim of this study was to investigate key central venous structures in neonatal population using CT imaging. METHODS. After excluding patients with distorting space-occupying lesions; high resolution thoracic CT scans from 50 supine neonates (range 0-2 years) were analyzed using dual consensus to investigate the key surface anatomy of the central venous structures. SUMMARY. Preliminary results suggest the origin of the brachiocephalic veins to be most

*continued on next page*

## Abstracts - Poster Presentations Session 3 continued

commonly located directly behind the head of the clavicle (60%). The formation of the superior vena cava (SVC) was most commonly located at the right 2nd costal cartilage (40%) and right 1st costal cartilage (40%). Furthermore, the SVC/RA junction was most commonly located at the right 3rd and 4th costal cartilage (25% and 35%, respectively). CONCLUSIONS. This is the first study to map the central venous structure in neonates. With pediatric interventional radiology procedures becoming increasingly common, accurate location of these structures is imperative for safe clinical practice. Surface anatomy must be accurate and evidence-based.

JORGENSEN, Adam<sup>1</sup>, Brett GARDINER<sup>1</sup>, Alistair HILTON<sup>1</sup>, H. Wayne LAMBERT<sup>2</sup>, and Jonathan J. WISCO<sup>1,3</sup>.

<sup>1</sup>Brigham Young University, Provo, UT 84602, USA; <sup>2</sup>West Virginia University School of Medicine, Morgantown, WV 26505, USA; <sup>3</sup>University of Utah School of Medicine, Salt Lake City, UT 84132, USA.

MRI reconstruction and 3D print of coronary vessels to aid in coronary bypass preoperative teaching and preparation.

INTRODUCTION. Coronary artery disease (CAD) has the highest mortality rate of chronic illnesses internationally, affecting 13 million people in the United States alone. The disease is characterized by a buildup of plaque in the coronary vessels, preventing the proper flow of blood to the heart. We have implemented an MRI reconstruction technique that allows for 3D printing of the vessels on the heart. This technique could be implemented to aid thoracic surgeons in the preoperative teaching and preparation for open-heart procedures. RESOURCES. We have acquired a pathology-free human cadaveric heart specimen from the West Virginia University School of Medicine (WVUSOM) Human Gift Registry, acquired high-resolution MR images, and segmented the images using Amira software. We 3D printed our rendered images at the Brigham Young University rapid prototyping lab. DESCRIPTION. Using rapid prototype (RP) technology, we used an accessible process to produce a physical 3D model from specific MRI data of the heart. Our methods consisted of three phases: (1) image acquisition via T1- and T2-Turbo Spin Echo (TSE) protocols using voxels of 0.6x0.5x0.9 mm and 0.4x0.3x3.0 mm; (2) post-processing image segmentation and data rendering in Amira, and (3) RP on acrylonitrile butadiene styrene (ABS) plastic. SIGNIFICANCE. Procedural treatment of progressed forms of CAD can require invasive coronary artery bypass grafts. While surgeons become proficient at performing the procedures through years of experience and training, some have begun utilizing 3D printing to gain exposure to the unique 3D architecture of the patient's heart preoperatively. The value of this process could be enhanced by presenting the patients their own 3D printed heart. The surgeon could teach the procedural process, as well as highlight anatomical variations encountered in clinical cases for residents, patients, and other developing members of the surgical team.

KAUFFMAN, Travis H, Amanda L OSTERLOH, Anthony B OLINGER. Department of Anatomy, Kansas City University of Medicine and Biosciences, Kansas City, MO 64105, USA.

Characterizing the superior vena cava to confirm central venous catheter location on radiographs.

INTRODUCTION. The placement of central venous catheters (CVCs) is a common hospital procedure, and chest radiographs are regularly used to confirm correct placement. Failure to place CVCs in the correct position can result in failure of the CVC and complications which may be fatal. Radiologists use a variety of landmarks seen on imaging to accurately determine the location of CVCs, however, factors such as image exposure, x-ray beam angle and active disease processes within the thorax may make accurate reads difficult. This study characterizes the superior vena cava and its tributaries in relation to the posterior ribs and carina in order to assist with accurate interpretation of CVC placement. METHODS. Data was collected from 38 embalmed cadavers previously dissected at Kansas City University and University of Nebraska Medical Center. The posterior rib level of the brachiocephalic-superior vena caval junction (BSJ), azygos vein opening (AVO) and cavoatrial junction (CAJ) were recorded by using the anterior-posterior plane to simulate a portable chest radiograph. The distance of the BSJ, AVO and CAJ from the carina was recorded. SUMMARY. The BSJ was most commonly located at the level of the posterior 3rd rib and at or before the posterior 3rd intercostal space (ICS) in 37/38 specimens. The AVO was most commonly located at the posterior 5th ICS and at or between the 4th

*continued on next page*

## Abstracts - Poster Presentations Session 3 continued

and 5th posterior rib in 32/37 specimens. The CAJ was most commonly located at the 5th ICS and at or before the level of the 6th posterior rib in 27/38 specimens. The average distances from the BSJ, AVO and CAJ to the level of the carina were 4.2cm inferiorly, 1.3cm inferiorly and 1.4 cm superiorly, respectively. CONCLUSION. The relationships seen between the structures studied can be used by radiologists to confirm proper placement of CVCs. The carina is a common landmark already used, but can be difficult to see. In these cases, the posterior ribs serve as reliable landmarks which can also be used.

KO, Jong Bum<sup>1</sup>, Rohit SACHDEVA<sup>2</sup>, Gyung won SON<sup>3</sup>, and Soo Y. KIM<sup>2</sup>. <sup>1</sup>College of Kinesiology, University of Saskatchewan, Saskatoon, SK S7N 5B2, Canada; <sup>2</sup>School of Physical Therapy, University of Saskatchewan, Saskatoon, SK S7S 0W3, Canada; <sup>3</sup>College of Medicine, University of Saskatchewan, Saskatoon, SK S7N 5E5, Canada.

### Reliability and validity of fiber bundle length measurements of the pectoralis major: in vivo ultrasound imaging.

INTRODUCTION. Tightness, scarring and weakness of the pectoralis major (PM) as a result of cancer extirpation or reconstructive surgery is common in breast cancer survivors. Stretching of the PM is an integral part of rehabilitation. Despite the reported benefits of stretching, clinicians currently rely on indirect measures to monitor changes of PM in response to treatment and rehabilitation. The aim of this study was to test the reliability and validity of a novel ultrasound imaging protocol developed to quantify fiber bundle lengths (FBL) of the PM. METHODS. Thirty healthy participants (19 females/ 11 males) with no previous history of shoulder injury or dysfunction were recruited (mean age  $26.7 \pm 6.1$  years). Participants were supine on a plinth with the head of bed inclined  $35^\circ$ . Major bony landmarks (acromion, lateral lip of the intertubercular groove, sternum) were identified on each participant. Two investigators independently scanned the superior portion of the sternocostal head of the right PM of each participant on two separate occasions. The panoramic imaging mode of a LOGIQ e ultrasound unit (12 MHz transducer) was used. The PM was scanned with the arm in three positions: by the side of the body, and at  $40^\circ$  and  $60^\circ$  of glenohumeral abduction. Each investigator independently measured FBL of PM on saved images. Pearson product-moment correlation coefficients were computed to determine intra- and inter-rater reliability of measurements. SUMMARY. Intra- and inter-rater reliability of measurements was strong ( $r > 0.80$ ) and highest with the arm at  $40^\circ$  of abduction. Mean FBL ( $15.49 \pm 0.85$  cm) were in agreement with measurements from cadaveric specimens ( $15.0 \pm 0.80$  cm) from a previous modeling study. CONCLUSIONS. This newly developed ultrasound imaging protocol may be a useful technique to monitor muscle length changes of PM in breast cancer survivors. This may in turn improve treatment techniques targeted for the PM and reduce shoulder dysfunction.

MIKO<sup>1</sup>, Michal, Ivan VARGA<sup>1</sup>, Stefan POLAK<sup>1</sup>, Lenka ORAVCOVA<sup>1</sup>, Lubos DANISOVIC<sup>2</sup>. <sup>1</sup>Institute of Histology and Embryology; <sup>2</sup>Institute of Medical Biology, Genetics and Clinical Genetics, Faculty of Medicine, Comenius University in Bratislava, Slovakia.

### Ultra-structural morphology of long-term cultivated white adipose tissue-derived stem cells.

INTRODUCTION. White adipose tissue is now considered as an active and important endocrine organ, site of wide array of immunologically active cells, all this with serious implications for practice. Recently, adipose tissue has been reported as a source of adult mesenchymal stem cells with wide use in regenerative medicine and tissue engineering. We focused our research on exploring the issues of isolation and long-term cultivation of mesenchymal stem cells obtained from adipose tissue. METHODS. White adipose tissue samples have been obtained from abdominal subcutaneous fat tissue of five healthy adult women, who underwent liposuction, then, isolation and cultivation of adipose tissue derived mesenchymal stem cells (ATSCs) was performed. Each time after reaching 90% confluence, the cells were sub-passaged in 1:3 ratios. ATSCs were cultivated up to 30 passages. Subsequently, cells of each generation were assessed by cytometry, inverted light microscope and transmission electron microscope. SUMMARY. Morphological analysis in all passages revealed an ultrastructure typical for cells with high level of proteosynthesis. Ultra-structure of ATSCs in the early passages, with typical

*continued on next page*



## Abstracts - Poster Presentations Session 3 continued

numerous lipid droplets and centrally localized nuclei was similar to multi-locular adipocytes which formed the brown adipose tissue. The cytoplasm of cells from the higher passages contains high number of lamellar electron-dense structures, which filled out almost the entire cytoplasm. CONCLUSION. None of the publications described ultrastructural morphology of long-term cultivated (ATSCs) – this is where we hope to see the biggest impact of our research. Extreme plasticity of adipose tissue is partially provided by adipose tissue mesenchymal stem cells, leaving aside a direct trans-differentiation of fully differentiated adipocytes by the stimuli that induce genetic expression reprogramming and through it a change in phenotype and, consequently functions. (Supported by grant No. APVV-0434-12.)

MIRJALILI, S. Ali.<sup>1</sup>, Kiarash TAGHAVI<sup>2</sup>, Geoff FRAWLEY<sup>3</sup>, and Susan CRAW<sup>4</sup>. <sup>1</sup>Department of Anatomy with Radiology, Faculty of Medical and Health Sciences, University of Auckland, Auckland, New Zealand; <sup>2</sup>Department of Paediatric Surgery, Royal Children's Hospital, Brisbane, Qld, Australia; <sup>3</sup>Department of Paediatric Surgery, Royal Children's Hospital, Melbourne, Vic, Australia; <sup>4</sup>Department of Radiology, Dunedin Public Hospital, Dunedin, New Zealand.

### Should we abandon landmark-based techniques for caudal anesthesia in neonates and infants?

INTRODUCTION. Caudal anesthesia is a landmark-based technique with ultrasound guidance occasionally used in the absence of landmarks. The current surface landmark remains a popular approach due to its desirable success rate. However, incomplete ossification of the posterior vertebral elements can make this procedure for neonatal caudal anesthesia difficult. The aim of this study was to describe the anatomical relationship of the posterior superior iliac spines (PSISs) to the sacral cornua in infants using ultrasound. METHODS. A total of 26 healthy infants (17 female; mean age 13 weeks) were scanned by a radiologist in the prone position with hip and knee joints flexed. The PSISs and sacral cornua were identified clinically then using ultrasound to assess whether these markings corresponded with the clinical markings. The distance between the PSISs and the distance between the tip of the PSIS and tip of the sacral cornu were measured using ultrasound. SUMMARY. The PSISs were clinically identified in all babies, but the sacral cornua were not palpable in four babies (15%). The PSISs and sacral cornua were easily visualized using ultrasound in all participants. The mean distance between the two left and right PSISs was  $3.4 \pm 0.5$  cm; the mean distance between the PSISs and cornu was  $2.5 \pm 0.5$  cm on the left and right. CONCLUSIONS. This study showed that the current landmark (equilateral triangle) for infant caudal anesthesia is unreliable. Importantly, the sacral hiatus is clinically identifiable only if the sacral cornua are palpable; otherwise, using ultrasound is essential.

NATKA, Vitaly<sup>1</sup>, David HORN<sup>1</sup> and Brion BENNINGER<sup>1,2</sup>. <sup>1</sup>Medical Anatomy Center, Departments of Medical Anatomical Sciences, Neuromuscular Medicine, Family Practice, Western University of Health Sciences, COMP-Northwest, Lebanon, OR. USA; <sup>2</sup>Orthopaedic and General Surgery residency faculty, Samaritan Health Services, Corvallis, OR. USA.

### Percuision: DirectVision camera guided urinary catheterization training during medical students anatomy lab.

INTRODUCTION. Urinary catheterization (UC) is a common procedure practiced in hospitals in short, and long stay wards, healthcare of the elderly homes, and the emergency room. UC is a procedure that 3rd and 4th year medical students preform minimally, if at all. It is often performed by residents on patients with no previous experience. The objective of this study was to investigate whether DirectVision UC skills can be taught in the anatomy lab to first year medical students. METHODS. A literature search was conducted regarding UC during a first year medical anatomy. A 3-way catheter with DirectVision was used in 5 males & 4 females donor cadavers by 30 students. A Likert scale questionnaire was conducted. SUMMARY. Literature search reveals no known studies using DirectVision in an anatomy lab. UC was unsuccessful in 2 males due to narrowing or occlusion. 3 males and 4 females allowed a soft 3-way catheter to be successfully introduced. All students were successful with DirectVision UC in the anatomy lab. 15-25% of hospitalized patients receive UC. UC is often performed by a trainee without previous instruction and repetition. There are some synthetic simulators, but they are not very realistic and do not reveal the anatomy of the urethra in detail. Failed UC by a trainee results

*continued on next page*



## Abstracts - Poster Presentations Session 3 continued

in a urology consult. Instead of a urologist being faced with a difficult UC they are often sorting out a damaged urethra due to poor trainee technique. Visualizing the urethra would allow a trainee to stop before causing urethral damage. CONCLUSION. This study revealed DirectVision skills for UC can be successfully acquired by 1st year medical students during an anatomy lab course.

NGUYEN, Vuvi H.<sup>1</sup>, Howe LIU<sup>2</sup>, Armando ROSALES<sup>1</sup>, and Rustin REEVES<sup>1</sup>. <sup>1</sup>Department of Integrative Physiology and Anatomy, <sup>2</sup>Department of Physical Therapy, University of North Texas Health Science Center, Fort Worth, TX 76107, USA.

### Anatomical observation of the dorsal scapular nerve- A series of cadaver study.

INTRODUCTION. The impingement of the dorsal scapular nerve (DSN) often leads to shoulder weakness and scapular pain that radiates to the lateral aspect of the arm and forearm. This nerve originates from a branch of the root of C5 in the brachial plexus and typically pierces the middle scalene muscle to innervate the levator scapulae, rhomboid minor, and rhomboid major muscles. Due to its anatomical location, the DSN is difficult to dissect and thus, is not often shown to medical students in lab. In this project, the DSN is dissected in 3 cadavers in order to show and educate medical students on its spinal root origin, anatomical route, and muscle innervations. RESOURCES. Studies were conducted on 3 embalmed adult Caucasian cadavers in which the origin, anatomical route, and muscular innervations of the DSN were dissected and documented. DESCRIPTION. It was found that the DSN originated from C5 spinal nerve root in two cadavers whereas in one cadaver, the DSN branches from the spinal nerve root of C4. The route of the DSN varies either by passing anteriorly to the scalene muscles (seen in two cadavers) or piercing through the middle scalene muscle (seen in one cadaver) in order to travel posteroinferiorly to its targeted muscles. As observed, the DSN also showed variation in its innervations. This nerve innervated only the rhomboid minor and major muscles in one cadaver and in the other two cadavers, the DSN innervated both the rhomboid muscles and the levator scapulae muscle. SIGNIFICANCE. The variations of the DSN spinal contribution, route, and muscle innervations are identified in this study. Such variations will truly help clinicians become better aware of its anatomy in order to make the appropriate diagnosis and treatment plan to patients with pain related to dorsal scapular nerve impingement.

NWOSU Ijoma A.<sup>1</sup>, Andrew J. MILLER<sup>1</sup>, Luke CARLSON<sup>1</sup>, Frank SCALI<sup>1</sup>, Dennis J. WARFIELD JR.<sup>1</sup>, Meghan TORNATORE<sup>1</sup>, Jose PEREZ-GUMA<sup>1</sup>, Lance G. NASH<sup>1</sup>. <sup>1</sup>Department of Anatomy, embryology and histology, American University of the Caribbean (AUC), Cupecoy, St. Maarten, Dutch West Indies.

### Transramic obturator artery: a normal human variant in Dutch and American cadavers I

INTRODUCTION. Clinically important variants of the OA can arise from either the external iliac or its branches, rarely from femoral artery, and traverses the posterior aspect of the superior pubic ramus. This particular course leaves the vessel exposed to both iatrogenic and traumatic compromise and has been called the corona mortis or crown of death. This makes it a considerable challenge to all specialists who operate in the retro-inguinal region (of Bogros), whether it is arterial, venous or both. The aims of this study are to analyze variants of the obturator artery (OA) and obturator vein (OV) in Americans and Dutch cadavers, and to propose a change in nomenclature and classification. METHODS; 275 formalin-fixed adult human cadavers from the Netherlands (Holland) and the United States of America, donated to the medical school for medical education and research, were dissected between January 2011 and November, 2014. There were 124 males (65 American and 59 Dutch), 151 females (76 Americans and 75 Dutch) and the ages ranged from 21 – 98 years with an average of 81.58. There was no history of vascular surgical intervention in any of the cadavers. A hemipelvectomy was performed on each cadaver at the level of bifurcation of abdominal aorta. Bilateral hemi-pelves were dissected. At the end the two sides were compared, recorded and photographed for similarities and differences. While there were 275 cadavers dissected, the total number of dissected pelvic vessels (arteries and veins) were 499 single obturator vessels, (264 in the American cadavers and 235 in the

*continued on next page*

## Abstracts - Poster Presentations Session 3 continued

Dutch cadavers). The American and Dutch prevalences compared well with our meta-analysis prevalence of 26.64%. DESCRIPTIONS; The two sub-populations show similarities principally in anterior division of internal iliac artery and inferior epigastric, but differ in the rare origins of OA, and transramic obturator vein. SIGNIFICANCE; This study and the meta analysis that shows other studies since 1817, agree that there are racial, intra-racial and ethnic differences, as well as a high frequency of OA from sources other than the IIA – over 25% world-wide, implying that corona mortis is a variant and not an anomaly nor is it aberrant.

OLSON, Ashley M., Kristen Y. GIEFER, Kenna B SCHNARR, and Anthony B. OLINGER. Department of Anatomy, Kansas City University of Medicine and Biosciences, Kansas City, MO 64106, USA.

### Characterization of the Inferior Vena Cava to improve IVC filter placement and longevity.

INTRODUCTION. Congenital or interrupted (a developmental defect of the inferior vena cava and collateral circulation) malformations of the IVC are the two major pathologies of the IVC. Both can cause significant stenosis of the IVC. The major clinical implication of IVC stenosis is an increased risk for deep venous thrombosis. Because other pathologies, such as angulation, also lead to turbulent flow it would lead us to be this would also lead to an increased risk in DVT formation. An increased risk in DVT formation necessitates placement of an IVC filter. The filter is susceptible to tilt, a major complication in which the filter is no longer in the center of the IVC. This study aims to characterize the IVC in the hopes of improving IVC filter placement and longevity. RESOURCES. A total of 80 cadavers were used for this study. The IVC was accessed using gross dissection. The branching pattern of the IVC was recorded. The distance between the major branches was measured. The distance from the hepatic veins to the renal veins and the distance from the renal veins to the right gonadal vein were measured. The distance from the renal veins to the bifurcation of the IVC was also measured. The angulation of the IVC was recorded. DESCRIPTION. To characterize the IVC, including branching pattern, the distance between the major branches, and angulation of the IVC in relation to the long axis of the body. SIGNIFICANCE. IVC filter placement is currently problematic due to the major complication of tilt. This occurs when the filter shifts in the IVC so its midpoint, which contains a small hook for removal in the future, is no longer in the center of the IVC. Characterizing the IVC in relation to its unique branching patterns and angulation variations allows for more straightforward IVC filter placement thus increasing its longevity and minimizing complications.

OSTERLOH, Amanda, Stanley WIGGINS, and Anthony OLINGER. Kansas City University of Medicine and Biosciences, Kansas City, Missouri, 64106, USA. Mercy Clinic Cardiology & Clinical Cardiac Electrophysiology, Springfield, Missouri, USA.

### Anatomical data can aid in clinical decisions regarding 'left atrial appendage closure devices'.

INTRODUCTION. Determining a correlation between the size of the left atrium and the left atrial auricular os (LAAO) would be beneficial in treating patients with persistent atrial fibrillation (AF) in the prevention of stroke. Several medical device companies have developed 'left atrial appendage closure devices' designed to prevent stroke in patients with persistent AF. These devices are deployed over the LAAO, where thrombotic emboli most frequently develop in the setting of AF. In finding the proposed anatomical correlation, clinicians could then determine the appropriate sized 'left atrial appendage closure device' preoperatively to use for the procedure. Also, this information could aid in determining if a further intervention may be indicated after use of the closure device, given the increase in the size of the left atrium over time due to AF. To the best of our knowledge, there is no anatomical data to aid in these clinical decisions. METHODS. The left atrium was measured from anterior to posterior atrial walls and from right to left pulmonary vein. The inside diameter of the LAAO was measured. Area of the left atrium was calculated and correlated to the size of the LAAO. SUMMARY. There was a positive correlation between the area of the left atrium and the diameter of the LAAO, such that as the area of the left atrium increased so too did the diameter of the LAAO. CONCLUSIONS. Given these findings clinicians can now determine preoperatively the appropriate size of a 'left atrial appendage closure device' to ensure a positive outcome. Also, clinicians can predict that as the left atrium enlarges over

*continued on next page*

## Abstracts - Poster Presentations Session 3 continued

time due to the pathogenesis of atrial fibrillation, so too will the LAAO, despite the closure device. Therefore, repeat echocardiograms are indicated to monitor the stability of the device and determine if further interventions are necessary to prevent thrombotic emboli from dislodging from behind the previously placed device.

OTOBO, M. Tarimobo and TARIMOBO-OTOBO Rugina. Department of Anatomy, Niger Delta University, Wilberforce Island, Bayelsa State, Nigeria.

### The suspensory ligament of the ovary versus the ovarian ligament; a semantic conundrum.

INTRODUCTION. Anatomical terminologies with ambiguity cause difficulty in clinical translation when morphological nomenclature does not match functional meaning. This scenario has limited the understanding of a clinical subject, for which it could have been a mere translation of basic anatomy. RESOURCE. A review of the gross anatomy of the uterus during an obstetrics clerkship and subsequent laparoscopic visualization of the pelvis, revealed students difficulty in identifying the suspensory ligament of the ovary and the ovarian ligament based on basic science reference. Besides, while students misrepresented the suspensory ligament of the ovary, the clinician named it the infundibulopelvic ligament. DESCRIPTION: The ovarian ligament attaches proximally to the posteriorinferior part of the uterotubal junction and distally to the superiomedial part of the ovaries, while the suspensory ligament of the ovary, is a lateral thickening of the broad ligament on each side of the uterus and attaches to the lateral walls of the pelvis. Students identified the ovarian ligament as the suspensory ligament of the ovaries, due to its attachment and orientation in the pelvis relative to the ovaries, using geometric deductions of the axis of the ovarian ligament attachments and the implied function as suggested by the term suspensory ligament. SIGNIFICANCE. Basic anatomy as a foundation for clinical translation is the bases of the anatomy curriculum, in this regard, identifying the suspensory ligament of the ovaries are of clinical significance in vascular ligation when necessary and caution during pelvic surgeries. Therefore, there is need for anatomical references to be in unison and an unequivocal anatomical terminology of the suspensory ligament and ovarian ligament.

OVEYSSI, Justin O., Ravi PIRYANI, and Anthony B. OLINGER. Department of Anatomy, Kansas City University of Medicine and Biosciences, Kansas City, MO, 64106, USA.

### Relating aortic annulus to the femoral and subclavian arteries.

INTRODUCTION. TAVI (trans-thoracic aortic valve implantation) is a new surgical technique that is used for replacing stenotic aortic valves. A replacement valve may be delivered by way of the femoral or subclavian arteries, or through the thoracic wall. There are several contraindications for this procedure. One contraindication is an aortic annulus diameter greater than 27mm or less than 18mm. The aortic annulus is located at the aortic root at the level of the aortic valves. This study seeks to determine how often the aortic annulus diameter falls outside of this recommended range for suitable TAVI candidacy. In addition, we are looking to see if there is a correlation between the diameters of the aortic annulus, femoral, or subclavian arteries in order to establish whether or not one measurement is a reliable predictor of the other in an individual. RESOURCES. The aorta was dissected at the aortic root and the aortic valve was removed. Diameter of the aortic annulus was measured using an electronic caliper. DESCRIPTION. Diameters of the subclavian arteries were measured bilaterally at the level of the first rib. Femoral artery diameters were measured bilaterally two inches inferiorly from the ilioinguinal ligament. Diameters of the aortic annulus as well as the femoral and subclavian arteries were compared. Linear regression was performed to determine if there was a positive correlation between any of the measurements. SIGNIFICANCE. Identifying a positive correlation between these measurements may have surgical implications for the TAVI approach to aortic valve replacement. Several of the cadavers measured had aortic annulus diameters outside of the recommended range for TAVI. In addition, we identified several correlations between measurements that may indicate a preference for one form of TAVI over another in a surgical candidate. The results of this study should assist surgeons in minimizing risk in surgical candidates.

*continued on next page*

## Abstracts - Poster Presentations Session 3 continued

PALMER, Laura, Thomas R. GEST, and DolgorBAATAR. Paul L. Foster School of Medicine, TTUHSC, El Paso, TX, USA.

### Should hemorrhoids be considered a complication of portal hypertension?

**INTRODUCTION.** In some textbooks for medical students, hemorrhoids are listed as a complication of portal hypertension. However, the role of portal hypertension in the pathogenesis of hemorrhoids remains elusive. It is well known that portal hypertension leads to the development of porto-systemic shunts, which may present as esophageal and/or rectal varices. The aim of this study was to elucidate the distinctions between hemorrhoids and rectal varices. **METHODS.** We performed analysis of 56 papers that compared different aspects of rectal varices and hemorrhoids and their relation to portal hypertension. We also compared microscopic appearance of hemorrhoidal plexuses with that of rectal submucosal veins in tissue samples obtained from 6 cadavers. **SUMMARY.** The literature analysis showed that the prevalence of hemorrhoids in patients with portal hypertension is same as that in the general population, suggesting that portal hypertension does not play a role in the pathogenesis of hemorrhoids. In contrast, rectal varices were found almost exclusively in patients with portal hypertension. In addition, clinical presentation and, importantly, treatment strategy of these two entities differ substantially. Histologic analysis revealed that vessels within hemorrhoidal plexuses contain significantly less smooth muscle cells compared to rectal submucosal vessels. However, large amounts of free smooth muscle cells, which are not associated with vessels, have been found within the hemorrhoidal plexuses. **CONCLUSIONS.** Hemorrhoids and rectal varices are two distinct entities with different morphology, pathophysiology, clinical manifestations, and treatment. Rectal varices, but not hemorrhoids, are associated with portal hypertension. These results suggest that hemorrhoids should not be considered a complication of portal hypertension and textbooks needs to be revised accordingly.

PFEIFFER, Jacob F. Clive C. PERSAUD Devon S. BOYDSTUN Amanda L. OSTERLOH Kristin COLYER Ashley OLSON Anthony B. OLINGER Kansas City University of Medicine and Biosciences, Department of Anatomy, Kansas City MO, 64106, USA.

### Characterization of the coronary arteries to improve aortic replacement surgery.

**INTRODUCTION:** In the presence of aortic root disease, aortic replacement (AAR) has been the standard of therapy since 1962. With advances in ARR, experienced surgical centers can still incur mortality from 2-6%. Tension, buckling, torsion, or malpositioning of the coronary buttons can lead to myocardial ischemia, ventricular arrhythmias, myocardial infarction, or pump failure. Knowledge of the exact location of the coronary arteries may lead to a decrease in morbidity and mortality associated with AAR. **RESOURCES:** The hearts of 25 embalmed cadavers (16 female, 9 male) were removed during routine lab dissection. Each heart was cleaned to remove any excess fat surrounding the aorta and coronary arteries to enable a clear view. The height from the aortic root at which the right and left coronary arteries branched was measured using digital calipers. The axis of the heart was determined to be from the midpoint of where the pulmonary veins enter the left atrium to the apex of the heart. From this axis, the angle at which the right and left coronary arteries branched was measured using a goniometer. These values were recorded for later statistical analysis. **DESCRIPTION:** The average distance from the aortic root to the left and right coronary arteries were 12.32mm and 9.32mm respectively. Distances were 11.23mm and 8.83mm for the left and right coronary arteries respectively in males. Distances were 12.94mm and 9.59 mm for the left and right respectively in females. The average angle from the axis of the heart was determined to be 73° and 52.24° for the left and right coronary arteries respectively. The mean angles for males were determined to be 73.11° and 53.22° for the left and right coronary arteries respectively. Angles for females were 72.94° and 51.69° for the left and right coronary arteries respectively. **SIGNIFICANCE:** This information can serve to be useful for Physicians that are involved in patients requiring ARR to help increase the rate of success.

## Abstracts - Poster Presentations Session 3 continued

RICHMOND, S. R. Gillian<sup>1</sup>, Peter BOSHARA<sup>1</sup>, Gaston HABIB<sup>1</sup>, Grace NASRI<sup>1</sup>, Prerana RODRIGUES<sup>1</sup>, Nadia SOLOMON<sup>1</sup>, Naveen SOOKNANAN<sup>1</sup>, James COEY<sup>1</sup> and Sara SULAIMAN<sup>2</sup>. <sup>1</sup>Department of Anatomy, St. George's International School of Medicine; Drill Hall, Faculty of Health and Life Sciences; Northumbria University, Newcastle upon Tyne, NE1 8ST, UK; <sup>2</sup>Department of Applied Sciences, Faculty of Health & Life Sciences, Northumbria University, UK;

### Viewing the ganglion impar in vivo utilizing ultrasound: A feasibility study and literature review.

INTRODUCTION. "Ganglion impar" is the final unpaired ganglion demarcating the caudal convergence of the sympathetic chain ganglia in the pelvic region of the human body. The general position of the ganglion impar is anterior to the coccyx, but both researchers and practitioners note significant variability in its location, size and shape. Direct visualization of the ganglion by ultrasound has not been carried out to date. Cadaveric studies have been informative, but limited in their ability to sufficiently assist physicians in non-invasively locating and targeting the surprisingly inconsistent ganglion impar for clinical procedures in patients.

RESOURCES. Literature on the ganglion impar is scarce. Cadaveric studies focusing on ganglion impar anatomy describe variations in the ganglion's size and location. Clinical studies show that ganglion impar nerve block, with varying degrees of success, can result in significant pain relief in patients with coccydynia and other forms of pelvic pain. A recently published case report involved an innovative ultrasound guided approach was attempted in this study. DESCRIPTION. This study utilized ultrasound to investigate the ganglion impar in one subject in both prone and transverse positions to assess its sonographic visibility and anatomical morphology. However, by the use of this technique the ganglion structure was not visualized. SIGNIFICANCE. Failure to view the ganglion in both positions suggests that the ganglion impar cannot be visualized using ultrasound in this case study. Previous studies used ultrasound to monitor needle insertion targeting ganglion impar, but not specifically to visualize the ganglion itself. This may help explain the variations seen in therapeutic outcomes and pain relief after administration of nerve blocks. The use of other landmarks, such as the coccyx and sacro-coccygeal junction, might be more useful in locating the ganglion impar.

RODLER, Daniela, and Fred SINOWATZ. Institute of Anatomy, Histology and Embryology, Department of Veterinary Sciences, University of Munich, D-80539 Munich, Germany.

### Localization of stem cell and differentiation markers in prostate cancer and benign prostatic hyperplasia.

INTRODUCTION. Recent reports of cancer stem cells have prompted questions regarding the involvement of normal stem/progenitor cells in prostate cancer. Although still controversial, the cancer stem cell may be a target in the treatment of prostate cancer and a thorough understanding of its biology might allow it to be targeted selectively and eliminated. Recent work on immunophenotyping of prostate cancer supports the hypothesis that prostate cancer arises from malignant transformation of stem cells. METHODS. The present study was performed on 12 cases of prostatic adenocarcinomas of varying Gleason grades and 35 cases of benign prostatic hyperplasia (BPH) of men between 45 and 82 years old. The aim of our study was to localize several stem cell (Oct4, NANOG, Sox2, CD133) and basal cell markers (cytokeratins 5, 14, 18). Additionally immunostaining of prostatic specific antigen (PSA) and androgen receptor (AR) was performed. Transmission electron microscopy was used to demonstrate the changes of epithelial and stromal cells during their transformation to malign (prostate cancer) and benign (BPH) tumor cells. SUMMARY. A positive immunostaining for Oct4 and for CD133 was found in all prostatic carcinomas, whereas samples of BPH were consistently negative. No positive staining was found for Sox 2 or NANOG, neither in prostatic carcinoma nor in BPH. Staining was positive in BPH for the basal cell markers CK5, CK14 and CK18. PSA and AR expression varied significantly in prostatic carcinomas whereas it was regularly and distinctly expressed in the secretory cells of BPH. CONCLUSIONS. The results obtained show that markers of stem cells are found in prostatic carcinomas, which could be used for isolation of prostatic stem cells. On the other hand, the observed differences in immunophenotyping between basal cells in PBH (negative for Oct4 and CD133) and prostate cancer cells could question the role of basal cells in the development of prostate cancer.



## Abstracts - Poster Presentations Session 3 continued

SOLOMON, Danielle, Penelope BURIKAS, Ian BOWERS, and Anthony OLINGER. Kansas City University of Medicine and Biosciences. Kansas City, MO, 64118, USA.

### Examination of the Intercostal Nerve and Branch Points: A Cadaveric Study.

INTRODUCTION. Thoracentesis can result in neuralgia as a result of severing the branches of the intercostal nerve. The present study aimed to investigate a safe zone as a better entry points for procedures. METHODS. Human cadavers were selected for the study. With the cadavers in the supine position, each intercostal space was dissected out with careful examination of the intercostal nerves and branches. Any nerve branch seen or nerve that crossed midline was pinned so that measurements could be taken. Calculations were performed to identify a safe zone for each intercostal space. The measurements were reviewed comparing each intercostal space in order to recommend the safest intercostal space. RESULTS. After thorough dissection of each intercostal space, the safest zone for instrument insertion was found to be in spaces 4 and 7, 120 mm from midline on the right side. CONCLUSIONS. Based on this cadaveric study, Intercostal spaces 4 and 7, 120 mm from midline on the right side resulted in infrequent severing of any branches of the intercostal nerve, and would be a more suitable location for instrument placement in thoracentesis and VATS procedures.

VAN SCHOOR Albert-Neels<sup>1</sup>, Marius C BOSMAN<sup>1</sup>, and Adrian T BOSENBERG<sup>2</sup>. <sup>1</sup>Department of Anatomy, School of Medicine, Faculty of Health Sciences, University of Pretoria, Pretoria, South Africa. <sup>2</sup>Department of Anesthesiology and Pain Management, University of Washington and Seattle Children's Hospital, Seattle, USA. Study of the differences in the level of the conus medullaris in four different age groups.

INTRODUCTION. In performing neuraxial procedures, knowledge of the location of the conus medullaris in patients of all ages is important. The aim of this study was to determine the location of conus medullaris in a sample of newborn/infant cadavers and sagittal MRIs of children, adolescents and young adults. METHODS. The subjects of both the samples were subdivided into four developmental stages. No statistical difference was seen between the three older age groups ( $p > 0.05$ ). A significant difference was evident when the newborn/infant stage was compared with the other, older stages ( $p < 0.001$  for all comparisons). SUMMARY. In the newborn/infant group the spinal cord terminated most frequently at the level of L2/L3 (16%). In the childhood stage, the spinal cord terminated at the levels of T12/L1 and the lower third of L1 (21%). In the adolescent population, it was most often found at the level of the middle third of L1 and L1/L2 (19%). Finally, in the young adult group, the spinal cord terminated at the level of L1/L2 (25%). This study confirmed the different level of spinal cord termination between newborns/infants less than one year old and subjects older than one year. In this sample the conus medullaris was not found caudal to the L3 vertebral body, which is more cranial than the prescribed level of needle insertion recommended for lumbar neuraxial procedures. CONCLUSION. It is recommended that the exact level of spinal cord termination should be determined prior to attempting lumbar neuraxial procedures in newborns or infants.

VARGA, Ivan, Michal MIKO, Stefan POLAK and Lubos DANISOVIC. Faculty of Medicine, Comenius University in Bratislava, Slovakia.

### The clinical significance of interstitial Cajal-like cells and their role in tissue regeneration.

INTRODUCTION. The Spanish neuro-histologist, Santiago Ramón y Cajal in 1893 discovered a new cell type in the muscle layer of the gut. After about half a century, electron-microscopic examinations of the wall of digestive tube re-discovered these cells and they got the new name "interstitial cells of Cajal". They have been recognized as an important element in the regulation of gastrointestinal motility. RESOURCES. The presence of cells similar to interstitial cells of Cajal (so-called interstitial Cajal-like cells, ICLCs) is not restricted only to gastrointestinal tract. They can be found in various organs, for example in the urinary bladder, prostate, mammary gland, uterus, Fallopian tube, placenta, liver, exocrine pancreas, lungs, bone marrow, heart and some blood vessels. Although no mention about these cell populations is made in the official terminology, in the Terminologia Histologica. DESCRIPTION. Currently, with using of methods of immunohistochemistry, the

*continued on next page*

## Abstracts - Poster Presentations Session 3 continued

identification of ICLCs is not so difficult. Immunohistochemistry on formalin-fixed paraffin-embedded tissues is performed using monoclonal antibodies for CD117/c-kit. In our article we present an overview about ICLCs in different organs completed with own microphotographs. SIGNIFICANCE. In general, ICLCs have different functions based on their anatomical localization. For example, ICLCs in the heart improve cardiac function (they are "nursing" cardiac stem cells), participate in neo-angiogenesis and decreasing cardiac fibrosis in pathological conditions. ICLCs play also possible role in liver, kidney and skin regeneration. In other organs, ICLCs are involved in intercellular signaling and have strategic position among target cells, capillaries and nerve fibers. In the future, ICLCs could be used as a source of cellular therapy to enhance repair of numerous damaged tissues and organs. (This study was supported by grant of the Slovak Research and Development Agency No. APVV-0434-12.)

VARGA, Ivan<sup>1</sup>, Zuzana CIERNA<sup>2</sup>, Ludovit DANIHEL<sup>2</sup>, and Michal MIKO<sup>1</sup>. <sup>1</sup>Institute of Histology & Embryology; <sup>2</sup>Institute of Pathology, Faculty of Medicine, Comenius University in Bratislava, Slovakia.  
Different types of placental trophoblasts: New terminology and clinical significance.

INTRODUCTION. Trophoblast is composed of different subpopulations of cells. Cytotrophoblast represents stem cells whereas syncytiotrophoblast is the terminally differentiated multinucleated cell mass that produces pregnancy-associated hormones and regulates the diffusion of respiratory gases, nutrients and waste products between mother and embryo/fetus. Recent years, mostly in pathological and gynecological literature term "intermediate trophoblast" was introduced. RESOURCES. After entering the term „intermediate trophoblast“ in the database PubMed more than 150 scientific articles appear, but there is no mention about it in Terminologia Embryologica. DESCRIPTION. Intermediate trophoblast (IT) represents heterogeneous cell population with different features. Villous IT consists of cells larger than cytotrophoblast cells, with pale cytoplasm and single uniform round nucleus. They are localized in trophoblastic columns of anchoring villi. IT of implantation site consists of mononucleate or multinucleate cells with abundant eosinophilic cytoplasm. The nuclei have irregular outlines; they are lobulated, with multiple deep clefts. The main function of this type of cells is remodeling of maternal arteries in the basal plate and establishment of materno-fetal circulation. Chorionic-type IT consists of uniform mononucleate or multinucleate cells with eosinophilic to clear cytoplasm. It is located in the chorion laeve of fetal membranes. One of the functions of this type is production of extracellular matrix, which provides elasticity and strength to the fetal membranes. SIGNIFICANCE. The fact that some forms of gestational trophoblastic diseases arise from IT gives us evidence that IT represents separate group of trophoblastic cells. Implantation site IT is trophoblast subpopulation from which placental site trophoblastic tumor and exaggerated placental site arise. Chorionic-type IT is a source for epithelioid trophoblastic tumor and placental site nodule and plaque.

WEINHAUS, Anthony J. Department of Integrative Biology & Physiology, University of Minnesota Medical School, Minneapolis, MN 55455, USA  
Revisiting the anatomy of the superior surface of the respiratory diaphragm.

INTRODUCTION. On a recent consulting engagement with a new start-up company, a study was conducted in an attempt to deploy a novel device through the respiratory diaphragm – while avoiding all vascularization - in a location lateral to the heart. This proposed study was conducted subsequent to the examination of widely-used, prominent, anatomy atlases (N=4) that show clearly that this area was free of blood vessels. RESOURCES. Adult human cadavers were dissected, observed, and photographed. Un-fixed (no procedures except refrigeration) (N = 4, both sides of 2 specimens) and Formaldehyde-fixed (whole body perfusion via arterial access) cadavers (N=32, both sides of 16 specimens). DESCRIPTION: Examination of formaldehyde-fixed cadavers suggested that the superior surface of the diaphragm was free of vessels. However, advancing the study to unfixed specimens suggested a much different result. It was discovered that branches of three major vessels run across the superior surface of the respiratory diaphragm – Internal thoracic, Pericardiophrenic, and Superior Phrenic. SIGNIFICANCE. The observation of the presence of these vessels

*continued on next page*

## Abstracts - Poster Presentations Session 3 continued

lead to the termination of the study. The presence of these vessel running across the surface of the diaphragm would be too dangerous for such a procedure, and a completely new protocol for this device to be devised. The majority of atlases of Human Anatomy need to be up-graded to show the presence of vessels on the surface of the respiratory diaphragm. Anatomy students, anatomists, and clinicians should be aware of their presence to prevent medical errors in teaching and practice. The absence of the vessels in atlases may be the result of the variability in visualization of the vessels between un-fixed and formaldehyde-fixed cadavers. The donors are gratefully recognized for their immense contribution to education and research.

WRIGHT Jonathon<sup>1</sup> and Brion BENNINGER<sup>1,2</sup>. <sup>1</sup>Medical Anatomy Center, Departments of Medical Anatomical Sciences, Neuromuscular Medicine, Family Practice, Western University of Health Sciences, COMP-Northwest, Lebanon, OR. USA; <sup>2</sup>Orthopaedic and General Surgery Residency faculty, Samaritan Health Services, Corvallis, OR. USA.

### Developing a surface anatomy landmark ratio to identify kidneys in cadavers with finger ultrasound.

INTRODUCTION. Ultrasound (US) has become an essential skillset in emergency medicine and gaining importance throughout healthcare today. Gradually, US is being introduced into clinical years of medical school and less so during the basic science curriculum. The demand to learn US is greater than available training. The objective of this study was to investigate if a consistent landmark could be identified from donor cadavers (DC) using a bimanual US probe to view the kidney. METHODS. Literature search was conducted regarding US landmarks identified from DC's. 20 DC (40 sides) and 20 healthy volunteers as controls had measurements collected using the xiphoid process, clavicle, midaxillary line and iliac crest landmarks to ascertain if a ratio could be created for a consisted location to place the US probe footplate . Fukuda Denshi UF-760AG ultrasound machine and SonicEye biplanar probe was used. Each subject was labeled with a body habitus of lean, moderate or heavy. SUMMARY. Literature search revealed 1 study on live subjects using a classic probe. Palpable bony surface landmarks could be consistently identified from DC's and controls. A ratio was created between bony landmarks enabling a consistent location for the US footplate to be placed with DC's and controls. Ultrasound is a valuable tool and identifying landmarks to aid novice users to locate common structures and spaces could expedite skillsets and efficiency. CONCLUSION. This study revealed that a ratio from the palpable bony landmarks of the xiphoid process and iliac crest while including the midaxillary line could be successfully used to place an US probe footplate which would view the kidney.

## Abstracts – Poster Presentations Session 4

(listed by presenting author last name)

BARASH Alon, NISSIM Hila, KARASIK David. Faculty of Medicine in the Galilee, Bar Ilan University, Safed, Israel.  
A rare case of acute formaldehyde allergy in the dissection room.

INTRODUCTION. Formaldehyde is an organic compound with wide chemical use mainly in the textile and wood industry. When dissolved in water it forms the hydrate formalin, which is customarily used in preservation and fixation of biological tissues, including human cadavers. Easily evaporating ,formalin is a known irritant of mucous membranes, and the US National Toxicology Program described formaldehyde as known to be a human carcinogen. Therefore, in virtually all medical schools that use cadavers for dissection, some kind of ventilation system is used to minimize exposure to formaldehyde, to a maximum of 0.3 parts per million (ppm). RESOURCES. In our newly established facility, downdraft tables are installed, as well as high number of total room air-volume circulations are maintained. Over the four years of activity, tests never captured formaldehyde levels in excess of 0.25ppm. Anatomy course runs for 2 months including

*continued on next page*

## Abstracts - Poster Presentations Session 4 continued

about 50 hours of dissection lab. The course begins with the thorax, continues to abdomen, pelvis, head & neck and limbs & back. DESCRIPTION. Hours after completion of the last abdomen lab, a student developed an acute asthma like syndrome, although she does not suffer from asthma. Coincidentally she was tested for formaldehyde exposure that same lab, which was found well below the maximum at 0.04ppm. The severance of the attack was such that required hospitalization. The student was treated with corticosteroids and adrenalin and was given inhalations. About a month later, during neuroanatomy lab, the student, at her request entered the dissection room with eye and mouth protection, but about 10 minutes later, left the dissection room as she began to feel the same symptoms mainly eye irritation and difficulty breathing. SIGNIFICANCE. Along with being the first case in our experience (from several medical schools), review of the literature did not reveal any such extreme case involving medical students. Care must be taken to insure the safety of all students during lab; the effect might start hours after exposure, as seen in this case

BARRACK, Daniel<sup>1</sup>, David HORN<sup>1</sup>, Brion BENNINGER<sup>1,2</sup>. <sup>1</sup>Medical Anatomy Center, Departments of Medical Anatomical Sciences, Neuromuscular Medicine, Family Practice, Western University of Health Sciences, COMP-Northwest, Lebanon, OR. USA; <sup>2</sup>Departments of Surgery, Orthopaedics & Rehabilitation, Oregon Health & Science University, Portland, OR. USA.

Timed visual text guide for skill acquisition of the Sectra Visualization Table.

INTRODUCTION. The Sectra Visualization Table (SVT) is a computer that allows a user to view CT and MRI imaging rendered in 3D, which can be filtered in a tissue specific manner and manipulated using a touch screen for educational and clinical purposes. SVT is an extremely useful medium, but it is unclear how long it takes for a novice operator to become proficient. The objective of this study was to develop a training document (VTG) which includes strong visual cues for efficient processing of the SVT's use while addressing andragogical methods. METHODS. Literature search was conducted regarding SVT and medical student (MS) curriculum. 30MS were given 15 minutes to read the guide composed of illustrations with minimal text. Guide included step by step demonstrations of techniques, used to manipulate the CT/MRI image. Subsequently, they were allowed to manipulate images with the touch screen. Further 10 controls were chosen. Their proficiency of 17 tasks manipulating 3-D images was assessed. SUMMARY. No obvious studies were identified regarding the use of SVT with MS. MS successfully interpreted the guide, and used the techniques associated with manipulating images. The average assessment score was 15.5/17 per person. Following an anatomy dissection or didactic course, having access to manipulate 3-D CT/MRI images would enhance MS' understanding of stereostructural anatomy. MS will be exposed to their patients' imaging anatomy. SVT guide effectively enabled students to manipulate a CT/MRI on a 46 inch touch screen when compared to controls. CONCLUSION: This study revealed that a visual heavy teaching guide can enable MS to manipulate 3D CT/MRI images with minimal training.

BARTON, Scott T.<sup>1</sup>, Mark D. GARY<sup>1</sup>, Maria C. SAVOIA<sup>2</sup>. <sup>1</sup>Anatomical Services, Division of Medical Education; <sup>2</sup>Division of Medical Education, School of Medicine, University of California, San Diego, La Jolla, CA 92093, USA. Advantages of using a gravity embalming method: steps to reduce formaldehyde exposure and to increase employee productivity.

INTRODUCTION. The use of a gravity embalming method has several advantages in the operations of an anatomical preparation laboratory. In this study, the process of utilizing gravity embalming was evaluated and contrasted with an alternative, and more commonly utilized, mechanical approach. RESOURCES. A gravity embalming method utilizes a carboy with an attached flexible tube that terminates in an arterial vessel. A monitor kit was used to measure the formaldehyde exposure levels. DESCRIPTION. In this gravity embalming method, 12 gallons of a premixed embalming solution were pumped into a carboy. The cadaver was prepared by making a single incision superior to the right clavicle. Fluid was injected into a closed circulatory system through the right common carotid artery. Chemical exposure levels were monitored with a formaldehyde monitor kit to contrast exposure during normal gravity-fed operations versus a machine embalming process. SIGNIFICANCE. The exposure to formaldehyde during the gravity embalming method was dramatically reduced relative to the machine embalming. This exposure difference was attributed to employees not having

*continued on next page*



## Abstracts - Poster Presentations Session 4 continued

to mix the embalming solution, the lack of continuous drainage from the cadaver, and the dramatic reduction in time employees are working directly with the cadaver. Furthermore, time-savings to employees using this embalming method was also significant, utilizing one sixth of the time for the gravity embalming method relative to the traditional approach. We advocate the use of a gravity embalming approach for cadaver embalming due to the reduction in formaldehyde exposure and preparation time.

BERGEN, Hugo T., Alison M. LONGO, and Jason PEELER. University of Manitoba, Department of Human Anatomy & Cell Science, College of Medicine, Faculty of Health Sciences, Winnipeg, MB, Canada.  
Neuroanatomy education: evaluating methods of delivery on student opinions and academic performance.

INTRODUCTION. Medical schools have traditionally used a dissection-based approach for educating students in neuroanatomy. There is a trend towards increased use of prosected specimens, models, and 3-D imaging materials as learning resources. It is not known which method constitutes the most effective way to teach students a basic understanding of human neuroanatomy. The purpose of this study was to examine whether the method of educational delivery influences student perceptions about learning anatomy, as well as performance on a practical exam. METHODS. Undergraduate students from the same medical school were compared. One cohort was taught using a method that involved some dissection of brain specimens while the second cohort was taught using a method of delivery that employed more prosected specimens. Contact hours for both groups were similar. A standardized educational survey was used to collect information regarding student perceptions and evaluate 6 different methods of delivery. This data was compared against student performance on neuroanatomy practical exams. SUMMARY. Seventy students (dissection=40, prosection=30) completed the survey. Survey results revealed that teaching that used clinical cases was the most effective approach for relating anatomical structure to function, while the use of medical imaging was the most effective approach for instilling anatomical knowledge. When comparing the performance of students on the lab practical exam, the dissection group outperformed the prosection group (mean=83% vs 72%). The dissection group also outperformed the prosection group on exam questions that were given to both groups (mean=80% vs 76%). CONCLUSIONS. Data suggest that student perceptions and academic performance are influenced by the method of delivery, and that medical imaging and case based scenarios enhance the learning environment. The results will be used to guide the selection of delivery method in future neuroanatomy curriculum.

BISNATH, Carol<sup>1</sup>, Leslie NICKELL<sup>1</sup>, and Anne AGUR<sup>2</sup>. <sup>1</sup>Office of Health Professions, Student Affairs, Faculty of Medicine, University of Toronto, Toronto, ON M5S 1A8, Canada; <sup>2</sup>Division of Anatomy, Department of Surgery, University of Toronto, Toronto, ON M5S 1A8, Canada.  
Residents: Career mentors for medical students.

INTRODUCTION. Career mentorship begins on day one of medical school, and as such, often commences during the Anatomy portion of the curriculum, where Residents from a variety of backgrounds contribute to teaching. Despite this important role, the preparation and willingness of Residents to be career mentors has not been examined. RESOURCES. Residents (PGY 1-5) from the Neurology and Physical Medicine and Rehabilitation programs at the University of Toronto participated in two 20 minute discussion sessions exploring the Residents' perceived role as career mentors for the medical students. These sessions occurred prior to their annual Anatomy academic half-days. The Residents' comments were summarized and recommendations proposed. DESCRIPTION. All the Residents were asked career-related questions by 1st to 4th year medical students, but felt that they were not able to answer all the questions effectively without more knowledge of existing resources. Residents overwhelmingly commented that it was very challenging to find a single, focused and readily accessible career management resource, which is essential, given their time constraints. They also felt that they were not career mentors, but recognized that they played a more informal but important role in career exploration and specialty decision-making. The Residents themselves gave examples of good and bad mentorship they had received as medical students. SIGNIFICANCE. Residents do perceive themselves as having a role in helping medical students with career-related decisions. It is evident that there is a need for an online, succinct and easily accessible career exploration resource.

*continued on next page*



## Abstracts - Poster Presentations Session 4 continued

CAMPEAU, Lisa M. and Jason C. MUSSELL. Louisiana State University Health Sciences Center, New Orleans, LA 70112.

Evaluating the efficacy of a video dissection guide tailored to the Louisiana State University Health Sciences Center gross anatomy curricula.

**INTRODUCTION.** To close the educational gap due to low instructor:student ratios in gross anatomy labs, a new video dissector based on the text used at LSUHSC, Grant's Dissector 15th edition, is being created by the gross anatomy faculty. Currently available video guides are more demonstrative and less instructional, our goal is easing the perfunctory dissection burden by describing techniques and characteristic structures so critical dissection of historically difficult-to-identify structures can be performed more quickly with less damage. It is hypothesized that these LSU-specific videos will be of greater aid to students in identifying structures than guides already in existence or than written text alone. **METHODS.** To test this hypothesis, the class was divided into three groups: written dissector only, traditional anatomy video specifically Acland's Video Atlas of Human Anatomy, and LSU video dissection guide. Accuracy of structure identification was assessed by a simple questionnaire administered to all three groups. The students were to identify a given structure or it was to be located by the faculty. Also, video group assignment was compared to gross anatomy practical exam scores for each dissection block. **SUMMARY.** It was hypothesized that assignment to the LSU video dissection guide would result in higher practical exam scores than either other video group. Analysis of the data did not confirm this hypothesis in the three sets of questionnaires performed in the Fall 2014 medical gross and developmental anatomy course; however, it may be that additional data collection would isolate statistically significant differences in favor of one specific video group. **CONCLUSIONS.** While statistical differences did exist between the video groups, they were not consistently in favor of one group. It may be that if the video series was extended over more dissections the differences would become more prominent and numerically significant.

CANTWELL, Sean R., George F. BONADURER III, Wojciech PAWLINA, and Nirusha LACHMAN\*. Department of Anatomy, College of Medicine, Mayo Clinic, Rochester, MN 55905, USA.

A near peer-driven dissection selective: primer to a medical school anatomy course.

**INTRODUCTION.** Cadaveric dissection remains an important tool for teaching gross anatomy. In addition to its utility in learning anatomy, cadaveric dissection has also been shown to enhance students' spatial reasoning, ability to cope with stress, professionalism, and communication skills. Despite these benefits, widespread changes in medical school curricula have led to decreased time for gross anatomy and cadaveric dissection. A five-day dissection course led by second year medical students was offered to first year students as a selective option the week preceding the anatomy course. **RESOURCES.** Low-fidelity dissection models were used to introduce students to proper techniques in scalpel use, blunt dissection, separation of fascial planes, and structure identification. Participants were assigned regions on a cadaver, which they dissected while focusing on dissection techniques learned earlier that day. Clinical applications of dissection were emphasized through interactive presentations by faculty from departments of anatomy, radiology, and orthopedic surgery. On the final day of the course, students presented appropriate approaches and tips for dissecting specific regions of the cadaver. **DESCRIPTION.** This exercise used formally allocated student self-directed learning time to create, implement, and evaluate a novel, one-week pre-anatomy dissection course. A survey measuring students' understanding of dissection technique and comfort with dissection was administered prior to the dissection course, and during the first and final week of the anatomy course. **SIGNIFICANCE.** One week after the end of the dissection course participants demonstrated increased understanding of dissection techniques relative to their peers. Follow-up indicated that participants found the dissection course helpful and would strongly recommend it to their peers. The course was a student initiative based on student course evaluations and recommendations for enhancing the dissection experience.

## Abstracts - Poster Presentations Session 4 continued

CARMICHAEL<sup>1</sup>, Steven, Brion BENNINGER<sup>1,2</sup>, and Tom Schlundt<sup>1</sup>. <sup>1</sup>Willed Body Donation Program, Medical Anatomy Center, Departments of Medical Anatomical Sciences, Neuromuscular Medicine, Family Practice, Western University of Health Sciences, COMP-Northwest, Lebanon, OR. USA. <sup>2</sup>Orthopaedic and General Surgery residency faculty, Samaritan Health Services, Corvallis, OR. USA.

Comparing cadaver preparations for maximum imaging quality used for anatomy teaching courses, CME's and research.

INTRODUCTION. There is no equivalent substitute to the human body and therefore donor cadavers (DC's) are the ideal form for teaching medical anatomy, image mediums, invasive procedures and homogenous tissue research. There are several preparations one can choose to create the optimum form for a desired teaching effect. Teaching imaging in the cadaver lab is usually with images from live specimens, not cadavers being dissected and lacking interaction. The objective of this study was to assess which preparations would be ideally suited to conduct ultrasound (US) on DC's during a dissection lab. METHODS. Literature search was conducted regarding preparation types of DC's to optimize US use and skills. Fukuda Denshi UF-760-AG ultrasound system with 1. conventional, 2. endocavity, 3. finger and 4. 3D/4D probes were used on 4 separate DC preparations (fresh frozen-FF, Freedom Art-FA, Carolina-C, Western-W). Each DC had the identical limb and cavity structures imaged. Two separate examiners acquired images with each of the 4 probes. Images were analyzed for clarity by US superusers. SUMMARY. Literature search revealed no known studies comparing US probes with DC preparations. The FF (2-48hrs) and FA (14 days) revealed quality images with mobile joints prior to deterioration. C (1year) revealed acceptable images and the W (1 year) had less quality imaging while both had rigid immobile joints. FA provides more probe time then FF and easier to maintain, therefore ideal for Continued Medical Education and multiple body part courses. C provided higher quality images then W and would be suited for 1 year anatomy courses. CONCLUSION. This study revealed that FA is ideal for multiple probe US imaging and for mobile joint uses up to 14 days and C was ideal for multiple probe US imaging up to 1 year with immobile joints. Both aid stereostructural anatomy learning.

CRUTCHFIELD, Jay M. and John H. OLSON, Department of Anatomy, A.T. Still University School of Osteopathic Medicine, Mesa, AZ 85206.

A step towards change: The virtual anatomy lab.

INTRODUCTION. Across all curricula, cadaveric dissection has been challenged by decreasing dissection time and replacing this time-honored tradition of this activity with other means of instruction. Because of limited time, resources, and a waning disinterest in cadaveric dissection by our students, a 3D virtual anatomy lab, surgical videos, radiographs, and other technological innovations was introduced to supplement our anatomy curriculum. RESOURCES. An assay of available technology resulted in the institution of several 3D computer-based programs: Cyber-Anatomy (Elsevier, Inc.), VH Dissector (Toltech.net), BodyViz (Visual Medical Solutions, LLC), and 4D Anatomy (4D Anatomy, Inc.), are our premier products. Other products, such as actual operating-room video, online dissection guides, and other MP4 products are available also. A Panasonic 3D projector PT-DZ870 (Panasonic Corporation) was installed. DESCRIPTION. The use of 3D visualization, radiographic manipulation, DICOM-file rendering, and MP4 files supplements the students' education. SIGNIFICANCE. With today's technological innovations, most of the arguments supporting cadaveric dissection as the only tool in the education of future physicians and surgeons are no longer supported by the literature. The arguments supporting cadaveric dissection for the non-surgically-motivated medical student, who requires more knowledge of radiological visualization of the human body than actual hands-on dissection time, is now confronted with the reality of our technological world and its ability to supplement education. Further studies are needed to assess the impact this technology will have on the retention of student's anatomical and/or clinical knowledge and/or board-examination performances.

## Abstracts - Poster Presentations Session 4 continued

ENTEZAMPOUR, Mo, Paul LYONS, Kendrick DAVIS, and Chris MILLER. University of California Riverside School of Medicine, Riverside, CA 92521.

### Rê•Lif-ing: Exploring a Life in Death.

**INTRODUCTION.** Medical students enter a complex, dynamic, fast-paced healthcare system. Sound decision making in this clinical setting requires “critical thinking, time-sensitive action, and skilled-task performance”. This paradigm tends to marginalize humanity in medical education. Gross anatomy offers a unique opportunity of providing a counterbalance by having students regard their cadaver, or “donor-patient”, as their first patient and by exploring the life the donor-patient may have lived. **RESOURCES.** Rê•Lif-ing is a fivefold process: 1) The donor-patient’s medical history is inputted into a human patient simulator; subsequently, the simulator is allowed to die, witnessed by the students who will “attend to” this particular donor-patient’s body during their dissections; 2) A forensic pathologist presents a lecture on the tenets of cause-of-death determination, emphasizing observable clues that the donor-patient’s body may present; 3) Through guided-discovery and completing a multi-page questionnaire, students document pathologies and other physical findings that may have affected the donor-patient’s life; 4) Students spend a day at a coroner’s office working with forensic pathologists; and, 5) Students attend a donor-patient memorial service at the conclusion of their gross anatomy curriculum. **DESCRIPTION.** Rê•Lif-ing challenges medical students not only to garner anatomical knowledge, but also, based on the “clues” observed, to hypothesize about the life of their first patient. **SIGNIFICANCE.** Rê•Lif-ing provides medical students, in their role as final caregivers, with insights into the lives their donor-patients may have lived. This connection with the living person will help students embed a sense of humanity and compassion that will remain throughout their years of clinical practice.

FISHER, Dean R., Nicki HARRIS, Travis G. SIEMS, Alex RODRIGUEZ and Parviz KHOSHBAKHTAIN\* University of California Los Angeles, Los Angeles, CA 90095 USA and \*University of California Irvine, Irvine, CA 35233, USA.

### Using a database to track the demographics of preregistered donors to predict future trends in whole body donations.

**INTRODUCTION.** Databases have been used in Donated Body Programs for the past 25 years. Most of these databases contain statistical information to complete the Certificate of Death and supply information needed for educational and research projects, such as age, sex and cause of death. This study tracks the location, sex and age of the individual (pre-registrant) to predict future trends to the UCLA Donated Body Program. **METHODS:** Data was collected and entered into the Donor Digital Library database over a 5 year period from January 1st of 2010 to December 31st of 2015. During this period, one thousand, nine hundred and seventy two (1972) individuals signed forms to donate their remains to UCLA’s Donated Body Program. Information supplied by each pre-registrant included, birthdate, sex, and current location (city). This information was compiled and used to compare pre-registrants with deceased registrants (841) over the same period. A map was created to show the proximity of the individual relative to the University. **SUMMARY:** The information gathered in this study assists in predicting future budgeting and growth within the program. By averaging the age and sex of the individual and the proximity from which they live, this allows us to plan ahead and to predict whole body donation fluctuations within the program. **CONCLUSIONS:** Based on this study, we were able to gather statistical information on pre-registered and deceased donors. We compiled this data to compare and to better understand how fluctuations occur in the number of whole body donations received within a calendar year. We can now predict future trends and can expand our outreach programs in certain areas with this information.

## Abstracts - Poster Presentations Session 4 continued

GERWER, Johanna, Thomas GEST. Department of Medical Education, Texas Tech University Health Sciences Center Paul L. Foster School of Medicine, El Paso, Texas 79905, USA.

### Survey of body donor personal information provided to students attending medical school in the United States.

INTRODUCTION. Body Donor Programs in the United States face challenging issues in balancing ethical concerns and educational needs. Body donors give their bodies to be used for the education of future physicians. Each donation enables medical students to learn important anatomical structures and relationships. Beyond allowing basic science objectives to be fulfilled, body donations have the potential to provide additional learning opportunities. Students can realize increased empathy and gain greater insight into the patient experience. To accomplish this, however, students should be provided with body donor personal information including: demographics, background, and medical history. Currently, among Donor Programs in the U.S., there is great variability in the amount of donor personal information that is provided to students. The purpose of this study is to assess this variability among medical schools in the U.S. and to determine the reasons for restricting or providing donor personal information to students. RESOURCES. Telephone interviews and email surveys were used to collect information concerning the provision and use of donor personal information with students. DESCRIPTION. One hundred fifty-one donor programs in the U.S. were contacted via email or telephone interview or both. Fifty-three programs responded (35% response rate). The survey results show variation, not only in the amount of personal donor information provided to students, but also in the attitudes and beliefs of the donor program personnel concerning providing donor personal information to students. SIGNIFICANCE. This research documents the variability of the educational use of donor personal information. By demonstrating inconsistency, we hope medical schools are encouraged to increase the amount of donor personal information provided to students in order to enhance the development of important medical skills, while maintaining ethical standards.

GREENE, Sarah J.<sup>1,2</sup>, Amanda BECHTEL<sup>1</sup>, Lee ROSEN<sup>1</sup> <sup>1</sup> University of Vermont College of Medicine, Burlington, VT 05401 <sup>2</sup> Department of Pathology and Anatomy, Morehouse School of Medicine, Atlanta, GA 30310.

### The meaning of a convocation of thanks: Beyond the students.

INTRODUCTION. Every year, medical schools across the United States and abroad hold memorial ceremonies to honor anatomical donors. While the meaning of these ceremonies to students has received attention, the meaning to family members in attendance and to donor programs at large has not been addressed. The purpose of this study was to evaluate the impact of the Convocation of Thanks (CoT) on donor family members and the Anatomical Gift Program (AGP) at the University of Vermont (UVM). METHODS. Beginning in 2011, donor family members were invited to attend and participate in the annual CoT at UVM. Each year, a questionnaire was sent out to attendees after the ceremony to collect feedback about the ceremony. Inquiries and registration for the AGP were tracked to determine if there was a change in frequency during the months that followed each ceremony. SUMMARY. Between 2011-2014, 25 questionnaires were returned from family members in attendance, in addition to other forms of written feedback. The most common comments regarding family member experiences included gaining an understanding of the importance of anatomical donation of their loved one (n=10), as well as finding closure for their loss (n=7). There was no significant difference in the frequency of inquiries before and after the CoT. CONCLUSION. Data suggest that the CoT had a positive impact on closure of the loss of a loved one for family members, while also highlighting the importance of anatomical donation, which family members may not have previously recognized.

HEMANTH, Raksha<sup>1</sup>, Erica A. ERRIGO<sup>1</sup>, Annette PANTALL<sup>1</sup>, Rebecca L. PRATT<sup>1,2</sup>. <sup>1</sup>College of Osteopathic Medicine, <sup>2</sup>Department of Radiology Michigan State University, East Lansing, MI 48824, USA.

### Muscle fiber direction of the upper trapezius in relation to tender zones of patients with chronic neck pain.

INTRODUCTION. Neck pain is a common musculoskeletal complaint and the reason many patients consult osteopathic physicians. Tender zones (TZ) and tissue changes in neck and shoulder muscles, particularly the upper trapezius (UT), are frequently associated with idiopathic neck pain. Osteopathic manipulative medicine

*continued on next page*

## Abstracts - Poster Presentations Session 4 continued

(OMM) techniques, specifically myofascial release and strain-counter strain, are reported to reduce tenderness. We hypothesize that TZ locations of patients with chronic neck pain correspond to changes in muscle fascicle direction in the UT. **METHODS.** Five female patients with neck pain (age range 21-53) were recruited for this pilot study. Using OMM techniques, tissue texture abnormality was noted on a schematic of the posterior head and neck. These indications were then transferred onto skin overlying the UT of cadavers (n=5). Donors were subsequently dissected and UT fiber direction changes were measured using goniometers. Zero was set along the horizontal fibers of the UT attaching to the scapular spine. **SUMMARY.** Changes in muscle fiber direction were most notable at  $22.30 \pm 3.60$  and the other at  $13.50 \pm 2.60$ . The 5 patient schematics indicated TZs located at  $18.60 \pm 2.40$  (SD 2.60) and  $9.60 \pm 1.20$  (SD 2.70) from the recorded muscle fiber changes on the female donors. Clinical implications are that areas of muscle where there is a large transition in fascicle direction may result in tissue changes and tenderness possibly as a result of increased intra-muscular shear forces. **CONCLUSIONS.** The findings of this pilot study support our hypothesis that TZs of patients with neck pain are in close proximity to changes in muscle fascicle direction of the UT. Our ongoing studies involving electromyography nerve stimulation to analyze muscle activity during isokinetic and ramp contractions in patients with neck pain may further reveal associations between muscle fibers, fascia and the neurophysiological causes of neck pain. (Gratitude to the MSU Willard Body Program)

HEWETSON, Anthony, Vaughan LEE, Texas Tech University, Department of Medical Education, Lubbock, TX 79430, USA.

### Advanced dissections and education skills: Training teaching assistants.

**INTRODUCTION.** Due to increased class size and decreased faculty availability, clinical anatomy instruction at many schools is increasingly dependent on the efforts of graduate teaching assistants. Maintaining high quality instruction requires special training designed to increase teaching assistant proficiency in dissection and in conveying didactic information. **RESOURCES.** A course requiring equal amounts of didactic preparation and dissection was developed. The focus of dissection was creation of prosections, expertly prepared specimens for the demonstration of anatomical structures, which was conducted under the direct supervision of a skilled faculty member. As the prosection proceeded, the students were expected to demonstrate good dissection technique and to develop an understanding of the use of display in prosection. The prosections generated were those used in class and had to be of the highest quality. Didactic proficiency was evaluated by use of question and answer sessions during the prosection and perceived deficiencies in teaching technique were addressed. A formal process for evaluating both didactic knowledge and teaching skills is under development. **DESCRIPTION.** The goal was to design a course for teaching assistants to develop advanced dissection techniques and enhanced instruction skills to deliver didactic information to medical students. **SIGNIFICANCE.** The use of teaching assistants allows us to provide instruction to medical students with fewer faculty resources. The quality of instruction, however, must not be sacrificed. This course provided the additional instruction to prepare graduate teaching assistants to deliver quality instruction. This approach should be considered by any institution that is faced with a growing demand to shift laboratory instruction to teaching assistants.

HONG, Trudy M.<sup>1</sup>, Kaori TAMURA<sup>2</sup>, Georg C. BEZARD<sup>1</sup>, Ali Cem KUCUKDAGLI<sup>1</sup>, Beth K. LOZANOFF<sup>1</sup>, Steven LaBRASH<sup>1</sup>, Selcuk TUNALI<sup>1,3</sup>, Scott LOZANOFF<sup>1</sup>. <sup>1</sup>Department of Anatomy, Biochemistry & Physiology, University of Hawaii School of Medicine, USA; <sup>2</sup>Department of Kinesiology and Rehabilitation Science, University of Hawaii at Manoa, USA; <sup>3</sup>Department of Anatomy, TOBB University of Economics and Technology, Ankara, Turkey.

### Presenting mechanisms of anatomical variations utilizing 3D animations and the Aurasma mobile app.

**INTRODUCTION.** Knowledge of anatomical variations is critical to avoid clinical complications and it enables an understanding of morphogenetic mechanisms. Depictions are comprised of photographs or illustrations limiting appreciation of three-dimensional (3D) spatial relationships. The purpose of this study is to describe an approach for presenting complex morphogenetic mechanisms based on examples of two anatomical variations: an aberrant right subclavian artery (ARSA) and a third head (caput tertium) of a biceps brachii

*continued on next page*



## Abstracts - Poster Presentations Session 4 continued

muscle. **RESOURCES.** ARSA and caput tertium were identified in separate cadavers during routine medical student dissections. Specimens were photographed and physical measurements were recorded. Three-dimensional models were lofted and rendered with Maya software and converted as Quicktime animations. Regarding morphogenetic mechanisms, ARSA was represented by the incorrect regression of a portion of the embryonic aortic arch proximal to the right 7th intersegmental artery. Caput tertium formation was demonstrated as a disruption of the presumptive investing fascia leading to ectopic splitting of the ventral premuscular mass. Photographs of the first frame of each animation were recorded and registered with Aurasma Mobile App software. **DESCRIPTION.** To create animations of anatomical variations and associated morphogenetic mechanisms that can be manipulated on the mobile device enabling the student to easily visualize and appreciate the 3D spatial relationships. **SIGNIFICANCE.** Animations provide a useful approach for visualizing anatomical variations. The specific colors help students visualize connections and understand complex embryological mechanisms that are often difficult to demonstrate in an anatomy lab or clinical setting. Future work will be directed at creating a library of variants and underlying mechanism of formation for presentation through the International Journal of Anatomical Variation website ([www.ijav.org](http://www.ijav.org)).

KIMBAL, Adam<sup>1</sup>, Bonnie KENYAN<sup>1</sup>, David HORN<sup>1</sup> and Brion BENNINGER<sup>1,2</sup>. <sup>1</sup>Medical Anatomy Center, Departments of Medical Anatomical Sciences, Neuromuscular Medicine, Family Practice, Western University of Health Sciences, COMP-Northwest, Lebanon, OR. USA; <sup>2</sup>Orthopaedic and General Surgery residency faculty, Samaritan Health Services, Corvallis, OR. USA.

Comparing ultrasound images and probes between variable cadaver preparations for health care training.

**INTRODUCTION.** Ultrasound (US) is the visual stethoscope for today's student health care professional (SHCP). US displays the body's architecture in monochromatic scaling (MS). Integrating US during anatomy dissection would enable the learner to better understand imaging associated with US. Traditional embalmed tissue has the least amount of muscle tissue compliance when compared to lightly embalmed, unembalmed and live tissue. The objective of this study was to investigate various US probes that successfully reveal anatomy from donor cadaver patients (DCP's) of variable embalming solutions. **METHODS.** Literature search was conducted regarding the use of US with DCP during anatomy lab. Healthy volunteers (n=20), had their supraspinatus(S), flexor pollicis brevis (FPB), and vastus medialis(VM) muscle tendon complexes imaged with Fukuda-Denshi UF-760AG US system using linear (LA38 & SonicEye finger) probes and SonoSite M-Turbo with HFL 50 probe as controls. Recently deceased unembalmed (n=2), traditionally embalmed (n=20), and live healthy subjects (n=20) had US performed. Each muscle had probes placed parallel and perpendicular to muscle fibers. **SUMMARY.** Literature search revealed no known US studies comparing probes with different cadaveric tissues to develop US skills. S, FPB, and VM of 20 embalmed cadavers (n=40 sides) were all identified in all 3 mediums with all 3 separate probes. Images were equivocal to US textbooks. No clinically significant differences between live and cadaveric tissue was noted, however there was minor variability between the two cohorts. For SHCP to acquire US skills it is useful to correlate MS with structures. SHCP could begin this exercise with DCP's during an anatomy course. **CONCLUSION.** This study revealed US can be successfully conducted on recently deceased unembalmed and traditionally embalmed DCP's integrating US with anatomy courses.

LONGO, Alison M., Hugo BERGEN and Jason PEELER. University of Manitoba, Department of Human Anatomy & Cell Science, College of Medicine, Faculty of Health Sciences, Winnipeg, MB, Canada.

Musculoskeletal anatomy education: evaluating the influence of different methods of delivery on medical students perception and academic performance.

**INTRODUCTION.** Medical schools have traditionally used a dissection-based approach for educating students about musculoskeletal (MSK) anatomy. There is a growing trend towards the use of prosected, and 2D or 3-D imaging materials as learning resources. While data may suggest that these methods of delivery enhance the learning environment, controversy still exists among medical educators about the most efficient or effective way to educate students. The purpose of this investigation was to examine whether the method of educational delivery would influence student perceptions about learning, and academic performance on MSK anatomy exams. **METHODS.** Undergraduate students from the same medical school were compared. One

*continued on next page*

## Abstracts - Poster Presentations Session 4 continued

cohort was educated using a dissection based teaching model; the second cohort was taught using a prosection based method of delivery. All other aspects of the MSK curriculum were the same, including contact hours. Information was gathered about student perceptions using a standardized survey that compared 6 different methods of delivery (dissection/prosection/lecture /case-based/on-line/medical imaging) on 8 specific learning objectives. Survey results were compared against student performance on MSK practical exams. SUMMARY. Ninety-three students (dissection=39, prosection=54) participated. Only 27 students had previously taken an anatomy course. Both groups rated learning via medical imaging and case based scenarios highly. Each cohort ranked their specific method of delivery (dissect vs prosect) in the top 3. There was no significant difference in the academic performance between the groups. CONCLUSIONS. Data support the inclusion of medical imaging and case-based scenarios as a key component of MSK anatomy curriculum, but suggest that little difference exists in student performance when comparing dissection and prosection based curriculums. These results should help guide the selection of effective MSK anatomy delivery methods within medical programs.

McANDREW, Darryl J. Graduate School of Medicine, University of Wollongong, Wollongong NSW 2522 Australia.

### A look back over the first 9 years of our body donation program: What we wish we'd known!

INTRODUCTION. Body donation programs are designed and managed to support the educational requirements of students and the research needs of academic staff within medicine and allied health. However, there are many additional considerations when developing a program. Professional and administrative personnel need to address staffing and budgeting issues of the program that are currently difficult to estimate. Literature relating to the growth and costs of the early developmental years of programs is limited to donor characteristics and cadaver numbers specific to that institute, which may not be relevant to others. This project reflects on the first 9 years of the University of Wollongong's Body Donation Program and associates donor and cadaver details to local socioeconomic and demographic data, thus producing information that can be applied in any geographical location. RESOURCES. Nine years of donor characteristics data was collated through a retrospective cohort study design, examining the UOW Anatomy Database. This was related to demographic and socioeconomic data for the region supplied by the Australian Bureau of Statistics. DESCRIPTIONS. To produce data that can be used in the planning and budgeting of new body donation programs and the identification of potential body donors. SIGNIFICANCE. This review provides data that would allow educational institutes contemplating the development of a body donation program to apply the socioeconomic and population derived donor characteristics to their specific region, allowing for more accurate infrastructure, staff and budget planning. For example, donor numbers in any particular year could be estimated based on the number of local residents within a particular age bracket and associated costs predicted based on average deceased donor distance from the institute.

MUELLER, Dean A., and Jeannette R. HINKLE. University of Michigan Anatomical Donations Program, Ann Arbor, MI 48109, USA.

### Instrument organization.

INTRODUCTION. Since the 1950's the Anatomical Donations Program has accumulated over 3,000 surgical instruments for the purpose of anatomical dissection without any formal organizational system. This vast inventory, which is used by students, professors and physicians, deteriorated over time into a series of disorganized containers of substandard instruments that were difficult and unsafe to use. As in most institutions, the storage and maintenance of instruments are downgraded in priority amidst the department's myriad of responsibilities. Without an organizational structure, the frequent event of locating instruments to perform a quality dissection becomes chaotic, dangerous and time-consuming. RESOURCES. Standard commercial temporary cremation urns with lids removed served as containers to house the instruments. Labels stating the instruments' names (i.e. Small-Toothed Forceps) were printed, laminated and affixed to the containers vertically by drilling one self-threading screw into each end of the labels. On each container, beside the label, an actual, physical instrument corresponding to the label (i.e. a pair of Small-Toothed Forceps) was

*continued on next page*

## Abstracts - Poster Presentations Session 4 continued

fastened to the container by drilling small holes in the wall of the container and then pulling zip-ties through the holes and around the instrument, with the excess length of the zip-tie inside the container. Once tightened around the instrument, the excess lengths of the zip-ties were removed. After the containers were labeled and affixed with corresponding instruments, the containers were stocked and stored in an accessible cabinet. DESCRIPTION. To design a comprehensive organizational infrastructure to house dissection instruments with basically no budget, using only supplies already available in the department. SIGNIFICANCE. A clear and effective system for organizing and storing communal dissection instruments in the academic setting of gross anatomy laboratories results in higher quality instruments and a cleaner and safer environment. For the students' edification, the storage and maintenance of instruments should reflect the high standard of respect, dignity, hygiene and organization required of all health care professionals.

NOEL Geoffroy PJC<sup>1</sup>, Jonathan HUDON<sup>1</sup> and Sandie LAROUCHE<sup>2</sup>. <sup>1</sup>Division of Anatomical Sciences, Department of Anatomy and Cell Biology, Faculty of Medicine; <sup>2</sup>Ingram School of Nursing, McGill University, Montreal, QC, H3A 0C7, Canada.

### Dissecting out the variables of an interprofessional near peer anatomy teaching experience.

INTRODUCTION. Healthcare professionals have traditionally been educated separately with limited common training opportunities that could help them understand how each other applies their knowledge of anatomy. The emphasis on specific anatomical structures and the clinical scope of each profession is often different. By identifying commons ground and complementarities in their knowledge of anatomy, students from different professional programs could ultimately be able to work more collaboratively with each other. METHODS. In this study, we assessed multiple variables of a near peer teaching experience that crossed professional boundaries. Forty first or second year medical students, distributed into 10 to 15 groups of 1 to 2 medical students facilitated at least two 2hr anatomy laboratory sessions for 190 first year registered or non-registered nursing students, or a combination of both, distributed into groups of 12 to 15 nursing students. All participants completed surveys before and after the sessions to test the impact of variables, such as Readiness for Interprofessional Learning, Professional Identity Scale, Clinical Teaching Preference and Near Peer Teaching Experience, on the success of the experience. SUMMARY. Scores from both Teaching Questionnaires showed that both professional groups benefited from the experience. However, the analysis of the Professional Identity scores revealed that grouping students with similar scores or clinical exposure determined the effectiveness of the exercise. CONCLUSIONS. The interprofessional near peer teaching approach was beneficial to both tutors and tutees as they both appreciated the commonalities and complementarities between each profession. However, in designing similar interprofessional near peer teaching initiatives, it is important to carefully consider the level of clinical exposure of the different groups, their professional identity formation and their curricular milestones.

OWENS, Juston, Donna HERMEY, and Stan ILIFF. Lincoln Memorial University – DeBusk College of Osteopathic Medicine, Cumberland Gap, TN 37752, USA.

### Methods of using plastinated specimens to enhance learning and retention of anatomical structures.

INTRODUCTION. Plastinated specimens have revolutionized the ways in which human anatomy can be presented to students. The current study's aim was to determine how to best use plastinated specimens in the classroom to help students experience the most learning and retention. RESOURCES. Two plastinated specimens were used to teach a high school Anatomy and Physiology class previously unknown anatomical structures. An upper limb specimen and a neck specimen were both used during the presentation. DESCRIPTION. The Anatomy and Physiology class met for 50 minutes. The class time was divided into three sections, each section consisting of a short presentation. The first presentation exclusively taught the students using only the upper limb specimen. The second presentation exclusively taught the students using a PowerPoint presentation which featured illustrations of the neck. The third presentation used the neck specimen to reiterate the same concepts from the PowerPoint presentation. Before the presentations, students were given a pre-test to determine their previous exposure to the anatomical structures, and following each presentation, the students were given a 5-question quiz to determine their level of learning. SIGNIFICANCE.

*continued on next page*

## Abstracts - Poster Presentations Session 4 continued

The students' test scores suggested that the most learning occurred during the neck presentations. The most improved scores occurred when students were shown structures using illustrations and then shown those structures again using the plastinated specimen. The data obtained from this research suggests that in an effort to help students learn and retain more information it is prudent to include plastinated specimens as teaching tools alongside lectures that use illustrations of anatomical structures.

PIPE, Kimberly H., Aron R. DAVIS. University of California Davis Body Donation Program, Sacramento, CA 95820, USA

### Veterans memorial services for donors.

INTRODUCTION. The UC Davis Body Donation Program (UCD BDP) holds a veterans memorial service in addition to its general memorial service each year. The service is designed to honor anatomical donors who are veterans of all branches of the United States military. RESOURCES. The UCD BDP staff follows the process outlined by the US Department of Veterans Affairs to determine eligibility for receiving military honors. The UCD BDP provides families with the required forms and will liaise with the Honor Guard to determine volume and scheduling. Families are invited to contribute to the memorial by bringing photos and mementos of their loved one. DESCRIPTION. This is a separate service to give gratitude to both individuals and families of those who donated their bodies for the advancement of education and research and who also served in the US Armed Forces. The service is comprised of four parts which include a welcoming address, expressions of gratitude by faculty and students, the presentation of the U.S. flag and closing remarks. Before the flag presentation, the Honor Guard is introduced and they will describe the process for presenting military honors and when attendees should stand or sit. The Honor Guard will unfold, present and refold the flag prior to placing it on a pedestal. With the flag on the pedestal, Taps is played. This first flag presentation is given to one of the UCD School of Medicine Deans and is symbolic of the family presentations that follow. During closing remarks, families are instructed to have their representative ready in the lobby for individual presentations. SIGNIFICANCE. The service gives families of entitled veterans the opportunity to experience full military honors and a sense of closure that they would have received had they chosen traditional funeral rites.

PUGH, Kristy R., Evan M. GAROFALO, Brandon W. BONDS, and Colin F. MACKENZIE. Shock Trauma & Anesthesiology Research Center & Department of Anatomy and Neurobiology. University of Maryland School of Medicine, Baltimore, MD 21201, USA.

### Anatomic knowledge increases after participation in ASSET training.

INTRODUCTION. Rapid open vascular exposure and repair can be life-saving in both civilian and combat casualty situations and requires mastery of anatomic knowledge, which is generally built by repetition in training. With limitations in training hours, the opportunities for surgeons to gain proficiency in performing open vascular exposures have been reduced. The Advanced Surgical Skills for Exposure in Trauma (ASSET) course is a training program that teaches surgeons over forty key vascular exposures using cadaveric models. We hypothesized that ASSET training improves anatomic knowledge. METHODS. Surgical residents were evaluated by two co-located evaluators on four selected ASSET procedures (axillary, brachial and femoral artery exposure, and lower extremity fasciotomy) using previously validated metrics including anatomic knowledge, landmarks, and skin incision location before and after ASSET training. Pre and post-ASSET scores were compared using paired t-test,  $p < 0.05$  was significant. SUMMARY. Forty surgical residents with an average of 3.6 clinical years of experience were evaluated. Mean scores for anatomic knowledge were significantly improved after training (Pre =  $40.5 \pm 13.2$  vs. Post =  $69.8 \pm 10.8$ ;  $p < 0.00001$ .) CONCLUSION. Anatomic knowledge for the exposure of traumatic vascular injuries, where mistakes and delays can have dire consequences, benefits significantly from ASSET training. Supplemental courses, such as ASSET, provide alternative surgical training to allow infrequently performed procedures to be practiced. (Sponsored by Grant No. W81XWH-13-2-0028 from USAMRMC JCP-1 and CDMRP).



## Abstracts - Poster Presentations Session 4 continued

QUINN, Melissa, M., and Jennifer M. BURGOON. Division of Anatomy, College of Medicine, The Ohio State University, Columbus, Ohio, 43210, USA.

Understanding our students and how they learn: preferred learning styles of undergraduate gross anatomy students.

INTRODUCTION. Students learn and process information in many different ways. Learning style instruments are useful as they allow instructors to learn more about students, as well as aid in the development and application of useful teaching approaches and techniques. At the undergraduate level (i.e., primarily students working on their first bachelor's degree), there is a noticeable lack of research on learning style preferences of students enrolled in gross anatomy. METHODS. The Index of Learning Styles (ILS) questionnaire, developed by Drs. Richard Felder and Linda Silverman, which indicates students' preferred learning styles in four dimensions, was administered to students enrolled in a large enrollment undergraduate gross anatomy course with laboratory to determine their preferred learning styles. SUMMARY. The preferred learning styles of students (n = 506) enrolled in an undergraduate gross anatomy course were active (54.7%), sensing (84.8%), visual (80.9%), and sequential (74.4%). CONCLUSIONS. An understanding of students' preferred learning styles should guide course design. Based on the preferred learning styles of the undergraduate students in this particular gross anatomy course, course activities should be hands on (i.e., active), the course should be grounded in concrete information (i.e., sensing), the course should utilize visual representation such as images, figures, models, etc. (i.e., visual), and the course curriculum should move in small incremental steps that build on each topic (i.e., sequential).

RICHARDSON, Matt, Adam BURCH<sup>1</sup> and Brion BENNINGER<sup>1,2</sup>. <sup>1</sup>Medical Anatomy Center, Departments of Medical Anatomical Sciences, Neuromuscular Medicine, Family Practice, Western University of Health Sciences, COMP-Northwest, Lebanon, OR. USA; <sup>2</sup>Orthopaedic and General Surgery residency faculty, Samaritan Health Services, Corvallis, OR. USA.

Using augmented reality in the form of Google Glass to examine students in the medical anatomy lab.

INTRODUCTION. As medical education progresses, anatomy courses are compressed into 6-12 weeks with extra sessions during the first two years. Its unclear when the first "tagged" exams were conducted where structures are marked with pins or string. Such exams are the accepted method of anatomical examination in North America and Great Britain. This does not accurately reflect in vivo invasive procedures where no structures are pre-marked for the surgeon. The objective of this study was to investigate Google Glass (GG) as a novel lab testing method, approaching anatomy of invasive procedures. METHODS. Literature search was conducted regarding the use of GG as an examination tool in the anatomy lab. Medical Students (MS) were taught how to use GG and asked to practice. At exam stations MS read a clinical vignette and asked to identify an unmarked structure by using soft tipped/non-marking forceps, then take a picture with GG. SUMMARY. No previous studies were identified using Google Glass as an examination method for MS. MS averaged 72.5% in identifying correct structures. This average is lower than expected, we believe due to unfamiliarity with testing strategy, not to any inherent difficulty in using the technology. We propose a new method of anatomical lab examination through the use of augmented reality in the form of GG. The purpose of using GG would be to remove all pins, markers, tags or strings from anatomy lab examinations to more accurately emulate/depict anatomy in its true clinical form. Each new technology provides unique opportunities to change and improve medical education. GG allows dissection examinations to be done that require MS to break free from the cycle of memorization and regurgitation requiring them to better understand clinical anatomy. This method requires another level of complexity and critical thinking from the examinee. CONCLUSION. GG can be used during anatomy lab exams for more life-like and directly applicable clinical anatomy.



## Abstracts - Poster Presentations Session 4 continued

RICHTER, Saskia D, Laura C. BOUCHER, Eileen L. KALMAR. Division of Anatomy, The Ohio State University, Columbus, OH, 43210 USA.

Multimodal learning resource: cross-sectional anatomy.

INTRODUCTION. Learning through cross-sectional anatomy is not a new concept; however, very few programs utilize this type of learning resource at all educational levels. Through physical cross-sections, unlabeled digital images, fully labeled digital images, and correlated computed tomography (CT) images, students develop a three-dimensional understanding that will be fundamental to various careers. The aim of this project is to create a complete gross anatomy multimodal cross-sectional collection for use at all educational levels.

RESOURCES. Our resources included one adult male cadaver (age 82), CT scanner, Nikon digital camera, and Adobe Photoshop. DESCRIPTION. Prior to sectioning, a full-body CT image series was performed, creating 4,797 images at 0.6mm. A total of 151 (1 to 1.5 inch thick) sections were created utilizing the same cadaver. All sections were transverse, except through the right knee, where sagittal sections were taken. Both surfaces of each section were digitally imaged, labeled for key anatomical structures, and organized by region. All inferior and medial view images were then correlated to the corresponding CT image. Finally, a comprehensive library of all images (labeled and unlabeled) and CTs was created for use in lecture and laboratory settings, as well as for independent student study. SIGNIFICANCE. Cross-sections are a unique tool that can be utilized to help students understand anatomical relationships and various clinical images. All physical cross-sections are utilized as a hands-on lab resource together with images, and CTs to create a multi-media, multimodal teaching resource set. By challenging students to identify and understand anatomy through transverse and sagittal sections, they are able to better interpret multiple functional aspects and anatomical relationships.

RUTLAND, Marsha D; Janelle K. O'CONNELL. Hardin-Simmons University, Department of Physical Therapy, Abilene, TX. 79698, USA.

Benefits of offering a clinical anatomy review course to health care professionals.

INTRODUCTION. To evaluate the benefits of a clinical anatomy review course to healthcare professionals.

METHODS. Thirty-nine healthcare providers participated in a 5-hour anatomy review course (4 hours: lecture with clinical scenarios & human cadaver lab + 1 hour reading from 3 assigned articles prior to course attendance). A pre-test consisting of 10 questions (100 possible points) was issued initially followed by a post-test at course completion. A follow-up test was sent via Survey Monkey 4 months after course completion. The pre- and post-test contained the same questions but were ordered differently. The follow-up test consisted of 7 questions from the original bank of 10. SUMMARY. The composition of the healthcare providers who attended the course consisted of 31 Physical Therapists (PTs), 3 Physical Therapist Assistants, 3 Occupational Therapists, 1 Occupational Therapist Assistant, and 1 Certified and Licensed Athletic Trainer. Average years of practice for all attendees was 14.4 years, while average years of practice of PT's was 13.7 years. A paired t-test revealed significant improvement ( $p=0.00$ ) in knowledge gained from pre-test (39.7% + 16.7) to post-test (69.7% + 17.2). Average test score improvement on the pre- to post-test scores was 30%. All (100%) of participants rated the course 80% or higher. Seven subjects (22.5% of attendees) responded to the 4-month follow-up test. The 4-month post-test scores had a mean of 58.5% demonstrating an improvement and retention of knowledge, although not significantly different from initial pre-test scores. However, all respondents (7 of 7) reported improvement in clinical practice techniques. CONCLUSIONS. An educational course with readings, tests, lecture, cadaver lab, and functional lab application increased knowledge and improved treatment techniques among healthcare clinicians. More review courses with practical application to the healthcare clinician should be offered to help improve clinical practice.

## Abstracts - Poster Presentations Session 4 continued

SEVERNS, Danielle M., and Alla G. PETERS. Department of Biology, Missouri Southern State University, Joplin, MO 64801, USA.

### Whole-body donation willingness: associations with cadaver-based anatomy and blood/plasma donations.

**INTRODUCTION.** Whole-body donation is a practice of critical importance in improving medical care. However, the shortage of cadavers remains a problem. Multiple studies worldwide have assessed individual willingness and identified demographic correlations associated with whole-body donation. Research has indicated significant associations between being an organ donor and a willingness to consider the donation. Reported data also suggest a negative relationship between participation in cadaveric dissection and willingness to consider the donation. This study surveyed three factors: individual participation in blood donation, plasma donation, and cadaver-based anatomy to determine how they correlated with willingness to consider whole-body donation. **METHODS.** Current and previous students ( $n=261$ ) at Missouri Southern State University whom have taken ( $n=120$ , 46%) and have not taken ( $n=141$ , 54%) cadaver-based anatomy were surveyed. Willingness for the donation was asked in yes/no format and using a Likert scale, 1 as strongly unwilling and 5 as strongly willing. The survey included demographic factors such as gender, age, college major and year. Data were analyzed using Statistical Package for the Social Sciences software. **SUMMARY.** Participation in cadaver-based anatomy with prosected cadavers was not found to be significant with increased willingness for the donation. Enrollment in cadaver-based anatomy and increase in age were collectively significant with increased ranking of willingness ( $p=0.026$ ). Being current blood and plasma donors as well as having a history of blood donation were all found to be significant with willingness to become a whole-body donor ( $p=0.045$ ,  $0.015$ , and  $0.002$ , respectively). **CONCLUSIONS.** Study results reveal that students who participated in both blood and plasma donation are more willing to consider whole-body donation. All findings further contribute to current knowledge regarding factors associated with willingness for this essential donation.

SEVERSON, Arlen R. Department of Biomedical Sciences, University of Minnesota Medical School, Duluth Campus, Duluth, MN 55812, USA.

### Converting a computerized neuroanatomical tool to a HTML5 format.

**INTRODUCTION.** In order to meet the medical neuroscience laboratory educational needs in a revised and condensed curriculum, an HTML5 interactive neuroanatomical learning tool is being developed and tested. The learning tool is currently available online for student use. The program is designed to facilitate student learning of neuroanatomical structures, structural relationships, significant morphological and functional features of the human central nervous system, and the clinical relevance of the neuroanatomical structures. **RESOURCES.** Gross images of intact and dissected brains, thick and stained thin brain sections, thin stained brainstem and spinal cord sections, and MR images are currently available for being included in the program. **DESCRIPTION.** Neural structures to be identified are listed on the right-hand side of the screen and clicking on the name of a specific structure produces a transparent overlay of that structure. Structures can be identified also by moving the pointer over the image and clicking on a specific structure. With either approach, the structure is identified by a colored overlay and a collapsible dialog box at the bottom of the screen that provides a brief description of the structure and its functional role in the nervous system. A student can scroll from one image to another. A glossary of neuroanatomical terms used in the program allows a student to select and view the neuroanatomical structures in the gross and sectioned specimens, and the MR images. **SIGNIFICANCE.** The move to the new format appears to be an efficient way to learn the neuroanatomical and functional aspects of the nervous system in a shortened and clinically oriented neuroscience course.



## **Preclinical Science Assistant/Associate/Full Professor Position**

**William Carey University College of Osteopathic Medicine** is seeking applications for a full-time assistant/associate/full faculty position in cadaver-based human gross anatomy. Some experience in neuroanatomy, histology, and embryology would be beneficial. This faculty position is open for hire as soon as July 1, 2014, and will remain open until filled.

All applications must be submitted online at:  
<https://wmcarey.peopleadmin.com/postings/884>.

*The University does not sponsor H1B visas.*

For additional information, please contact  
Italo Subbarao at [isubbarao@wmcarey.edu](mailto:isubbarao@wmcarey.edu), or 601.318.6046.



*We've created a tool*

**to help you describe our organization  
to potential new members.**

**To obtain a brochure, please visit the AACA registration desk.**

